

# Mature Jejunal Teratoma in adolescents: A case report

N Wisnu Sutarja, MD, Ariandi Setiawan, MD, Fendy Matulatan, MD

Pediatric Surgery Division, Department of General Surgery, Medical Faculty of Airlangga University, Dr. Soetomo Hospital, Surabaya, Indonesia

## SUMMARY

Jejunal teratoma (JT) is a rare type of extragonadal teratoma. To date, the subject of mature jejunal teratomas has not yet been discussed in the literature. This type of teratoma contains cystic, solid, and calcified components. JT may be suspected on a computed tomography (CT) scan, which can describe the various features of the germinal layer components, followed by normal laboratory results of alpha fetoprotein (AFP) and  $\beta$ -human chorionic gonadotropin ( $\beta$ -hCG). This case report describes that of a teenager with a mature JT whose chief complaints were recurrent general weakness due to anemia and an abdominal mass. The patient was initially treated with non-operative management; however, his symptoms remained unresolved, and he accepted surgical intervention. No additional chemotherapy or radiotherapy was required after complete tumor excision. The patient no longer complained of general weakness following surgery.

## INTRODUCTION

Jejunal teratomas (JT) are very rare neoplasms, and no publication discussing this type of tumor is yet available. JT contain cystic, solid, and calcified components. This type of tumor may be suspected on a computed tomography (CT) scan, which can describe the various features of the germinal layer components, followed by normal laboratory results of alpha fetoprotein (AFP) and  $\beta$ -human chorionic gonadotropin ( $\beta$ -hCG). In this report, we discuss the case of a teenager with a mature jejunal teratoma.

## CASE REPORT

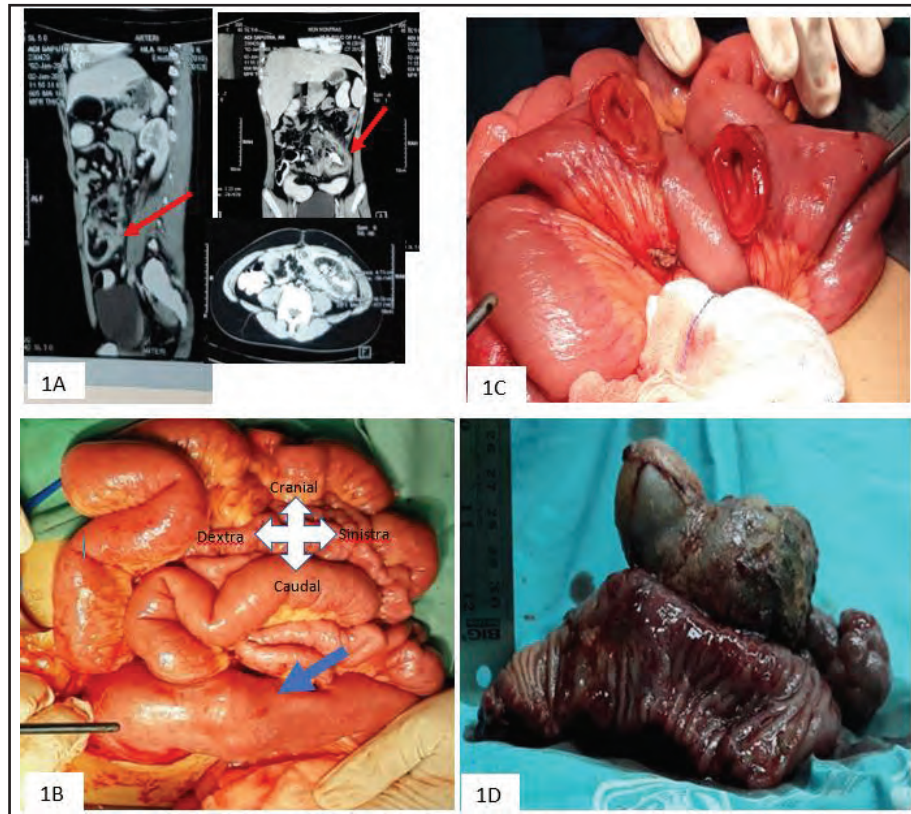
A 15-year-old male arrived at Dr. Soetomo Hospital (SH), Surabaya, Indonesia with a chief complaint recurrent general weakness due to anemia. This problem was solved temporarily by repeated hospitalization within the last 1 year for recurrent transfusion. The patient's appetite and sleeping quality was good, his daily activities were within normal limits. Our patient had no motor or sensory complaints. Every time he felt weak, his hands and face turned pale and then he was admitted to the peripheral hospital. The patient denied other complaints such as headache, fever, bloody stool, blood in urine, history of trauma, or spontaneous bleeding from other places whenever he felt weak. The patient didn't have medical record about the laboratory value from peripheral hospital. When his anemia had been resolved, he felt fit and was discharged from the hospital. His last transfusion was 2 months before this admission. When arrive in SH, the patient was found to be anemic, which required transfusion until his condition improved and

acceptable for operation of his lump. He had a painless lump in his lower left abdomen which was recognized by his mother since he was a 3-days-old neonate and increased in size as the patient grew older. The patient reported no other lumps grew elsewhere on his body. The patient had a good appetite, never complained of abdominal distension, no blood in his feces, had normal bowel habits, and never had other digestive problems. His urine was clear and yellow, and no complaints regarding his urination were made. The patient's weight was stable in the last 1 year, and he had no history of other diseases or high blood pressure. No peripheral blood smear examination nor fecal occult blood test (FOBT) was previously performed.

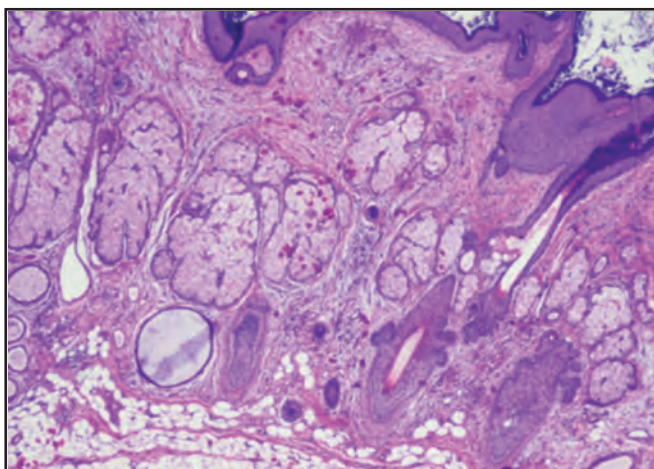
The patient had no family history of recurrent anemia, tumor, cancer, or similar complaints. The patient's mother was 24 years old when the patient was conceived. Routine checks by the midwife and an ultrasound examination of the womb by an obstetrician revealed that the fetus was normal. On physical examination, the patient's weight was 54 kg, and his vital signs, heart, and lungs were normal. His conjunctiva was anemic. In abdominal examination, we obtained the impression of a mass lump in the left lower quadrant with the skin surface was normal as the surrounding mass, normal bowel sounds, tympanic percussion, palpation of a single solid mass, flat surface, with firm impression boundaries, fixed at the base, painless, mass size 11 × 8 × 6 cm, does not cross the midline. No palpable enlarged lymph nodes were found in the head, neck, axilla, or inguinal regions. Liver and spleen impressions were within normal limits. Both testes were palpable within normal limits. The rectal digital examination, we found that the ampulla recti did not collapse, and no palpable impression of an intraluminal or extraluminal mass was noted, hand gloves was visible feces without blood. Motor and sensory functions were within normal limits. Laboratory testing showed normal tumor markers of  $\alpha$ FP < 1.3 and  $\beta$ hCG < 2.0, blood count show Hb = 8.0 g/dL. Other laboratory values were within the normal range.

The results of physical examination revealed an intra-abdominal mass with anemia; thus, further radiological examination was recommended. Abdominal ultrasound on 1 month before operation revealed a donut-shaped intraluminal mass in the left lower quadrant of the abdomen; this mass appeared to lead to intussusception, but no symptoms of intussusception that matched the patient's clinical condition. A Computed Tomography (CT) Scan with contrast of the abdomen was then performed for further investigation.

Corresponding Author: N Wisnu Sutarja  
Email: wisnuflycrick@gmail.com



**Fig. 1:** (A) Abdominal CT scan with contrast showing a mass (red arrow). (B) Intraoperative mass attached to interintestine (blue arrow). (C) Intraoperative jejunum after tumor resection. (D) Cut section of tumor specimen.



**Fig. 2:** Histopathology of the teratoma (magnification, 10x).

CT scan with contrast of the abdomen on 1 week after ultrasonography showed a lesion with solid components, fat, and calcification. The lesion measured  $10.7 \times 7.72 \times 4.71$  cm and was located in the left parailiac region. Contrast administration showed enhancement of the edges, septa, and solid parts of the lesion. Figure (1A) shows the lesion in the lower left quadrant of the patient's abdomen.

From the laparotomy, we found clear peritoneal fluid. The tumor was located in the intraluminal jejunum and the jejunum attached to the left white line, sigmoid, and

terminal ileum, which was pulled to the left. Release of intestinal adhesion followed by tumor evaluation was then performed (Fig 1B). The intraluminal tumor in the jejunum was observed approximately 40 – 52 cm (about 12 cm long) distal to the ligament of Treitz. The tumor was freed from the surrounding tissue and then total tumor was resected along with the surrounding jejunum for about 20 cm (Fig 1C, 1D). After opening the resected jejunum, there was single heterogenous (solid and cystic) oval mass tightly attached with mesenteries side of jejunum, with size  $11\text{cm} \times 10\text{cm} \times 5\text{cm}$ , no ulceration, no hemorrhage as shown in Figure (1D). On further exploration, we obtained liver had sharp edges, a flat surface, and a normal red color. No mesenteric lymph node enlargement was noted. After the intact resection of the jejunum with tumor, end-to-end jejunum anastomosis were performed.

Macroscopic examination of the anatomical pathology of the tumor revealed that the preparation contained portions of jejunum tissue weighing 275 g, 3.5 cm in proximal jejunum diameter, and 3 cm in distal jejunum diameter. The outer surface was partly smooth and partly covered with fat. On the slices, the mass was observed as sebaceous tissue, bone, teeth, and hair, measuring  $10\text{cm} \times 9.5\text{cm} \times 4.5\text{cm}$ . Some cysts measuring 1.2 cm in diameter with a yellowish-gray color and dense, chewy consistency were noted.

Microscopic findings showed sections of intestinal tissue with tumor growth consisting of skin epidermis, sebaceous glands, hair follicles, skin adnexa, glandular epithelium, hard bone tissue, fatty tissue, squamae, and calcifications, as shown in

Figure 2. The tumor had grown to the serous layer. No glial tissue and neuroepithelial components were seen. The ends of the resection were tumor free. No tumor was seen in the surrounding seven lymph nodes.

## DISCUSSION

The most common prevalence for gastrointestinal teratoma is gastric teratoma, but gastric teratoma alone accounts for less than 1% from total of teratomas.<sup>1,2</sup> The most frequent teratoma is sacrococcygeal teratoma (45% of all teratoma or 1 out of every 40,000 humans). To the best of our knowledge, there is no publication describing mature JT has yet been published. Small intestinal teratomas are believed to occur as a result of incomplete totipotential cell division in the subserosa of the jejunum in early life. However, the exact mechanism of this type of tumor remains unknown because of its rarity.<sup>3</sup>

This disease is usually diagnosed based on the patient's history, physical examination of the intra-abdominal mass, laboratory results revealed normal AFP and  $\beta$ -hCG values, and abdominal contrast CT scan. In our study, the results of the CT scan showed a lesion with solid components, fat, and calcifications. The lesion was a little bit bigger in width by operation 1 month after the CT scan was taken.

Teratoma is a common form of germ cell tumor (GCT). This tumor can develop congenitally or during childhood.<sup>4,5,6</sup> Because the tumor in our case was observed as early as when the patient was 3 days old, it may have developed congenitally. Mature teratomas show insignificant tumor growth. Our patient showed no clinical complaints or signs of distant spread, which often appears in immature or malignant tumors. Surgical removal of the tumor was performed only after the patient's repeated complaints of anemia as a teenager. His family was also afraid of operating option explained why he had just operated the lump when he was 15 years old. The patient's repeated anemia may be due to microscopic bloody stool, unfortunately we didn't perform FOBT to confirm this supposition. The type of anemia could not be identified because peripheral blood smear test was not conducted. While this type of tumor is not likely to metastasize to the bone marrow, this belief could not be confirmed because no peripheral blood smear test was performed. Surgery revealed a tumor located approximately 40 cm distal to the ligament of Treitz, which is still part of the jejunum. The jejunal with intraluminal tumor attach to the surrounding tissue confirmed that the tumor had been growing over a long period, but no signs of mesenteric or locoregional spread were noted, as supported by the patient's good liver and good mesenteric conditions. Thus, the tumor could be removed completely.

Macroscopic and microscopic pathological examination of the tumor showed sebaceous tissue, bone, teeth, hair, fatty tissue, squamous, and skin. These findings explained that tumor contains parts of endoderm, ectoderm, and mesoderm where each part can differentiate into many different tissues.<sup>5,6</sup> Different types of tissue from these three germ

layers lead to a teratoma. From the end of the tumor resection, histopathologic examination revealed no glial cells or neuroepithelial components. This finding indicates the absence of malignancy (i.e., a mature teratoma).

Chemotherapy is recommended for patients with grades 2 and 3 congenital immature teratomas after surgical resection.<sup>3,7</sup> Our type of JT was mature, no additional chemotherapy or radiotherapy was required after complete tumor excision. The variation of serum AFP level could be an indicator of tumor recurrence and of the need of further chemotherapy for patient with teratoma, especially in immature teratoma.<sup>3</sup> In our case, three months follow up after operation of this patients show normal AFP and  $\beta$ -hCG values, and 1.5 years after operation also no sign recurrent general weakness, no sign of recurrent abdominal mass.

## CONCLUSION

Teratomas are a type of GCT that can occur in various tissues, including the jejunum. Mature JT are a very rare type of tumor. No case report of a mature jejunal teratoma has previously been published. Our patient underwent surgery at the age of 15 years, which, in theory, could increase the risk of tumor malignancy. However, the patient showed good clinical and laboratory results before and during surgery, and no tumor spread was noted. Anatomical pathology also indicated a good prognosis. Histopathological results suggested a mature teratoma. Workup for the tumor markers  $\alpha$ FP and  $\beta$ -hCG 3 months after the operation show normal values. Our patient had recurrent anemia prior to surgery, which could have been caused by occult blood from the mass. Unfortunately, we did not perform FOBT or peripheral blood smear to confirm the true cause of anemia. Approximately 1.5 years after surgery, no complaint of abdominal mass or general weakness due to anemia was made. The prognosis of this patient was good.

## REFERENCES

1. Sowińska PE. Neuroendocrine tumors: Clinical, histological and immunohistochemical perspectives and case report - mature teratoma in a 16-year-old girl. *Pathophysiology* 2021;28:373-86.
2. Pankaj H, Kartik CM, Anjan D, Bidyut D. Childhood gastric teratoma: A case report. *India. Indian J Pediatr Surg* 2018; 2(2): 139-41.
3. Szu TC, Hong SL, Jin CS, Chia TS. Congenital immature teratoma originating from the jejunum. *J Pediatr Surg* 2007;42:1600-3.
4. Jeong HC, Cha SJ, Kim GJ. Rapidly grown congenital fetal immature gastric teratoma causing severe neonatal respiratory distress. *J Obstet Gynaecol Res* 2012; 38: 449-51.
5. Jean ML, Pramod SP, Kenneth S. Teratomas and other germ cell tumours. In: Goerge WH, Patric M, Shawn DSP, Editors. *Holcomb and Ascraft Pediatric Surgery, 7th Edition*. Elsevier; 2020:1066-2020.
6. Rescorla FJ. Teratomas and other germ cell tumours. In: Arnold GC, Editor. *Textbook of pediatric surgery, 7th Edition*. Elsevier; 2012: 507-18.
7. Lam KY, Lo CY. Teratoma in the region of adrenal gland: A unique entity masquerading as lipomatous adrenal tumor. *Surgery* 1999;126:90-4.