

# Gastric perforation in a 5-day-old infant: A case report

Luh Putu Neolita Pradnya Wineni, MD<sup>1</sup>, Ariandi Setiawan, MD<sup>2</sup>

<sup>1</sup>Pediatric Surgery Resident, Airlangga University Faculty of Medicine, Dr. Soetomo Regional Public Hospital, Surabaya, East Java, Indonesia, <sup>2</sup>Pediatric Surgeon, Department of Surgery, Pediatric Surgery Division, Airlangga University Faculty of Medicine, Dr. Soetomo Regional Public Hospital, Surabaya, East Java, Indonesia

## SUMMARY

**Gastric perforation in a new-born signifies a surgical emergency requiring immediate attention. Therefore, early diagnosis is expected to lead to a better prognosis. Any infant presenting with sudden and severe abdominal distention should be suspected of gastric perforation. Diagnosis is confirmed by pneumoperitoneum in the plain abdominal X-ray, including anteroposterior and lateral views. In this study, we report a case of a 5-day-old neonate, who was diagnosed with gastric perforation and accordingly proceeded with primary surgical repair.**

## INTRODUCTION

Gastric perforation in neonates is a serious and life-threatening condition associated with high morbidity and mortality rates. Spontaneous gastric perforation has been reported in approximately 1 in 2900 live births and accounts for 10-15% of all gastrointestinal perforation cases in neonates and children.<sup>1,2</sup>

Siebold in 1926 was the first to describe spontaneous gastrointestinal perforation. Stern, in his research, reported surgical repair, while Leger, in 1950, described the first successful repair of gastric perforation in neonates.<sup>3,4,7</sup> The causes of neonatal gastric perforation can be categorized into two groups: spontaneous/idiopathic or traumatic/iatrogenic. Spontaneous or idiopathic gastric perforation refers to that caused by unidentified underlying diseases and accounts for most cases. Meanwhile, iatrogenic gastric perforation case is usually caused by gastric tube insertion or intubation attempts.<sup>2,9</sup>

## CASE REPORT

A 5-day-old female infant presented with sudden abdominal distention since a day prior to her admission. Further history was taken from her parents, and we identified that her entire abdomen was distended and improved after the insertion of orogastric tube at the previous hospital. The frequency of her bowel movement found to be normal, ranging from 3 to 4 times a day with soft consistency. She had fever since abdominal distention and her abdominal skin appeared reddish on examination. The patient was referred from Walisongo General Hospital in Gresik and was treated with intravenous D10 (300 cc/24-h), ceftiofur (150mg /12-h), and santagesik (30 mg/8-h).

Antenatal history revealed that the patient was born a second pregnancy that was routinely checked by a midwife.

Antenatal ultrasonography (USG) was performed once during pregnancy by an obstetrician-gynecologist to present normal finding. Due to placenta previa, she was delivered by cesarean section at 38 – 39th week of gestation, with a birth weight of 3000 g and an APGAR score of 7 – 8.

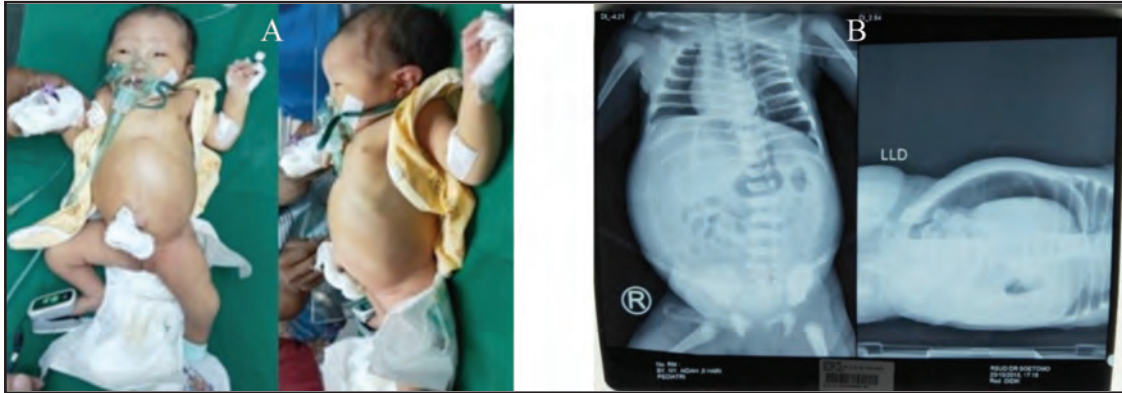The patient appeared lethargic and icteric (zone 2 on Kramer's scale) during her physical examination. The abdomen was found distended with reddish abdominal skin (Fig. 1A). Her bowel sounds decreased on auscultation, while the dullness of liver diminished on percussion. From rectal touché examination, we found that the tonus of sphincter ani collapse and mucosal surface was normal. Faeces, without blood, was found on the post-examination gloves. Urine output was 18 cc/2-h during the observation period at the emergency department (equal to 3 cc/kg/h).

The complete blood count test, result: hemoglobin 12.5 g/dL, WBC 3,980/uL, and platelets 139,000/uL. Her serum electrolytes levels were as follows: sodium 131 mEq/L, potassium 6.7 mEq/L, and chlorides 96 mEq/L. Her bleeding time was within normal limits. We performed plain thoracoabdominal X-ray or babygram as well as left lateral decubitus (LLD) imaging to reveal pneumoperitoneum, and the tip of the orogastric tube that appeared outside of the gastric contours, extending to the pelvic cavity. The LLD view revealed free intraperitoneal air (Fig. 1B).

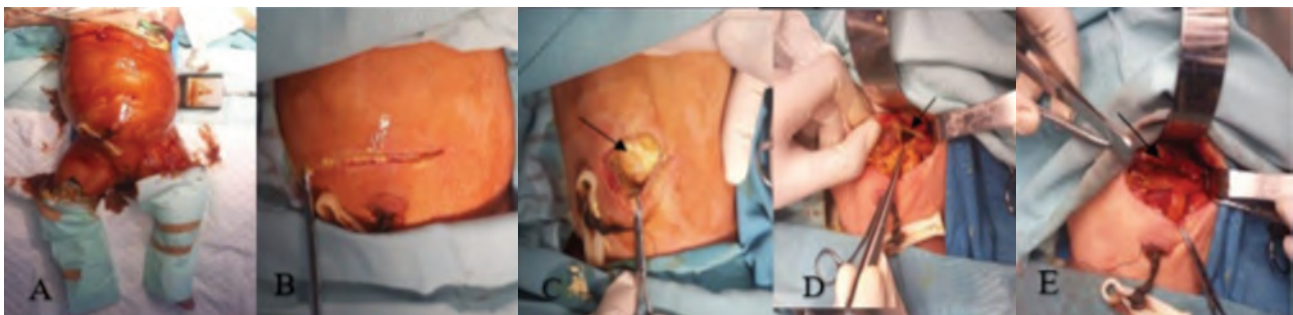
Based on the results of her clinical examination and the subsequent workups, we suspected perforation of a hollow organ, and thus an emergency surgery was accordingly performed via explorative laparotomy for the primary repair of gastric perforation.

Prior to incision, 90 mg of intravenous cefazolin was administered as the surgery was considered susceptible to contamination. The surgical field was then disinfected, and the patient was draped with sterile surgical drapes. Upon transversal supraumbilical incision, air and faecal matters burst out when we reached the peritoneal cavity. Gastric perforation with a diameter of approximately 5 cm was identified at the posterior aspect of the gastric fundus near the greater curvature. Several minor tissues surrounding the stomach was detected in the slough. We also observed grade II-III intestinal adhesion. The peritoneal cavity lavage was accordingly performed. The minor tissues of the stomach were excised, and primary suturing of the perforated region was performed using 4.0 silk thread via simple interrupted and overhecting sutures. Further evaluation of the intestines including jejunum, ileum, and colon revealed no

Corresponding Author: Luh Putu Neolita Pradnya Wineni  
Email: wineini@gmail.com



**Fig. 1:** A. The patient's abdomen appeared distended and reddish with dilated veins. B. Babygram revealed pneumoperitoneum and the tip of the orogastric tube appeared outside of gastric contours and the LLD view showed free intraperitoneal air.



**Fig. 2:** A. Disinfecting the surgical field and draping the patient. B. Transversal supraumbilical incision. C. Air and fecal matters burst out when the peritoneal cavity was reached (arrow). D. Gastric perforation with a diameter of approximately 5 cm detected at the posterior aspect of gastric fundus near the greater curvature (arrow). E. Primary suturing using a 4.0 silk thread simple interrupted overhecting sutures (arrow).

abnormalities. Another peritoneal lavage was then performed, and the surgical incisions were closed. We did not perform any histopathological investigation.

The patient was admitted to the Neonatal Intensive Care Unit (NICU) for her post-operative care. Her respiration status deteriorated 8 h post-op, requiring mechanical ventilation as follows: PEEP 2, FiO<sub>2</sub> 35%, and the oxygen saturation was maintained >90%. She also went into a hypotensive state, but her hemodynamic status improved after resuscitation using intravenous saline, blood transfusion, and dopamine. Her abdomen was soft on palpation, showing no distention and discoloration. Total parenteral nutrition was administered via central vein catheter.

On the second day post-op, the patient was hemodynamically stable, and the ventilator parameters were reduced to the following: PEEP 3, FiO<sub>2</sub> 25%, and oxygen saturation > 90%. She was weaned-off the ventilator on the fifth day post-op when her condition had clearly improved. She was able to breath spontaneously supported by a nasal cannula. On the tenth day post-op, she resumed breastfeeding with no evidence of vomiting or bowel obstruction. She was finally discharged after 25 days of hospitalization, and we found that she even gained weight.

## DISCUSSION

Neonatal gastric perforation is classified as either spontaneous (idiopathic) or traumatic. However, in most cases, the aetiology is most likely multifactorial.<sup>3,5</sup> Sudden and unexplained abdominal over-distention that leads to organ perforation is regarded as a spontaneous one. Most cases presented in the first 7 days of life with various clinical manifestation.<sup>1,6</sup>

Chieh-Mo Lin et al. outlined that gastric acidity in a newborn is exceptionally high during the first week of life. While this does not indicate potential causality, it can possibly contribute to gastric perforation.<sup>8</sup> Another study by Chen et al. analyzed that preterm neonate with gastric perforations is at 4.21-times higher risk of mortality than full-term neonates.<sup>4</sup>

Infants with gastric perforation may present with respiratory distress, hemodynamic instability, and even symptoms suggestive of shock such as hypothermia, cyanosis, poor peripheral perfusion, and diminished urine output. The abdomen may also appear distended in a short amount of time, which may be a sign of peritoneal irritation.<sup>4</sup> In our case report, the patient was a 5-day-old infant who presented with sudden abdominal distention since 1 day before admission. We also recorded a history of fever that started at

the same time has the onset of distention. On clinical examination, marked abdominal distention, reddish abdominal skin, with dilated veins were observed. Bowel sounds were decreased on auscultation, and no liver dullness was found on percussion. Urine output upon observation at emergency department was 18 cc/2-h (equal to 3 cc/kg/h).

Laboratory studies are performed to aid diagnosis in gastric perforation cases, such as blood cultures, leukocytes count, haemoglobin, haematocrit, platelet count, electrolytes profile, and blood gas analysis.<sup>1,5</sup> In this patient, we observed workup results as follows: haemoglobin 12.5 g/dL, WBC3,980/uL, and platelet 139,000/uL. Serum electrolytes level were as follows: sodium 131 mEq/L, potassium 6.7 mEq/L, and chlorides 96 mEq/L.

Plain abdominal X-ray was also performed to aid diagnosis, which showed massive pneumoperitoneum indicated by the presence of air under diaphragm that extended laterally as well as subcutaneous emphysema, pneumoscrotum, ascites, or even the tip of oro- or nasogastric tube that extends beyond the gastric contours.<sup>2,3,6</sup> The plain thoracoabdominal X-ray or babygram as well as LLD view X-ray of this patient showed pneumoperitoneum and the tip of orogastric tube that appeared outside of the gastric contours, extending to pelvic cavity.

The initial management included hemodynamic stabilization by administering bolus intravenous fluid or blood transfusion, the administration of broad-spectrum antibiotic in case of infection, and primary peritoneal drainage to achieve better clinical outcome.<sup>1,2,7,8</sup> We performed early resuscitation on our patient but no primary peritoneal drainage, since emergency surgery could be arranged immediately, and the patient was placed in an optimal condition prior the surgery.

The main therapy for gastric perforation is surgical exploration, which is started via a transversal supraumbilical incision and evacuation of the peritoneal fluid, followed by exploration of the perforation site. When gastric perforation is not detected, careful exploration of the gastroesophageal junction, duodenum, small intestines, and large intestines must be performed. If gastric perforation is detected, which is usually near the greater curvature, then it must be closed in one or two layers and can be strengthened using an omental patch. After repairing the perforation, the peritoneal cavity lavage is usually performed using a warm saline solution.<sup>5,7,8</sup> In this patient, we performed explorative laparotomy and primary repair on the site of gastric perforation. No histopathological investigation was performed in this study and hence we could not identify the cause of the perforation.

Supportive care and resuscitation measures were continued post-op, broad-spectrum antibiotic administration, gastric acid suppression therapy, total parenteral nutrition, as well as gastric decompression. Enteral nutrition was started after the patient's condition had stabilized. Several of surgeons perform contrast studies prior to initiation of enteral nutrition.<sup>7,8,16</sup> The present patient was admitted to the (NICU)

for post-operative care. Her respiration status deteriorated 8 h post-op and required mechanical ventilation. She also went into a hypotensive state, hence we performed resuscitation using intravenous saline, blood transfusion, and dopamine. Total parenteral nutrition was administered via the central vein catheter. The next day, the patient's condition had improved, and she was weaned-off the ventilator on her fifth day post-op. On the tenth day post-op, she resumed breastfeeding and was finally discharged after 25 days of hospitalization.

The clinical factor associated with poor prognostic outcome included sepsis, metabolic acidosis, and hyponatremia. Early diagnosis and identification of perforation and appropriate supportive treatment was deemed essential for the best possible clinical outcome.<sup>1,4,9</sup>

## CONCLUSION

Gastric perforation in newborns is a serious and life-threatening condition. Newborns, especially those of premature or low birth weight, who present with progressive abdominal distention with or without pneumoperitoneum should be suspected of gastric perforation.

Initial management of gastric perforation includes early diagnosis, resuscitation, stabilization, and surgical exploration. Early resuscitation can serve as a primary management for neonates to immediately stabilize their general condition prior to the main surgery, in order to achieve the best possible clinical outcome.

## REFERENCES

1. Adam CA and Robert KM. Gastric perforation in newborn surgery, 4th ed. CRC Press; 2018:65-570.
2. Holcomb GW, Murphy JP, St Peter SD. Lesions of the Stomach in Holcomb and Ashcraft's Pediatric Surgery. 7th edition. Elsevier Health Sciences. 2019; 478-88.
3. Duran R, Inan M, Vatansever U, Aladağ N, Acunaş B. Etiology of neonatal gastric perforations: review of 10 years' experience. *Pediatr Int* 2007; 49(5):626-30.
4. Chen TY, Liu HK, Yang MC, Yang YN, Ko PJ, Su YT, et al.. Neonatal gastric perforation: a report of two cases and a systematic review. *Medicine* 2018;97(17).
5. Oztürk H, Onen A, Otçu S, Dokucu AI, Gedik S. Gastric perforation in neonates: analysis of five cases. *Acta Gastro-Enterol Belg* 2003;66(4):271-3.
6. Cardiel-Marmolejo LE, Peña A, Urrutia-Moya L, Crespo-Smith D, Morales-Vivas CA, Camacho-Juárez KV, and Roque-Ibáñez C. Neonatal gastric perforation: a case report. *Rev Medica del Hosp Gen de Mex* 2018; 81:36-40.
7. Prashant SP, Abhaya G, Paras LK. Gastric perforation in two neonates: Spontaneous? Secondary to feeding tube: A case report. *SM J Pediatr Surg* 2016;2(1):1009.
8. Kshirsagar AY, Vasisth GO, Ahire MD, Kanojiya RK, Sulhyan SR. Acute spontaneous gastric perforation in neonates: a report of three cases. *Afr J Paediatr Surg* 2011;8(1):79.
9. Kim E. Gastric perforation in a newborn. *J Pediatr Surg Case Rep* 2019; 43:87-9.
10. Desouki K, Osman MK. Gastric perforation in neonates: analysis of five cases. *Ann Pediatr Surg* 2006;2(1):45-7.