

# Acute pericarditis as a clinical manifestation in COVID-19 infection in a district hospital setting

Seen Sze Tai, MD (UKM), Siok Sian Siek, MD (MSMU), Siti Hajar Mohammad Farid, MD (NNSMA), Mohamad Azri Ab Majid, MBBS (JJMMC), Huang Hin Chin, MRCP (UK), Pek Woon Chin, MMED (UM), MRCP (UK)

Hospital Enche Besar Hajjah Khalsom

## SUMMARY

The global outbreak of coronavirus disease 2019 (COVID-19) pandemic has heavily impacted the health service, leading to increased mortality and morbidity. Although known to manifest primarily as a respiratory illness, there are reports of cardiac involvement as extrapulmonary manifestation. We are reporting a case of pericarditis in a young patient who presented with only cardiac symptoms in COVID-19. He was admitted to the hospital for observation and treated with oral colchicine and oral ibuprofen. His conditions improved and subsequently discharged well. Acute pericarditis can present as part of the COVID-19 extrapulmonary spectrum. Therefore, it is important and challenging for clinicians to recognise the atypical presentations of COVID-19 to reduce morbidity and mortality.

## INTRODUCTION

COVID-19 is an illness caused by the SARS-CoV-2 virus, which has immensely burdened the public healthcare. It has been linked to a variety of disease manifestation including pulmonary and extrapulmonary. Myocarditis and pericarditis have been reported amongst the extrapulmonary manifestations of COVID-19 infection.<sup>1</sup> Higher incidences of thromboembolic events, leading to coronary thrombosis in COVID-19 infections, were reported compared to pericarditis and myocarditis, which may manifest at any stage of the disease. Therefore, it serves as a challenge for clinicians to diagnose and monitor the disease progression. In some cases, pericardiocentesis is often required due to pericardial effusion.<sup>1</sup> We next describe a case of acute pericarditis as a result of COVID-19 infection.

## CASE REPORT

A 21-year-old man was admitted in early March 2021 with a chief complaint of severe chest pain for four days, associated with shortness of breath and diaphoresis. The chest pain was described as pleuritic in nature (pain score of 7/10), aggravated by lying down and deep inspiration, and slightly relieved by sitting upright. He has a body mass index (BMI) of 27 kg/m<sup>2</sup>, working as an operator at a tofu factory with no known medical illness or surgeries prior to admission. He was not vaccinated against COVID-19. He denied any food or drug allergies. In addition, there was no family history of cardiac disease or sudden deaths. He is an active cigarette smoker with 7-pack-year exposure. He denied any high-risk behaviour such as illicit drug use.

He was hemodynamically stable (blood pressure of 106/62 mmHg; pulse rate of 96 beats/min; oxygen saturation 98% under room air; febrile with a body temperature of 38°C). Examination revealed that there were no signs of acute cardiac failure and no added heart sounds nor pericardial rub.

ECG showed saddle-shaped ST segment elevation at lead I, II, AVL, V2–V6 and PR segment depression in inferior leads with PR segment elevation in lead aVR (Figure 1). Nasopharyngeal swab for RT-PCR SARS-CoV-2 came back as positive, and he was thereafter managed and monitored in the COVID-19 ward. The chest radiograph was normal (Figure 2).

Serum biochemistry showed raised troponin I of 0.1 ng/ml (normal range < 0.02 ng/ml), creatinine kinase of 760 U/L (Normal range 26 U/L–174 U/L), and inflammatory markers (white blood cell count 19600/mm<sup>3</sup>, C-reactive protein 305.4 mg/L, ferritin level 635.1 ug/L). Echocardiogram revealed good left ventricular function with ejection fraction of 64% with no pericardial effusion, and all chamber sizes were normal. Infective screening, coagulation profile, and kidney and liver function tests were normal. However, blood samples for viral panel to look for other causative viral causes were not done due to limitation of resources in district hospital setting.

The case was consulted with the cardiologist on-call at a tertiary hospital, following which an impression of acute pericarditis secondary to COVID-19 infection was made, based on the clinical, ECG, and laboratory findings. Treatment was initiated for this patient with oral colchicine 0.5 mg thrice a day and oral ibuprofen 400 mg thrice a day.

He was discharged well on day 14 of illness with a follow-up appointment to the cardiology unit in a tertiary centre. Prior to which, repeated ECG showed sinus rhythm with resolution of ST segments, CRP level of 1.1 mg/L, and a normal creatinine kinase level of 105 U/L. Serial troponin-I level was not performed in this case in view of limited resources in our district hospital setting.

## DISCUSSION

COVID-19 infection has led to various clinical pathologies relating to the cardiovascular system. There are various reports on COVID-19-related cardiac injuries that have

This article was accepted: 13 March 2022

Corresponding Author: Seen Sze Tai

Email: tssze87@gmail.com

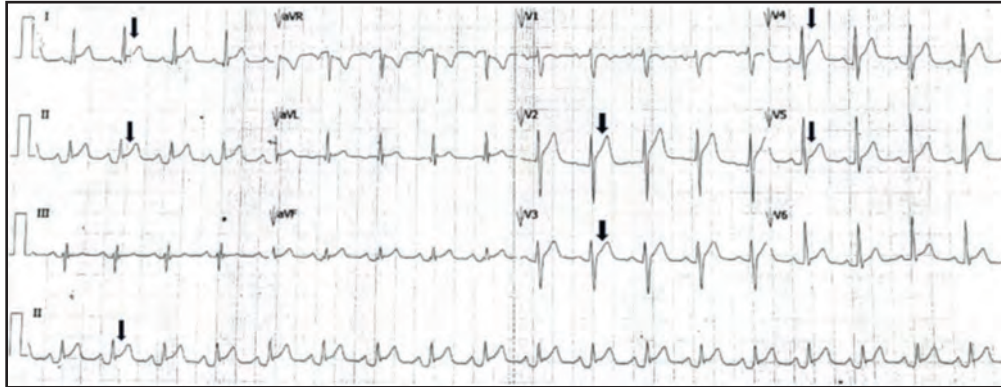


Fig. 1: ECG with ST segment elevation and PR depression.

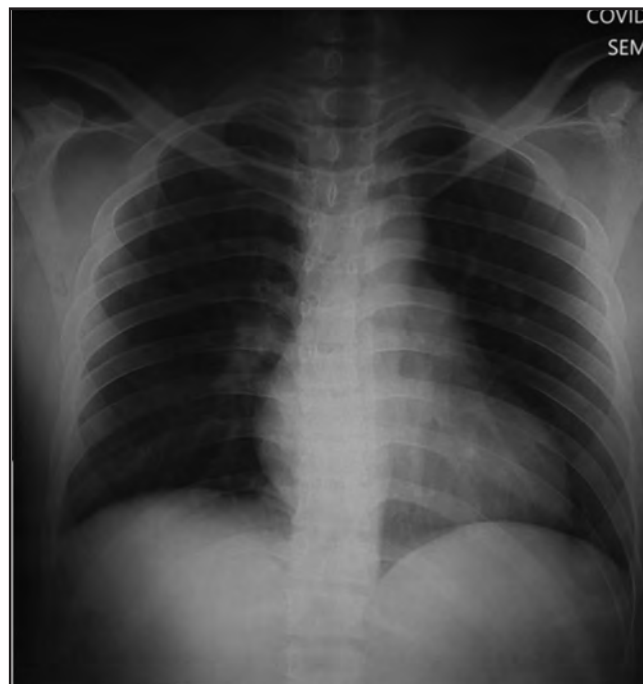


Fig. 2: Chest X-ray showed clear lung field.

caused an increase in the mortality rate.<sup>2</sup> The actual mechanism is unknown. However, it is believed to be related to the raised inflammatory markers during the cytokine storm that has caused worsening of heart function and cardiac injury.

Acute pericarditis is the most common disease of the pericardium where inflammation of the pericardium is frequently painful and causes fluid to enter the pericardial space. The exact aetiologies are highly variable, commonly seen in viral infections, including coxsackie, enterovirus, herpes simplex, cytomegalovirus, H1N1, respiratory syncytial virus, parvovirus B19, influenza, varicella, HIV, rubella, echovirus, and hepatitis B and C.<sup>3</sup> In this report, it was believed that the patient suffered from acute pericarditis secondary to SARS-CoV-2 (viral infection). Pericardiocentesis served as the gold standard to determine the underlying cause but was not performed in this case due to negative findings from the echocardiogram.

The patient complained of severe pericarditis chest pain, and the ECG revealed widespread ST elevation. Furthermore, inflammatory markers such as CRP, troponin I, ferritin, and WBC were elevated. This patient met two of the four criteria that led to the diagnosis of acute pericarditis.<sup>4</sup> The diagnosis of pericarditis was based on the clinical findings, ECG, and ECHO. Myocarditis frequently manifests as heart failure symptoms, an ECG with dysrhythmias, or an ECHO with hypokinesia. This patient has none. According to studies, 30–50% of patients with acute pericarditis have elevated cardiac troponin I.<sup>5,6</sup> Troponin I was tested with the Quidel Triage Troponin I fluorescence immunoassay, which has a minimum sensitivity of 95%. This patient has a high troponin level (0.1 ng/ml), whereas the normal range is 0.0–0.02 ng/ml. A large pericardial effusion, tamponade, fever > 38°C, subacute onset, and failure to respond to aspirin or NSAIDs are all poor prognostic factors.<sup>4</sup> A study conducted by Imazio et al.<sup>7</sup> showed that pericardial effusion was reported as high as 60% in patients with acute pericarditis. In

this case, he did not have any of the risk factors for poor prognosis and recovered gradually with no complications.

Further imaging such as CTCA and cardiac MRI may offer additional information regarding pericardial thickening, quantify systolic function, myocardial inflammation, and small effusions. As a district hospital with resource limitations, such imaging is not available to enable better understanding of the disease progression or prognostication in this patient.

Acute pericarditis is usually self-limiting, although it may recur. Treatment usually includes the use of non-steroidal anti-inflammatory drugs (NSAIDs), colchicine, and treating the underlying causative disease. At the beginning of the COVID-19 pandemic, there was a concern regarding the use of NSAIDs in COVID-19 patients. It is believed that NSAIDs may increase disease severity in patients with COVID-19. Various studies have been conducted and dismissed this idea.<sup>8,9</sup> Colchicine is an anti-inflammatory drug that is used to treat a variety of conditions, including gout, recurrent pericarditis, and familial Mediterranean fever. The use of colchicine in COVID-19 has been controversial. The COLCORONA and RECOVERY trials did not demonstrate any benefit in the colchicine arm, whereas the GRECCO-19 trial showed that colchicine reduced the primary clinical endpoint of deterioration in clinical status from baseline.<sup>10</sup> As for this patient, he was treated with both colchicine and ibuprofen for 1 week. His condition improved in the ward, and he was discharged home.

## CONCLUSION

Acute pericarditis can be a clinical presentation of COVID-19 patients. Our understanding of the COVID-19 disease spectrum is limited, and pericarditis may be underdiagnosed in most cases. Therefore, this case report emphasises the importance of recognising the atypical presentation of COVID-19 so that the patient can be treated promptly to reduce morbidity and mortality.

## REFERENCES

1. Jassim ZS, Smitha AK, Ashfaq AP. Myocarditis and pericarditis in patients with COVID-19. *Heart Views* 2020 Jul-Sep; 21(3): 209-14.
2. Shi s, Qin M, Shen B, Cai Y, Liu T, Yang F et al. Association of cardiac injury with mortality in hospitalized patients with COVID-19 in Wuhan, China. *JAMA Cardio* 2020;5.
3. Kytö V, Sipilä J, Rautava P. Clinical profile and influences on outcomes in patients hospitalized for acute pericarditis. *Circulation* 2014; 130: 1601-6.
4. Adler Y, Charron P, Imazio M, Badano L, Barón-Esquivias G, Bogaert J, et al. 2015 ESC Guidelines for the diagnosis and management of pericardial diseases. *European Heart Journal* 2015 Nov 7; 36(42): 2921-64.
5. Lange RA, Hillis LD. Clinical practice: Acute pericarditis. *N Engl J Med* 2005; 352(11): 1163.
6. E Bonnefoy , P Godon, G Kirkorian, M Fatemi, P Chevalier, P Touboul. Serum cardiac troponin I and ST-segment elevation in patients with acute pericarditis. *Eur Heart J* 2000; 21(10): 832-6.
7. Imazio M, Demichelis B, Parrini I, Giuggia M, Cecchi E, Gaschino G, et al. Day-hospital treatment of acute pericarditis: A management program for outpatient therapy. *Journal of the American College of Cardiology* 2004; 43(6): 1042-6.
8. Drake TM, Fairfield CJ, Pius R, Knight SR, Norman L, Girvan M, et al. Non-steroidal anti-inflammatory drug use and outcomes of COVID-19 in the ISARIC Clinical Characterisation Protocol UK cohort: A matched, prospective cohort study. *Lancet Rheumatol* 2021 (3).
9. Chandan JS, Zemedikun DT, Thayakaran R, Byne N, Dhalla S, Acosta-Mena D, et al. Non-steroidal antiinflammatory drugs and susceptibility to COVID-19. *Arthritis Rheumatol* 2021(73).
10. COVID-19 Treatment Guidelines Panel. Coronavirus Disease 2019 (COVID-19) Treatment Guidelines. National Institutes of Health [cited Aug 2021]. Available from: <http://www.covid19treatmentguidelines.nih.gov>.