

# A case report of transverse myelitis in a patient with human immunodeficiency virus

Siti Khairizan Rahim, MRCP<sup>1</sup>, Wong Teng Kang, MBBS<sup>1</sup>, Suraya Hanim Abdullah Hashim, MMED<sup>2</sup>

<sup>1</sup>Internal Medicine Department, Hospital Ampang, Ministry of Health of Malaysia, <sup>2</sup>Infectious Disease Unit, Hospital Ampang, Ministry of Health of Malaysia

## SUMMARY

Acute or subacute transverse myelitis is a rare disease caused by inflammation of the spinal cord. The extensive differential diagnosis of this disease require physician to timely decide the necessary investigations and plan for effective treatment. We report a case of anomalous multifactorial transverse myelitis in a patient with human immunodeficiency virus (HIV) who responded well with multimodal therapy. The patient was given immunosuppressive agent and plasma exchange for the demyelinating disease as well as antibiotics for neurosyphilis, antiviral for cytomegalovirus (CMV) neurologic disease, and highly active antiretroviral therapy (HAART). Three months after his first presentation, patient showed full neurology recovery and suppressed HIV viral load.

## INTRODUCTION

Acute or subacute transverse myelitis is a rare disease that can cause devastating permanent disabilities in a young adult. The aetiology of transverse myelitis can be grouped into demyelination, autoimmune, infection, and paraneoplastic.<sup>1</sup> It is crucial for physicians to decisively investigate and timely initiate the right treatment. Those decisions will have an impact on the outcome of the patient. The clinical presentation of the disease depends on the extent of the spinal cord involvement with varying degrees of motor, sensory, and autonomic dysfunction. Primarily, after excluding compressive myelopathy by Magnetic Resonance Imaging (MRI), the evidence of spinal cord inflammation must be certain through the lumbar puncture findings of cerebrospinal fluid leucocytosis with raised protein. In HIV-infected patients, the management becomes more complicated as more potential opportunistic infections that affect the neurology need to be considered.

## CASE REPORT

A 29-year-old male presented to Emergency Department after one week history of progressive lower limb weakness that affected the right leg, which then slowly progressed to the left leg within three days. He progressed from mild difficulty to walking and frequently tripping over the left leg to unable to stand steadily for one day. On the next day, patient developed acute urinary retention, resulting in a prompt visit to the Emergency Department. He has no fever, respiratory

infection symptoms, or diarrhoea prior to the onset of weakness. He had no fall or trauma recently. There was no significant previous medical or surgical history.

Upon admission, his Glasgow Coma Scale (GCS) was 15. He was afebrile, blood pressure was 122/82 mmHg, pulse rate 87 was beats per minute, and respiratory rate was 18 breaths per minute with Spo<sub>2</sub> 98% on room air. Neurological examination revealed hypertonia of the right leg and normotonic left leg, reduced power over the right leg (grade 3/5) and left leg (grade 0/5). Hyper reflexes of bilateral knee, ankle jerk, and positive Babinski over the right side were reported. There was reduced sensation from T4 level downwards and loss of anal sphincter tone. There was no ulcer, rash, lymphadenopathy, joint tenderness, or swelling. Overall eye examination was normal with no signs of optic neuritis or uveitis. The other physical finding was unremarkable.

Routine laboratory investigations showed the following: haemoglobin level 12.3 g/dL, platelet count 269 x 10<sup>9</sup>/L, white cell count 8 x 10<sup>9</sup>/L, urea 4.1 mmol/L, sodium 137 mmol/L, potassium 3.8 mmol/L, creatinine 73 µmol/L, calcium 2.15 mmol/L, and albumin 43 g/L. He was biochemically euthyroid. HIV rapid test and subsequent HIV antibody test were positive. ESR was 27 mm/hour and C-reactive protein was less than 4 mg/L upon admission.

The initial chest radiograph and computed tomography (CT) scan of the brain were normal. The MRI of the spine was performed on the third day of admission and noted intramedullary enhancement of patchy high T2 signal with contrast enhancement at T4 to T6 level measuring 4.8 cm in length and another long segment intramedullary T2 hyperintense signal without significant contrast enhancement at T3 to T10 level likely to be syrinx. There was no evidence of spinal cord compression (Figure 1(A) and 1(B)).

Lumbar puncture was performed on the fourth day of admission. The opening pressure was 10 cmH<sub>2</sub>O. Cerebrospinal fluid (CSF) investigations revealed low glucose (1.78 mmol/L), high protein (1.17 g/L), and mild lymphocytosis. CSF India Ink test was negative, and gram stain was negative. Blood for CMV PCR was detected at log 1.34 but CSF test for CMV was not sent during the first lumbar puncture, and patient was not keen for repeat test. Syphilis

This article was accepted: 13 February 2022  
Corresponding Author: Dr. Siti Khairizan Binti Rahim  
Email: sitikhairizanrahim@gmail.com

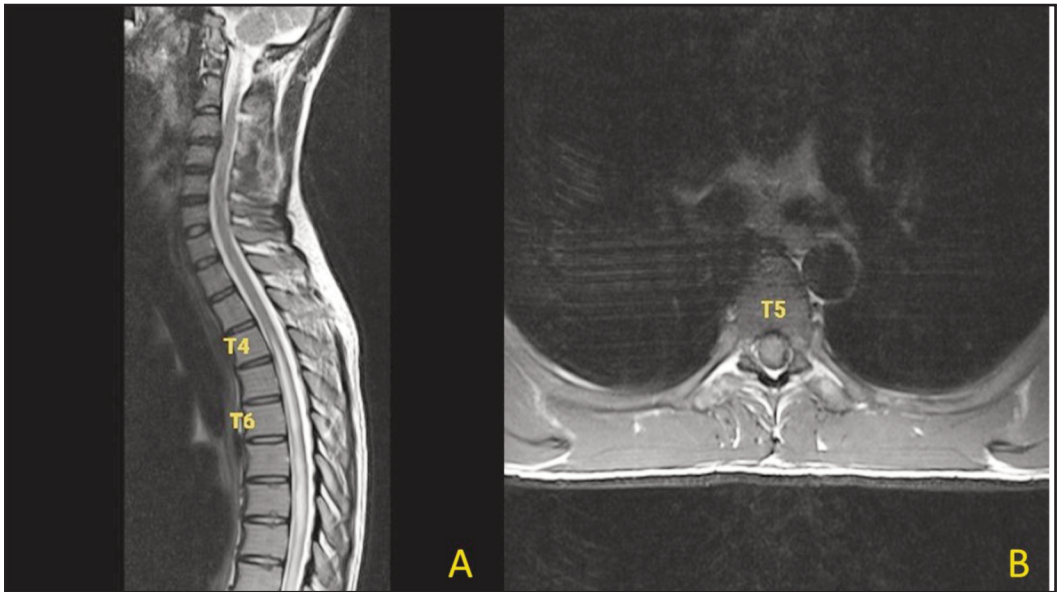


Fig. 1: T2-weighted Magnetic Resonance Image. (A) Sagittal view shows intramedullary enhancement of patchy T2 hyperintense lesion with contrast enhancement at T4 to T6 level (B) Axial view shows central intramedullary contrast-enhanced lesion at T5 level.

Types of treatment	Treatment received (day of admission)										
Antibiotic	IV Ceftriaxone then Benzylpenicillin (days 1–14)										
Corticosteroid	IV Methylprednisolone (days 4–8)			Followed by oral prednisolone (tapering dose)						stop	
Plasma exchange	Plasma exchange (days 14, 16, 18)										
Antiviral	IV Ganciclovir (days 10–30)					Highly active antiretroviral therapy initiation (day 31)					continue
	Admitted					Discharged					
Neurological symptoms	Symptoms started	Symptoms worsened		Symptoms started to improve				Symptoms fully recovered	No new Symptom		
Timeline of symptoms (week)	0	1	2	3	4	5	6	12	52		

Fig. 2: Timeline of neurological symptom progression and treatment received by patient.

test was positive with VDRL titre of 1:32 but negative TPPA. Unfortunately, the most diagnostic neurosyphilis test such as CSF test for VDRL or FTA-ABS are not available in Malaysia.

He was initially treated with intravenous ceftriaxone on admission as empirical treatment for neurological infection and subsequently switched to benzylpenicillin as the first line therapy for neurosyphilis. Considering the possibility of demyelinating disease, on the fourth day of admission, patient was given a course of intravenous

methylprednisolone, 1 g daily for five days, and followed by tapering dose of oral prednisolone. At day 10 of admission, intravenous ganciclovir was initiated to treat cytomegalovirus infection as the blood test genome was detected and as the clinical condition did not improve.

Plasma exchange was initiated at day 14 of admission after consultation from a neurology team in view of the poor response to the glucocorticoid therapy, concurrent antibiotic and antiviral treatment. Remarkable neurology

improvement was seen as the patient was able to stand with support after the third session of plasma exchange. His power over the right leg improved to grade 4/5 and left leg power improved to grade 2/5. However, plasma exchange was stopped after three sessions due to intravenous access issue.

In summary, he received a five-day course of intravenous methylprednisolone followed by tapering dose of oral prednisolone, three sessions of plasmapheresis on every other day, 14 days of treatment for neurosyphilis, and 21 days of treatment for CMV myelitis. Highly active anti-retroviral therapy (HAART) was initiated as soon as the patient completed the CMV treatment. His neurology deficit improved gradually and managed to be discharged after five weeks of hospitalisation with wheelchair and walking frame aided ambulation (Figure 2).

Some of the important pending results were reviewed after patient was discharged. The CSF oligoclonal band was detected, and other CSF results such as viral culture and mycobacterium tuberculosis culture were negative. Anti-nuclear antibody and anti-N-methyl-d-aspartate receptor (NMDAR) were all negative. The final diagnosis was revised as acute transverse myelitis due to demyelinating disease, CMV myelitis, and neurosyphilis.

After three months from the onset of neurology deficit, the patient was able to walk without aid to the consultation room during clinic review. There were no new symptoms, no residual leg weakness, or problem with urination. He complied with the HAART treatment and tapering oral prednisolone as advised. He is still on regular outpatient follow-up. The patient remains completely well until the recent review one year after the onset of the weakness.

## DISCUSSION

Acute transverse myelitis can be the initial presentation of demyelinating disease. The two important points from this case that urged the decision for multimodal therapy approach are being in the common age group for the onset of demyelinating disease and the newly diagnosed HIV status.<sup>1,3</sup>

Multiple sclerosis is the most common demyelinating disease of the central nervous system and predominantly follows the clinical subtype of relapsing–remitting at disease onset. However, for this case report, there is still insufficient criteria to fulfil the requirements of diagnose multiple sclerosis diagnosis. Further MRI of the brain and spine follow-up as well as other tests at the neurology center such as evoked potential study, will be a valuable tool to consolidate the diagnosis.<sup>3</sup>

The degree of symptom resolution and recovery for demyelinating disease is variable. Plasma exchange can be beneficial in patients who do not respond to glucocorticoid therapy and may result in faster improvement of neurological symptoms as encountered in this case report.<sup>1,4</sup> As for newly diagnosed HIV-positive patients who exhibited neurological symptoms, this may represent the first opportunistic infection in the central nervous system as the

degree of immunosuppression was still uncertain. Although toxoplasmosis and tuberculosis are more common infections, in this case, there was no clinical evidence and investigation result to suggest such disease. Therefore, infective myelitis due to syphilis and CMV were considered.<sup>5-7</sup>

Generally, syphilitic myelitis is rare but it is the most potential curable form of neurosyphilis. It was previously reported that MRI spine finding of syphilitic myelitis showed high signal intensity in the T2-weighted images.<sup>5</sup> Both syphilis and CMV myelitis may have abnormal cerebrospinal fluid analysis similar to the demyelinating disease, which are pleocytosis and raised protein.<sup>5,7</sup>

However, CMV infection commonly affects immunocompromised patient and may progress to end organ disease. Although neurological disease of CMV is rare, it may cause permanent disabilities without appropriate treatment. The association between the myelitis and the virus is still not well recognised but it may represent a postinfectious transverse myelitis.<sup>1,6,7</sup> In this instance, the patient is often treated with antiviral drugs and corticosteroids.

The most conclusive investigation to diagnose CMV infection in cerebrospinal fluid is by CMV polymerase chain reaction (PCR).<sup>7</sup> Unfortunately, the CSF sample was not sent for the test in this case. However, treatment was started as soon as the CMV detection by serum PCR in order to not miss out the golden time to treat the disease. Subsequently, HAART was initiated just after the completion of intravenous ganciclovir. After the acute phase, rehabilitative care is the next important step to improve functional skills and to prevent secondary complications from immobility. It is crucial to begin occupational and physical therapies early during recovery. In this case, the patient started to show neurological improvement at the second week of hospitalisation. He continues to improve with treatments and rehabilitation programs and neurologically recovered after three months.

The prognosis of the transverse myelitis is variable as the primary disease can be the main contributing predictor. Generally, infectious myelitis will have a better outcome with prompt treatment. However, for demyelinating disease such as multiple sclerosis, the patient needs to be followed up longer to determine the clinical subtypes and to evaluate new evidence of neurology deficit periodically before concluding the long-term prognosis.<sup>2,3</sup>

## CONCLUSION

Acute transverse myelitis has always been a challenging disease to be treated at a non-neurologist centre. The practical approach to manage acute transverse myelitis in a young HIV-infected patient would be ideal to follow the sequence from infection, demyelination, and autoimmune disease. However, the less common aetiology such as paraneoplastic myelitis should also be explored if the patient did not respond to the initial treatment given. This case was reported to promote awareness among physicians of the possible aetiologies for transverse myelitis in immunocompromised patient.

### CONFLICT OF INTEREST

The authors have no conflicts of interest to declare.

### ACKNOWLEDGEMENTS

We would like to thank the Director General of Health Malaysia for his permission to publish this article. Appreciation to all colleagues in the Department of Internal Medicine, Hospital Ampang, who have contributed to the care and management of the patient.

### REFERENCES

1. West TW, Hess C, Cree BA. Acute transverse myelitis: Demyelinating, inflammatory, and infectious myelopathies. *Semin Neurol* 2012; 32(2): 97-113.
2. Borchers AT, Gershwin ME. Transverse myelitis. *Autoimmun Rev* 2012; 11(3): 231-48.
3. Thompson AJ, Banwell BL, Barkhof F, Carroll WM, Coetzee T, Comi G, et al. Diagnosis of multiple sclerosis: 2017 revisions of the McDonald criteria. *The Lancet Neurol* 2018; 17: 162-73.
4. Courtese I, Chaudhry V, So YT, Cantor F, Cortnblath DR, Rae-Grant A. Evidence-based guideline update: Plasmapheresis in neurologic disorders. Report of the Therapeutics and Technology Assessment Subcommittee of the American Academy of Neurology. *Neurology* 2011; 76: 294-300.
5. Elmouden H, Louhab N, Kissani N. Medullary involvement in neurosyphilis: A report of 12 cases and a review of the literature. *Spinal Cord Ser Cases* 2019; 5: 38.
6. Drew WL. Cytomegalovirus infection in patients with AIDS. *Clin Infect Dis* 1992; 14: 608-15.
7. McCutchan JA. Clinical impact of cytomegalovirus infections of the nervous system in patient with AIDS. *Clin Infect Dis* 1995; 21(2): S196-201.