

Invasive *salmonella* enteritidis infection complicated by colonic perforations and pancytopenia: A case report

Chee Yik Chang, MRCP, Yi Lung Gan, MRCP, Jia Yin Lio, MD, Anuradha P. Radhakrishnan, MRCP

Medical Department, Hospital Selayang, Batu Caves, Selangor, Malaysia

SUMMARY

Salmonellosis caused by bacterial genus *Salmonella* is associated with a high morbidity and mortality rate. *Salmonellae* can be divided into typhoidal serotypes (*S. enterica* ser. Typhi and *S. enterica* ser. Paratyphi A) and nontyphoidal *Salmonella* (NTS) serotypes. The two most common NTS serotypes isolated from human sources were *S. enterica* ser. Typhimurium and *S. enterica* ser. Enteritidis. NTS infection can present with diverse clinical manifestations, including gastroenteritis, bacteraemia, septic arthritis, osteomyelitis, and endovascular infection. Intestinal perforation is an extremely rare and potentially fatal complication of severe salmonella infection. Herein, we report a case of invasive *S. Enteritidis* infection complicated by colonic perforation and pancytopenia. Following a colonic resection, the patient received a prolonged course of antimicrobial therapy and eventually recovered.

INTRODUCTION

Salmonella is one of the most commonly isolated foodborne pathogens, with over 2500 *Salmonella* serotypes identified to date. Infections caused by invasive serotypes of *Salmonella* are frequently fatal, necessitating appropriate and effective antibiotic therapy. Nontyphoidal *Salmonella* (NTS) infection can cause a wide range of clinical presentations, including gastroenteritis, bacteraemia, septic arthritis, osteomyelitis, and endovascular infection.¹ *S. Enteritidis* is the second most encountered serovar causing invasive NTS infections after serovar Typhimurium, accounting for approximately one-third of all cases. Contaminated hen's eggs were the most important vehicle of the *S. Enteritidis* infection.² Intestinal perforation is one of the most serious complications of *Salmonella* infection, and it can occur in patients who are not immunocompromised. Surgery is usually indicated in most cases of typhoid intestinal perforation, along with antibiotics and supportive care.³

CASE REPORT

An 18-year-old girl with no prior medical illness presented to Selayang Hospital, Malaysia with a three-week history of fever, diarrhoea, and abdominal pain. It was associated with malaise, reduced appetite, and weight loss. She denied having a headache, neck stiffness, blurred vision, or fitting episode. Two other members of the household also experienced similar but milder symptoms after consuming food bought from the market.

She was pale and delirious when she arrived at the hospital. She had a high-grade fever of 38.7°C and was normotensive but tachycardic. Her lungs were clear on auscultation, but her abdomen was distended and tender, with guarding. A neurological examination of the upper and lower limbs did not reveal any focal neurological deficit. The initial full blood count showed pancytopenia with a haemoglobin of 6 g/dL, white blood cell counts of $3 \times 10^3/\mu\text{L}$, and platelet counts of $90 \times 10^3/\mu\text{L}$. Blood gas analysis revealed metabolic acidosis with raised serum lactate of 3.3 mmol/L. The screening tests for HIV and connective tissue disease came back negative. An abdominal radiograph revealed grossly dilated large and small bowels, and a chest radiograph revealed no air under the diaphragm. The abdominal computed tomography (CT) scan revealed gross pneumoperitoneum suggestive of bowel perforation with tension pneumoperitoneum, but the brain CT scan revealed no abnormalities (Fig. 1).

The patient was intubated for respiratory failure on the same day of hospital admission, and empirical antibiotics were administered, including 2 g of intravenous ceftriaxone once daily and 500 mg of metronidazole thrice daily. She then underwent an emergency exploratory laparotomy, which revealed multiple punctate perforations in the splenic flexures of the colon, descending colon, and upper sigmoid colon. A segmental colonic resection was performed, and a double barrel stoma was created. After surgery, she was admitted to the intensive care unit and started on total parenteral nutrition. Meropenem was substituted for ceftriaxone due to persistent fever and to cover for nosocomial infection.

Salmonella spp was isolated from the blood culture and was later identified as *S. Enteritidis* by serotyping. The isolate was found to be susceptible to ampicillin and ceftriaxone. Histopathological examination of the affected colonic tissue revealed the presence of inflammatory infiltrates composed of neutrophils, lymphocytes, plasma cells, and histiocytes but no granuloma. There was no evidence of tuberculosis, cytomegalovirus, fungal infection, or malignancy. Her illness was complicated by intraabdominal collections and catheter related bacteraemia caused by extended-spectrum β -lactamases (ESBL)-producing *Klebsiella pneumoniae*, for which she received intravenous meropenem. A tracheostomy was performed as a result of the prolonged ventilation, and she was extubated after three weeks. Intravenous meropenem was administered for two weeks, followed by a prolonged course of ampicillin-sulbactam for six weeks. The pancytopenia resolved after antimicrobial therapy, so a bone

This article was accepted: 09 February 2022

Corresponding Author: Chee Yik Chang

Email: ccyik28@gmail.com

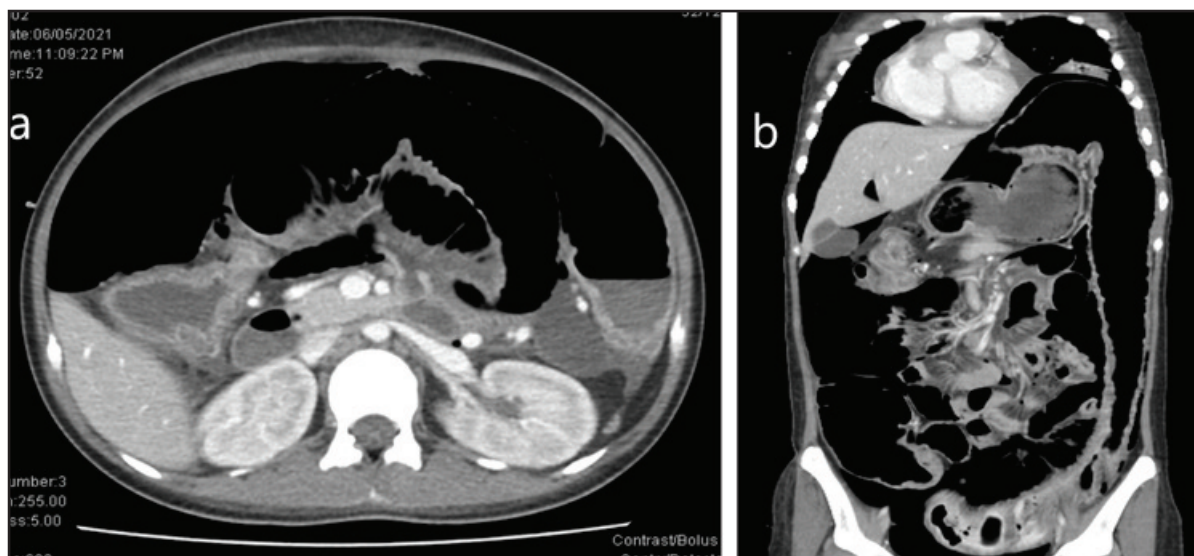


Fig. 1: Contrast-enhanced CT scan. (a) axial view and (b) coronal view of the abdomen revealing gross pneumoperitoneum suggestive of bowel perforation with tension pneumoperitoneum.

marrow examination was not required. A repeat CT scan of the abdomen revealed that the abdominal collections had resolved. She was discharged home and scheduled for stoma reversal at a later date.

DISCUSSION

Salmonella infection is still a major public health concern, especially in developing countries. Each year, it results in 93.8 million foodborne illnesses and 155,000 deaths. There are over 2600 different serovars of *Salmonella enterica*, which are divided into typhoidal and non-typhoidal *Salmonella*.^{1,2} *S. Typhimurium* and *Enteritidis* are the major serovars implicated in invasive non-typhoidal *Salmonella* disease in Africa, accounting for more than 90% of cases.⁴

Salmonella gastroenteritis is characterised by nausea, vomiting, abdominal pain, and diarrhoea, which usually appear 48 hours after ingestion of food contaminated with the bacteria. In immunocompetent patients, it usually manifests as a mild, self-limiting disease, and requires no antimicrobial therapy other than hydration. It can, however, be life-threatening, presenting with bacteraemia and fever, and if left untreated, it can result in death. Invasive disease is more likely to develop in patients who have HIV, malaria, malnutrition, sickle cell anaemia, or are elderly.³ Patients with invasive disease often have a fever and bacteraemia, and the clinical features can be non-specific, with different target organ involvement and complications such as pneumonia, endocarditis, mesenteric thickening and lymphadenopathy, hepatosplenomegaly, abscess formation, osteomyelitis, infective vascular aneurysm, pyelonephritis, and central nervous system manifestation such as meningitis.⁵

Although gastrointestinal tract infection is common with *Salmonella*, colonic perforation is rare and is one of the more serious complications.^{5,7} Typhoidal disease has been linked to the majority of cases of colonic perforation. However, there have been several cases of colonic perforation associated with

non-typhoidal *Salmonella* infection reported around the world.^{6,7} For example, Hélias et al.⁶ reported a case of spontaneous intestinal perforation due to *S. Enteritidis* in an otherwise healthy patient with no predisposing risk factors, which was very similar to our case. A study in the Netherlands confirmed that the use of H2 antagonists and proton pump inhibitors, as well as the consumption of raw eggs and products containing raw eggs, were linked to endemic *S. Enteritidis* infection.⁸ We hypothesised that the patient had consumed food containing raw eggs contaminated with *S. Enteritidis* that had been purchased at a market. Otherwise, our patient had no other risk factors, such as HIV infection, malnutrition, or use of H2 antagonists or proton pump inhibitors.

The pathogenesis of colonic perforation caused by *Salmonella* infection is poorly understood. In the case of *Salmonella* typhi-related colonic perforation, it was demonstrated that bacteria infiltrating Peyer's patches caused necrosis, which led to haemorrhage and perforation. Another postulation is that an exaggerated immune system causes an increase in inflammatory cytokine production, which causes clumping of macrophages and lymphocytes around vascular tissue, leading to bowel necrosis.⁹ On admission, our patient was diagnosed with pancytopenia, which was most likely caused by *Salmonella* infection. A case of severe pancytopenia in a patient with typhoid fever was previously reported, in which bone marrow examination revealed extensive haemophagocytosis, which contributed to pancytopenia.¹⁰ In our case, her pancytopenia improved after antibiotic treatment, so a bone marrow examination was not required.

Treatment should include a laparotomy to identify the perforation site and resection of the necrotic segment as soon as possible. Antimicrobials with broad spectrum coverage and anaerobic coverage should be started. In patients with severe sepsis, such as our patient, adequate hydration and resuscitation are critical for maintaining hemodynamic stability.

CONCLUSION

Although the incidence of *Salmonella* infection has decreased significantly in developed countries due to the availability of effective antibiotics, it remains endemic in developing countries. Severe complications from nontyphoid *S. Enteritidis*, such as colonic perforation, are extremely rare and have a high morbidity and mortality rate. Early surgical intervention, effective resuscitation in the pre-operative period, post-operative care, and the use of appropriate antibiotics are all required for the optimal management of intestinal perforation.

CONFLICT OF INTERESTS

The authors declare that they have no conflict of interest.

REFERENCES

1. Eng S, Pusparajah P, Ab Mutalib N, Ser H, Chan K, Lee L. *Salmonella*: A review on pathogenesis, epidemiology and antibiotic resistance. *Front Life Sci* 2015; 8(3): 284-93.
2. Gantois I, Ducatelle R, Pasmans F, Haesebrouck F, Gast R, Humphrey TJ, et al. Mechanisms of egg contamination by *Salmonella Enteritidis*. *FEMS Microbiol Rev* 2009; 33(4): 718-38.
3. Feasey NA, Dougan G, Kingsley RA, Heyderman RS, Gordon MA. Invasive non-typhoidal *Salmonella* disease: An emerging and neglected tropical disease in Africa. *Lancet* 2012; 379(9835): 2489-99.
4. Uche IV, MacLennan CA, Saul A. A systematic review of the incidence, risk factors and case fatality rates of invasive nontyphoidal *Salmonella* (iNTS) disease in Africa (1966 to 2014). *PLoS Negl Trop Dis* 2017; 11(1): e0005118.
5. Henedige T, Bindl DS, Bhasin A, Venkatesh SK. Spectrum of imaging findings in *Salmonella* infections. *AJR Am J Roentgenol* 2012; 198(6): W534-9.
6. Hélias M, Planchon J, Bousquet A, Dubost C. *Salmonella enterica* serovar *Enteritidis* peritonitis with spontaneous intestinal perforation in an immunocompetent patient. *BMJ Case Rep* 2019; 12(3): e228027.
7. van Vuuren TM, Wegdam JA, Wegdam-Blans M. Darmperforatie door *Salmonella Typhimurium* [Intestinal perforation caused by *Salmonella Typhimurium*]. *Ned Tijdschr Geneesk* 2013; 157(24): A6161.
8. Doorduyn Y, Van Den Brandhof WE, Van Duynhoven YT, Wannet WJ, Van Pelt W. Risk factors for *Salmonella Enteritidis* and *Typhimurium* (DT104 and non-DT104) infections in The Netherlands: Predominant roles for raw eggs in *Enteritidis* and sandboxes in *Typhimurium* infections. *Epidemiol Infect* 2006; 134(3): 617-26.
9. Nguyen QC, Everest P, Tran TK, House D, Murch S, Parry C, et al. A clinical, microbiological, and pathological study of intestinal perforation associated with typhoid fever. *Clin Infect Dis* 2004; 39(1): 61-7.
10. Sood R, Roy S, Kaushik P. Typhoid fever with severe pancytopenia. *Postgrad Med J* 1997; 73(855): 41-2.