

# Early-onset neonatal hypocalcaemia secondary to maternal vitamin D deficiency in an infant with DiGeorge syndrome: A first case report in Malaysia

Sithra Rengasamy, MMed<sup>1,2</sup>, Sheila Gopal Krisnan, MRCPCH<sup>2</sup>, Mohd Safwan Nordin, MBBS<sup>2</sup>, Siah Wooi Phaik, MBBS<sup>2</sup>, Wan Fadhilah Wan Ibrahim, MuDr<sup>2</sup>, Zurina Zainudin, MRCPCH<sup>1</sup>

<sup>1</sup>Department of Paediatrics, Faculty of Medicine and Health Sciences, Universiti Putra Malaysia, Serdang, Selangor, Malaysia

<sup>2</sup>Department of Paediatrics Hospital Seri Manjung, Manjung, Perak, Malaysia

## SUMMARY

DiGeorge syndrome is a genetic disorder that is related to a wide range of defects affecting various parts of the body. The clinical expression shows marked variability making the diagnosis often missed or underdiagnosed. Here, we describe a neonate who presented with loud inspiratory stridor secondary to hypocalcaemia at birth. Physical examination revealed no abnormality other than evidence of congenital cardiac defect. Laboratory evaluations confirmed the diagnosis of maternal vitamin D deficiency that led to symptomatic hypocalcaemia in the newborn infant. The presence of hypocalcaemia coupled with episodes of recurrent infections led to the clinical suspicion of DiGeorge, which was later confirmed by fluorescence in situ hybridisation test.

## INTRODUCTION

DiGeorge syndrome (DGS), also known as 22q11.2 deletion syndrome, affects approximately one in 4000–7000 children globally.<sup>1</sup> This disorder is characterised by embryological dysgenesis of the third to fourth pharyngeal pouches and fourth branchial arch, which is related to wide range of defects affecting various parts of the body.<sup>1,2</sup> Due to its incomplete penetrance, there is a marked variability in clinical expression of DGS. The classical features of this syndrome often include conotruncal cardiac anomalies, palatal cleft with specific facial appearance, hypocalcaemia, and thymic hypoplasia with secondary impaired T cell response, which leads to immunodeficiency.<sup>1,2</sup> Affected individuals may also have other associated problems such as kidney abnormalities, hearing loss, autoimmune disorders including rheumatoid arthritis or Grave's disease, and delayed psychomotor development with a tendency to develop seizures, learning disability as well as psychiatric illnesses.<sup>1,3,4</sup>

Transient neonatal hypocalcaemia is a well-recognised feature of DGS. It is typically associated with aplasia or hypoplasia of the parathyroid glands. However, neonatal hypocalcaemia secondary to maternal vitamin D deficiency in an individual with DGS has never been reported. This is believed to be the first case of early-onset symptomatic neonatal hypocalcaemia secondary to maternal vitamin D deficiency in a neonate who was later diagnosed with DGS in Malaysia.<sup>5,6</sup>

## CASE REPORT

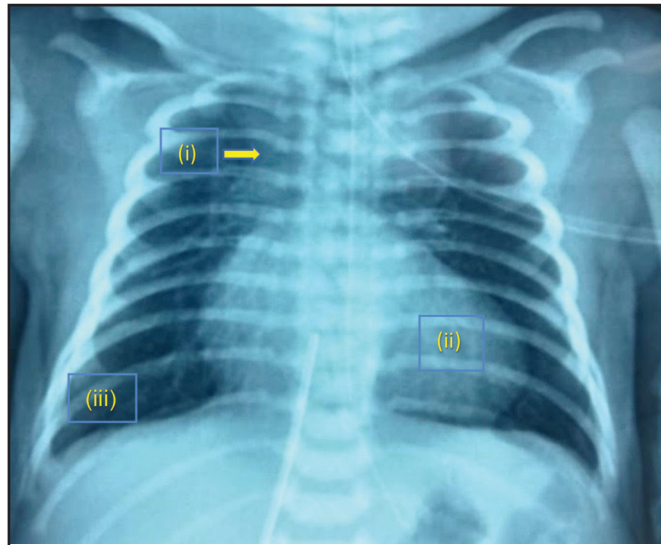
A female infant was admitted to the neonatal intensive care unit (NICU) for severe respiratory distress at birth. She was born at 38 weeks of gestation via spontaneous vertex delivery with a birth weight of 3680 g. The mother was a 35-year-old with no pregnancy-related complications. The baby cried immediately after delivery; however, the baby was noted to have loud inspiratory stridor immediately. Her respiratory rate was 65 breaths per minute associated with deep intercostal and subcostal recession. Pulse oximeter oxygen saturation was 85% on bag valve mask ventilation of 100% oxygen; hence, she was intubated, stabilised, and transferred to NICU. A direct laryngoscopy visualised no structural abnormalities that could explain the stridor. Further clinical assessment revealed no obvious dysmorphism, pulse rate was 120 beats/minute, blood pressure was 80/45 mmHg, and body temperature was 36.6°C. A grade three systolic murmur was heard on chest examination; other systemic review was unremarkable.

Despite optimum ventilatory support, the infant remained cyanosed and oxygen saturation ranged between 85% and 90%. Arterial blood gases showed pH 7.36, pCO<sub>2</sub> 39.2 mmHg, pO<sub>2</sub> 43 mmHg, and HCO<sub>3</sub> 21.5 mmol/L. Chest radiograph revealed a boot-shaped heart and a prominent thymic shadow (Figure 1). A bedside echocardiogram confirmed the diagnosis of Tetralogy of Fallot with the presence of major aorto-pulmonary collateral arteries (MAPCAs). Further evaluation disclosed a persistently low corrected serum calcium level (1.37 mmol/L) associated with a low serum 25-hydroxy D level for both the baby and the mother (29.76 nmol/L and 10.21 nmol/L, respectively) and normal serum parathyroid hormone level (20.8 ng/L), which suggest a diagnosis of vitamin D deficiency. The serum magnesium level was also low (0.67 mmol/L), and serum alkaline phosphatase as well as phosphate levels were normal (228 U/L and 1.95 mmol/L, respectively). She responded well to calcium and vitamin D supplements, evident by the gradual increase in her serum calcium level and magnesium levels after one week (2.02 mmol/L and 0.71 mmol/L), at one month (2.0 mmol/L and 0.78 mmol/L) and at two months (2.15 mmol/L and 0.89 mmol/L), respectively. Due to recurrent lung infections, she remained on respiratory support until day 77 of life. Apart from recurrent lung infections, she developed two episodes of septicaemia with no bacteria isolated from her blood cultures. Her infections were

This article was accepted: 14 February 2022

Corresponding Author: Sithra Rengasamy

Email: sdr818@gmail.com



**Fig. 1:** Chest radiograph at birth revealing (i) a boot-shaped heart with (ii) prominent thymic shadow, and (iii) clear lung fields.

presumptively treated for Methicillin Resistant Staphylococcus Aureus (MRSA) as she had nasal colonisation of MRSA. The constellation of cardiac anomalies, hypocalcaemia, and recurrent infections has led to the clinical suspicion of DGS, which was later corroborated by the presence of heterozygous deletion at chromosome 22q11.2 on fluorescence in situ hybridisation (FISH) test. Her immune functional status was evaluated, and the results were within normal parameters for her age.

**DISCUSSION**

Inspiratory stridor, which is found in this case, requires immediate evaluation to determine the underlying aetiology. A complete diagnostic workup is crucial especially in the presence of significant airway obstruction causing respiratory distress as seen in our case. Interestingly, the most important preliminary finding in our patient was hypocalcaemia. Inspiratory stridor presenting immediately after delivery is not only a rare presentation of neonatal hypocalcaemia but also potentially harmful. Acute laryngospasm caused by reflex closure of the larynx, resulted from hypocalcaemia in our case. Severe laryngospasm has the risk of causing significant hypoxia with resultant developmental delay, particularly in areas of neurocognitive development. Studies have shown that neonates with hypocalcaemia have a higher predictive index of developing intellectual disability.<sup>4</sup>

It is fair to conclude that hypocalcaemia in our case was due to insufficient levels of vitamin D. Although infrequently contributes to early-onset hypocalcaemia, maternal vitamin D deficiency is a well-recognised cause of neonatal hypovitaminosis D and neonatal hypocalcaemia.<sup>7</sup> Vitamin D deficiency during pregnancy results in poor transplacental transfer of vitamin D and calcium and thus reduced stores in the newborn.<sup>8</sup> Majority of these infants present with symptomatic hypocalcaemia with seizures, jitteriness, or less commonly stridor by the second week of life. Parathyroid hormone (PTH) levels are usually elevated in the presence of hypocalcaemia; however, it was not seen in this case. The

unexpected normal PTH levels may be due to the immature calcium-vitamin D-PTH axis, as well due to the presence of concomitant hypomagnesemia. Hypomagnesemia inhibits PTH action and concurrently reduces sensitivity at target organs. The possibility of neonatal hypoparathyroidism in this case could not be ruled out.

Hypocalcaemia secondary to hypoparathyroidism in individuals with DGS was first described by DiGeorge.<sup>9</sup> Hypoparathyroidism in this population is often mild manifesting as a phenomenon of decreased parathyroid reserve. The affected individual may be normo-calcaemic most of the time but predisposed to hypocalcaemia during periods of stress or illness, during which they may not be able to mount elevated PTH level and therefore unable to fully correct hypocalcaemia. The key point here is to regularly monitor the serum calcium as well as the PTH level. Hypovitaminosis D in patients with DGS is not unexpected. The state of hypoparathyroidism impairs the conversion of renal 25-hydroxyvitamin D (25[OH]D) to active form 1,25-dihydroxyvitamin D.<sup>8</sup> Unlike as seen in our case, vitamin D deficiency caused by hypoparathyroidism manifests later in life. The long-term effect of vitamin D deficiency caused by hypoparathyroidism can increase the risk of mental health disorders such as schizophrenia and depression.<sup>10</sup>

Our patient showed a good response to vitamin D and calcium supplements and was able to maintain normal serum calcium levels after discontinuation of supplements. Homeostasis of circulating calcium levels in individuals with DGS can be easily disrupted due to multiple reasons. The formation of thymus and parathyroid glands from the third and fourth pharyngeal pouch indicates a strong relation between the two. Although the presence of thymic shadow coupled with normal PTH levels may indicate the presence of the parathyroid gland, the function may be still impaired due to low reserves.<sup>1</sup> This inadvertently predisposes individuals with DGS to recurrent transient hypocalcaemia due to failure in maintaining calcium homeostasis. Ideally, vitamin D levels, serum PTH levels, and magnesium levels should be re-

evaluated again at a three-to-four-month interval until the age of one year and then annually to objectively ascertain the treatment outcome of this neonate.<sup>4</sup>

### CONCLUSION

Hypocalcaemia is an unusual but potentially life-threatening cause of inspiratory stridor at birth. This case highlights the importance of an immediate and complete evaluation of the underlying aetiology. Neonatal vitamin D deficiency secondary to maternal hypovitaminosis D is prevalent and is the main aetiological factor for symptomatic neonatal hypocalcaemia. The presence of associated cardiac defect and recurrent episodes of infection have also led to the diagnosis of DGS.

### ACKNOWLEDGEMENT

The authors would like to thank all the doctors and staff of NICU Hospital Manjung for their kind assistance in the management of our patient. The authors would also like to thank the Director-General of Health for his permission to publish this report.

### REFERENCES

1. Shprintzen RJ. Velo-cardio-facial syndrome: 30 years of study. *Dev Disabil Res Rev* 2008; 14(1): 3-10.
2. McDonald-McGinn DM, Sullivan KE. Chromosome 22q11.2 deletion syndrome (DiGeorge syndrome/velocardiofacial syndrome). *Medicine* 2011; 90(1): 1-18.
3. Digilio M, Marino B, Capolino R, Dallapiccola B. Clinical manifestations of deletion 22q11.2 syndrome (DiGeorge/Velo-Cardio-Facial syndrome). *Images Paediatr Cardiol* 2005; 7(2): 23-34.
4. Cheung EN, George SR, Andrade DM, Chow EW, Silversides CK, Bassett AS. Neonatal hypocalcemia, neonatal seizures, and intellectual disability in 22q11.2 deletion syndrome. *Genet Med* 2014; 16(1): 40-4.
5. Naeem KB, Ahmed M. Stridor in a neonate-is it just a floppy larynx? *J Pak Med Assoc* 2007; 57(6): 322-3.
6. Begum N, Mohsin F, Sufian A, Islam N, Nahar J, Mollah MA. DiGeorge syndrome presenting with seizure in neonatal period: A case report. *BIRDEM Med J* 2021; 11(2): 128-32.
7. Do HJ, Park JS, Seo J-H, Lee ES, Park CH, Woo HO, Youn HS. Neonatal late-onset hypocalcaemia: Is there any relationship with maternal hypovitaminosis D? *Pediatr Gastroenterol Hepatol Nutr* 2014; 17(1): 47-51.
8. Mulligan ML, Felton SK, Rlek AE, Bernal-Mizrachi C. Implications of vitamin D deficiency in pregnancy and lactation. *Am J Obstet Gynecol* 2010; 202(5): 429.
9. DiGeorge AM. Discussion on a new concept of the cellular basis of immunity. *J Pediatr* 1965; 67: 907-8.
10. Moy FM, Hoe VC, Hair NN, Vethakkan SR, Bulgiba A. Vitamin D deficiency and depression among women from an urban community in a tropical country. *Public Health Nutr* 2017; 20(10): 1844-50.