

Jejunal gastrointestinal stromal tumour masquerading as an ovarian cancer: A case report

Sohail Mushtaq, FRCS^{1,2}, Richelle Chua Huey Bing, MD^{1,2}, Sim Sze Kiat, MS¹, Nik Azim Nik Abdullah, MS²

¹Faculty of Medicine and Health Sciences, Universiti Malaysia Sarawak, Kota Samarahan, ²Department of surgery, Hospital Umum Sarawak, Jalan Hospital Kuching, Sarawak

SUMMARY

A 60-year-old lady presented with lower abdominal discomfort and a huge palpable intra-abdominal mass for 4 months, with significant weight loss over half a year. Transvaginal ultrasonography and computed tomography (CT) abdomen showed a large right solid cystic mass likely ovarian in origin. The CA-125 was raised. With the provisional diagnosis of ovarian cancer patient underwent laparotomy at Hospital Umum Sarawak, Malaysia. However intraoperative findings showed that uterus and both ovaries were normal. The tumour was arising from the jejunum and adherent to the dome of the urinary bladder and right broad ligament. The tumour was resected and final diagnosis was jejunal gastrointestinal stromal tumour (GIST). We described this case which was misinterpreted as an ovarian cancer.

INTRODUCTION

Gastrointestinal stromal tumour (GIST) is the most common primary mesenchymal tumours of gastrointestinal tract and the cell of origin is the interstitial cell of Cajal.¹ About 75% of GISTs have mutations in tyrosine kinase, and 10% have mutations in PDGFR α . GIST is typically a disease of adults in 5th or 6th decade of life. It is relatively more common in males. GIST can arise anywhere from oesophagus to rectum but common sites are stomach (50-60%) jejunum, ileum (25-35%) and duodenum (10%).¹

Clinical features of small bowel GISTs include, gastrointestinal bleeding, abdominal pain, abdominal mass or intestinal obstruction.^{1,2} Sometimes they are discovered incidentally on endoscopy or imaging performed for some other reason. Surgical resection is the mainstay of treatment. Asymptomatic small bowel GISTs smaller than 2 cm may be observed and treated conservatively.

CASE REPORT

A 60-years-old lady presented to the Sarawak General Hospital with lower abdominal discomfort and palpable abdominal mass for 4 months, associated with anorexia and significant loss of weight. Systemic review was unrevealing. She had past history of hypertension, dyslipidaemia and gout. There was no family history of malignancy or anaemic symptoms. Abdominal examination showed large, intra-abdominal mass at right lower quadrant. The mass was non-tender, firm in consistency and mobile side to side. Its upper margin was reaching up to umbilicus but lower margin was

not reachable. Rest of systemic examination was unrevealing.

Laboratory tests revealed a low haemoglobin level (8.1g/dl), otherwise no abnormality was seen in the total white cells, platelets count, liver and renal functions, and coagulation profile. Tumour markers showed elevated CA -125 =64.2U/ML (normal <35U/ML) but normal CEA

Abdominal and transvaginal ultrasonography showed a large, solid, irregular right adnexal mass. A Computerised tomography scan (CT) showed a large well-encapsulated solid-cystic pelvic mass measuring 11.5 x 16.7 x 17.4 cm arising from the right adnexa with no clear plane with dome of urinary bladder and right round ligaments suggestive of a malignant ovarian tumour (Figure 1). There was no evidence of liver or peritoneal metastasis.

With the provisional diagnosis of ovarian cancer, the patient underwent laparotomy under gynaecological team. Intraoperatively, the tumour was found to be arising from the antimesenteric border of jejunum 20 cm from the duodenojejunal junction measuring 18 x 16 cm. The tumour was adherent to the dome of urinary bladder and right broad ligament of uterus. There were no enlarged mesenteric lymph nodes or peritoneal nodules. Uterus and both ovaries were normal. Patient was then referred to on call general surgical team. With an intraoperative diagnosis of jejunal GIST, the tumour was resected with a gross clear margin. Serosal defect at the dome of urinary bladder repaired with vicryl 3/0 suture. About 15 cm segment of jejunum was resected en-block with tumour and anastomosis performed (Figure 2). The tumour was very vascular and intraoperative blood loss was about 500 ml.

Post operatively patient recovery was uneventful. She was started on clear fluids on day1, liquid diet on post-operative day 2 and progressed to soft diet on day3. She was discharged on post-operative day 6.

Histopathological examination revealed tumour with spindle cell proliferation arranged in vague fascicular, storiform and haphazard patterns with extensive areas of necrosis. The tumour cells displayed mild nuclear pleomorphism. Mitotic count was about 30/50hpf. No marked nuclear atypia or abnormal mitotic figures noted. The tumour involved the submucosa, muscularis propria and serosa of the small intestine. All resected margins were free of tumour. In

This article was accepted: 07 December 2021

Corresponding Author: Sohail Mushtaq

Email: msohail@unimas.my

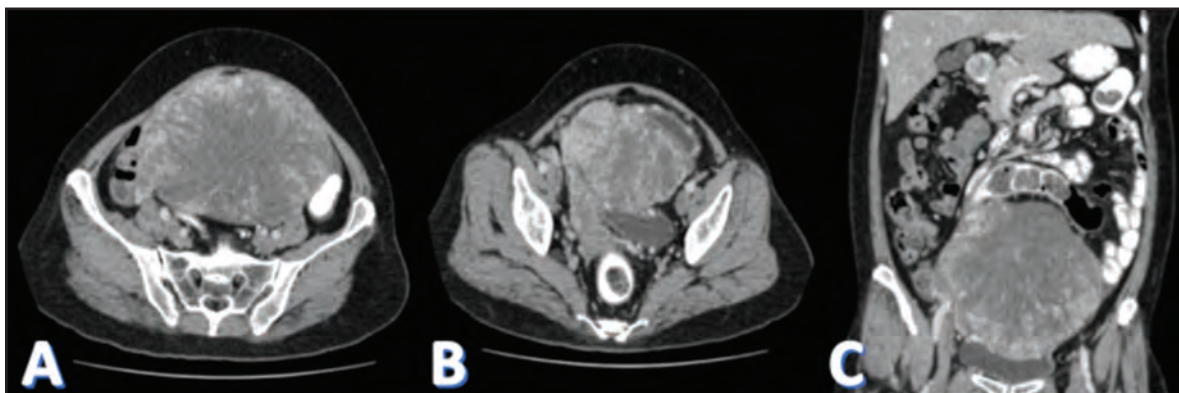


Fig. 1: CT scan of abdomen and pelvis (A, B – transverse sections; C – coronal section) showed a solid cystic mass with no clear plane with right broad ligament and dome of urinary bladder.

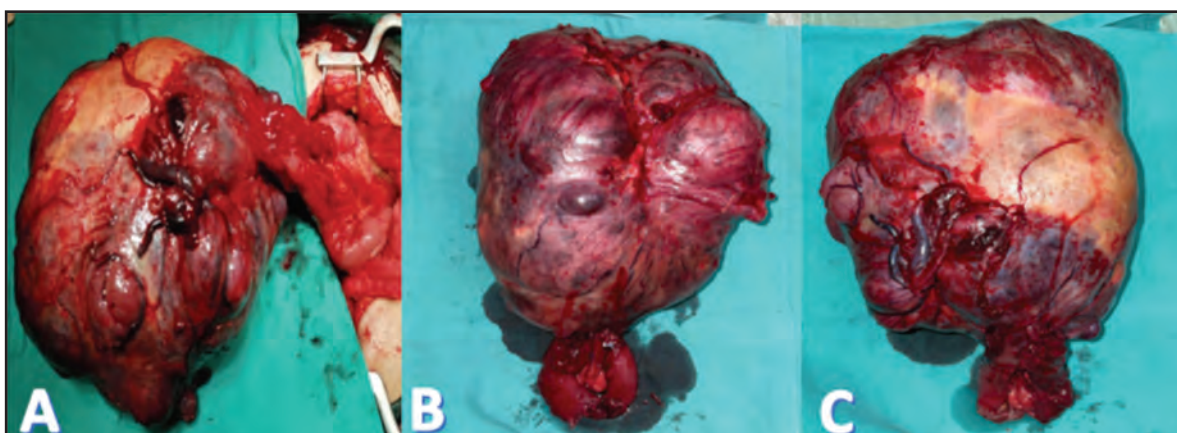


Fig. 2: Intraoperative photos. Large vascular tumour arising from antimesenteric border of jejunum (A). Resected specimen with segment of jejunum (B and C).

addition, immunohistochemical staining showed the tumour cells expressed diffuse DOG-1 and CD117 positivity whereas negative toward SMA, CD34, HMB45. The Ki67 proliferative index was about 10%. The final diagnosis was jejunal GIST with risk of progression.

During follow up patient was doing well. Abdominal wound has healed with no complications. She has been referred to our oncology department for adjuvant targeted therapy.

DISCUSSION

GISTs account for about 0.2% of gastrointestinal tumours.¹ Small bowel is the second common site of gastrointestinal stromal tumours after stomach. Jejunal GISTs are extremely rare.^{1,2} Common symptoms of GISTs include occult or overt gastrointestinal bleeding, abdominal mass, intestinal obstruction or incidental finding on endoscopy or imaging. GISTs may be endophytic presenting as submucosal lesions. Mucosa overlying the GIST may ulcerate producing an umbilicated appearance on endoscopy. GISTs may be exophytic where the main bulk of tumour is on the external surface of bowel or stomach. In our case the GIST was exophytic type.

Depending on the clinical suspicion upper GI endoscopy and CT scan are the investigations of choice. In our case, CT scan did not show any relation of the mass with the bowel and patient had no history suggestive of GI bleeding or obstruction.

Histopathology and immunohistochemistry are diagnostic tests for GIST. Jejunal GIST show variable morphology.¹ Tumours may be composed of spindle cells, epithelioid cells, or mixed spindle and epithelioid cells. Immunohistochemical assays are positive for CD117 and DOG-1.^{1,2}

Behaviour of GIST may vary from benign to malignant depending on the tumour site, size and mitotic rate.^{2,3} Size greater than 5 cm, mitoses larger than 5/50 high-powered fields, and non-gastric site indicate poor prognosis.

GISTs may invade local organs, spread to peritoneum or distant organs like liver, lungs, and bones.³ Spread to lymph nodes is very rare.

Surgery with clear margin is the mainstay of curative treatment.^{3,4} During surgery tumour should be handled gently to avoid capsule rupture which can result in spread of tumour in the peritoneal cavity and recurrence later. In our

case the jejunal GIST was adherent to serosa of the dome of urinary bladder. The tumour was resected completely including the serosa and superficial muscle layer of urinary bladder.

Targeted therapy with tyrosine kinase inhibitors like imatinib has important role in the management of GISTs. Neoadjuvant imatinib may downstage large tumour thus allowing organ preserving resections.⁴ Adjuvant imatinib may prevent recurrence in large (>1cm) tumours.⁴ Tyrosine kinase inhibitors are recommended even in metastatic GIST to control the growth of tumour.^{4,5}

CONCLUSIONS

Small bowel GISTs are rare. High index of suspicion is required in any patient presenting with abdominal or pelvic mass. Although modern imaging like CT scan are very helpful in reaching a definite diagnosis in majority of cases, however in some cases the final diagnosis is only revealed at operation. Surgery is the mainstay of treatment. Adjuvant treatment with tyrosine kinase inhibitors is recommended especially in large tumours to prevent recurrence.

ACKNOWLEDGEMENT

We are grateful to Universiti Malaysia Sarawak (UNIMAS) and Hospital Umum Sarawak for continuous support in research and publication.

REFERENCES

1. Sankey RE, Maatouk M, Mahmood A, Raja M. Case Report: Jejunal gastrointestinal stromal tumour, a rare tumour, with a challenging diagnosis and a successful treatment. *J Surg Case Rep* 2015; 2015(5): rjv050.
2. Dualim DM, Loo GH, Rajan R, Nik Mahmood NRK. Jejunal GIST: Hunting down an unusual cause of gastrointestinal bleed using double balloon enteroscopy. A case report. *Int J Surg Case Rep* 2019; 60: 303-6.
3. Yoshioka S, Tazawa H, Saito A, Komo T, Sada H, Hadano N, et al. Laparoscopic resection for a large gastrointestinal stromal tumor (GIST) with diaphragm invasion following preoperative imatinib treatment: A case report. *Int J Surg Case Rep* 2021; 81: 105727.
4. Qi J, Liu HL, Ren F, Liu S, Shi W, Liu WH, et al. Preoperative adjuvant therapy for locally advanced and recurrent/metastatic gastrointestinal stromal tumors: a retrospective study. *World J Surg Oncol* 2020; 18(1): 70.
5. Makkapati B, Nanda AK. Small bowel gastrointestinal stromal tumor presenting with involvement of the adjacent small bowel and hemoperitoneum case report. *Ann Med Surg (Lond)* 2020; 59: 17-20.