

Peptide receptor radionuclide therapy induced carcinoid crisis: A case report

Siow Ping Lee, MRCP¹, Azraai Bahari Nasruddin, MRCP¹, Subashini Rajoo, MRCP²

¹Endocrine Unit, Department of Medicine, Hospital Putrajaya, Wilayah Persekutuan Putrajaya, Malaysia, ²Endocrine Unit, Department of Medicine, Hospital Kuala Lumpur, Wilayah Persekutuan Kuala Lumpur, Malaysia

SUMMARY

Peptide receptor radionuclide therapy (PRRT) is a therapeutic option in inoperable or metastatic neuroendocrine tumours (NETs). PRRT proved to be promising in prolonging survival and delaying disease progression in patients with advanced bronchopulmonary carcinoid. However, it may lead to worsening of carcinoid symptoms or even precipitate carcinoid crises. The incidence of PRRT induced carcinoid crisis would be between 1–10%. This usually takes place during the first PRRT cycle, either during the tracer infusion or 12–48 hours' post-administration. We report a 62-year-old man with underlying metastatic lung carcinoid tumour who developed carcinoid crisis at 10 hours after receiving PRRT. The carcinoid crisis was successfully treated with intravenous octreotide infusion, corticosteroid, a selective 5-HT₃ receptor antagonist, parenteral ranitidine and chlorpheniramine for H₁ and H₂ antagonism respectively.

INTRODUCTION

Carcinoid tumours are neuroendocrine tumours (NETs) that are relatively slow-growing, but sometimes exhibit profuse metastatic behaviour, most often to the liver and lungs. Various vasoactive peptides such as bradykinin, tachykinin, histamine and serotonin secreted from these tumours are rapidly metabolized by the liver via the portal circulation. In cases of hepatic metastases where peptides escape hepatic metabolism or are directly released into the systemic circulation, patients present with carcinoid syndrome.¹ Carcinoid syndrome is the collection of symptoms and signs including diarrhoea, flushing, tachycardia, bronchoconstriction, and right-sided heart failure.¹

Carcinoid crisis is a severe complication of carcinoid syndrome in which a massive release of biologically active substances takes place. It is a rare, life-threatening condition with hemodynamic instability i.e. tachycardia, arrhythmias, metabolic acidosis, and/or mental status disorders, along with high mortality rate.² Carcinoid crisis is usually precipitated by stress, invasive procedures, induction of anesthesia, tracheal intubation, tumour manipulation, hypercapnia, hypothermia, hypotension, hypertension, initiation of chemotherapy, or drugs that cause a release of histamine including peptide receptor radionuclide therapy (PRRT).^{3,4} We report a patient with metastatic lung carcinoid who developed carcinoid crisis after receiving PRRT and he was successfully treated with intravenous octreotide infusion.

CASE REPORT

A 62-year-old man presented at the Hospital Putrajaya, Wilayah Persekutuan Putrajaya, Malaysia with 2 months' history of flushing and intense diarrhoea in June, 2018. He was not hypertensive and he had no history of headache, palpitation or sweating. Measurement of 24 hours urinary 5-hydroxyindoleacetic acid (5-HIAA) showed high concentration of 3677.79 mg/day (normal range: 2–8 mg/day). The imaging revealed a heterogenous enhancing irregular lung mass at left lower lobe measuring 3.7 x 3.1 x 3.6 cm (Figure 1A); multiple liver metastasis with the largest lesion at segment VII measuring 3.9 x 5.6 cm (Figure 2A); and multiple lytic and sclerotic bone lesions. Gallium (Ga)-68 DOTATATE scan showed evidence of somatostatin receptor avid disease in the lung mass, multiple liver lesions and bones. The lung mass at left lower lobe demonstrated standardized uptake value maximum (SUV max) of 11.9 (Figure 1B). On the other hand, the largest liver lesion demonstrated SUV max of 11.1 (Figure 2C). A tru-cut biopsy of the lung mass revealed no malignant cells. In view of high clinical suspicious of malignancy, an ultrasound guided liver biopsy was performed and the histopathological examination (HPE) was consistent with well-differentiated NET. His chromogranin A (Cg A) level was elevated at 59916 ng/ml (normal range: ≤ 225 ng/mL). He was then started on monthly intramuscular injection of octreotide 30 mg, a long acting-release (LAR) somatostatin analogue (SSA) and he eventually underwent left lung lobectomy in October, 2018 four months after the presentation. The HPE result showed carcinoid tumour grade 1 with clear margin and 2 lymph nodes involvement.

He developed coronary vasospasm with octreotide LAR at 4 months post-operatively and the treatment was switched to monthly subcutaneous injection of lanreotide 120 mg, another long acting SSA. A repeated Ga-68 DOTATATE scan at 6 months' post-surgery showed resolution of the lung disease (Figure 1C); but demonstrated evidence of somatostatin receptor avid disease progression in the liver and bones. The segment VII lesion had increased to 4.2 x 6.2 cm (Figure 2B). At the same time, patient had multiple episodes of carcinoid crisis with flushing, worsening diarrhoea and hypotension requiring intravenous (IV) infusion of octreotide and shorter interval of long acting SSA injection (2 weekly intervals). A surveillance Ga-DOTATATE PET/CT scan performed at 15 months after the surgery showed extensive disease in liver and bones; indicating progression of the disease. Hence, a PRRT was planned to halt the progression of the disease and for symptoms control. We

This article was accepted: 14 December 2021

Corresponding Author: Siow Ping Lee

Email: patricia82@hotmail.my

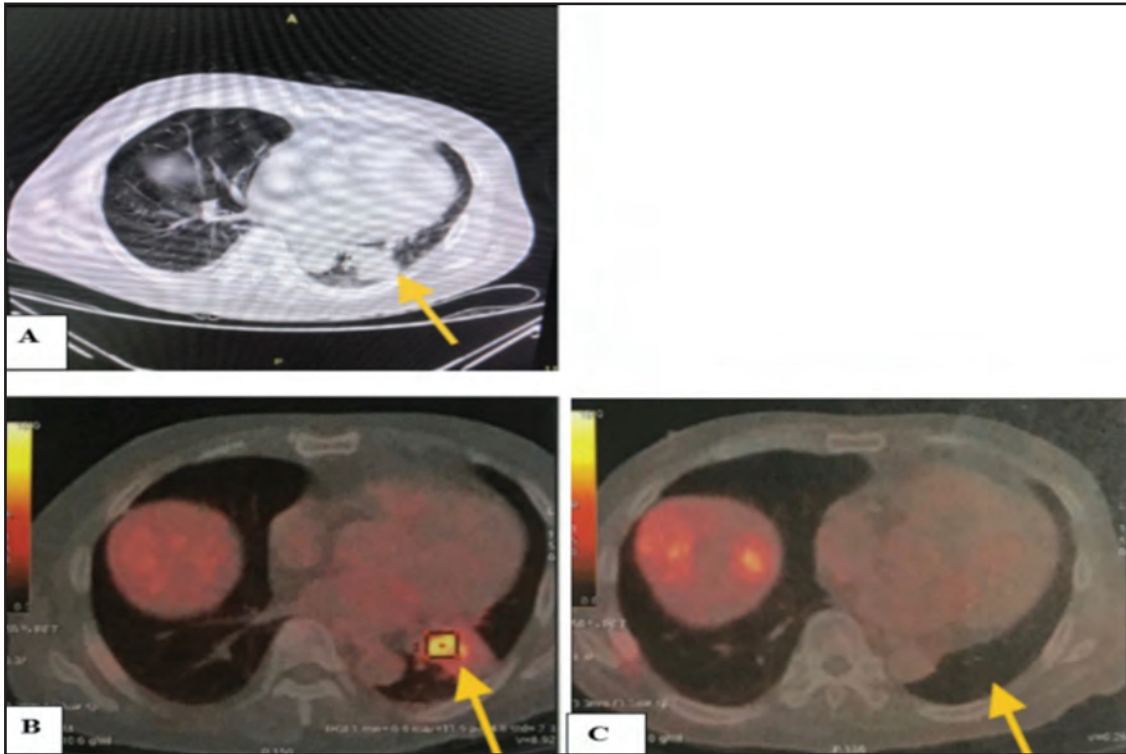


Fig. 1: Ga-68 DOATATE PET/CT scan showing (A) irregular left lower lobe lung mass before lobectomy (B) with the SUV max of 11.9 (C) has resolved after the surgery.

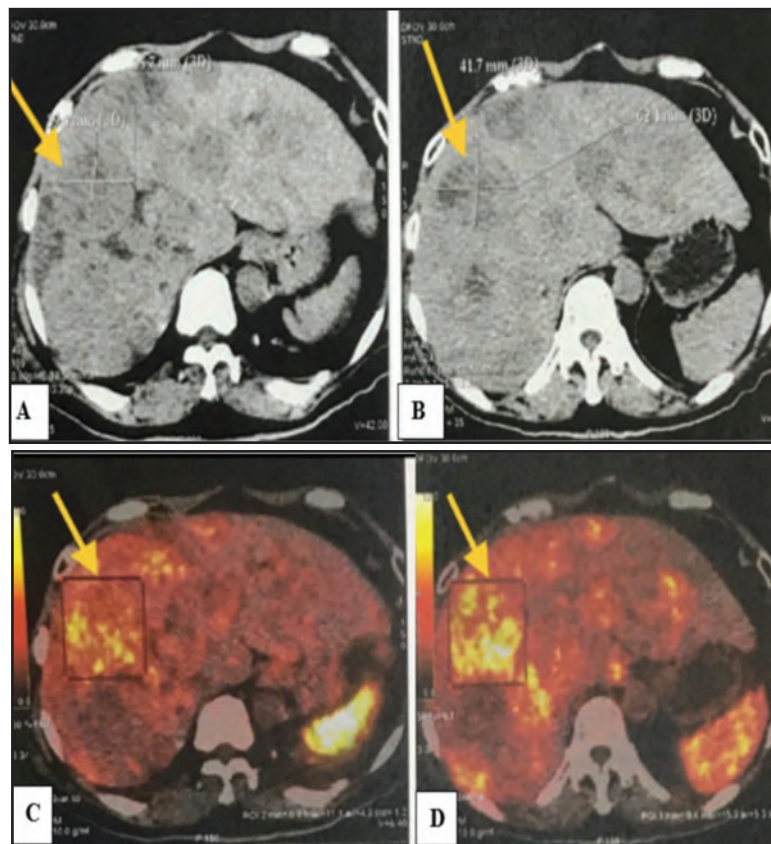


Fig. 2: Ga-68 DOTATATE PET/CT scan showing heterogenous hypodense lesions throughout both enlarged and lobulated liver lobes with the largest lesion measuring 3.9 x 5.6 cm (A) before the surgery and it has increased in size measuring 4.2 x 6.2 cm (B) at 6 months post-surgery. Ga-68 DOTATATE PET/CT scan showing the tracer uptake by the largest lesion at segment VII with the SUV max of 11.1 (C) before the surgery and the intensity has increased with the SUV max of 15.3 (D) at 6 months' post-surgery. The liver lesions also have increased in number post-surgery.

stopped the long acting SSA a month before ¹⁷⁷Lu-labelled PRRT to prevent competitive binding of ¹⁷⁷Lu-octreotate to the somatostatin receptors. The patient however, refused multiple daily injection of short acting octreotide at that time.

The patient received his first cycle of 200mCi of ¹⁷⁷Lu-labelled PRRT. Pre-medications such as IV granisetron (selective 5-HT₃ receptor antagonist) 2 mg, IV dexamethasone 4 mg and proton pump inhibitor were given. He had flushing and diarrhoea at 7 hours post-PRRT, hence, IV octreotide 50 mcg/hour was commenced. Unfortunately, the patient developed carcinoid crisis at 10 hours post PRRT administration. He developed severe hypotension with the blood pressure (BP) of 70–80/40–60 mmHg and tachycardia of 120–146 beats per minute (bpm). He also had multiple episodes of intense diarrhoea and flushing extending from head down to his abdomen. He was immediately resuscitated with crystalloid. The IV octreotide was increased from 50 mcg/hour to 100 mcg/hour. At the same time, subcutaneous lanreotide 120 mg was administered at 12 hours of PRRT. Regular parenteral ranitidine (50 mg IV) and chlorpheniramine (10 mg IV) were given on top of hydrocortisone (50 mg IV). His BP eventually increased to 110–120/60–70mmHg and his heart rate reduced to 80–90 bpm. The IV octreotide was slowly tapered down by 25 mcg each hour and then stopped 24 hours after PRRT. He was discharged well with oral prednisolone 30 mg daily and oral chlorpheniramine 4 mg 3 times per day for a total duration of 3 days. He was also given symptomatic treatment for his diarrhea with oral granisetron 1 mg when necessary.

DISCUSSION

We describe here a case of carcinoid crisis following PRRT. Although infrequent, carcinoid crisis can occur during or even a few days after the administration of PRRT. The incidence of PRRT induced carcinoid crisis is between 1–10%.² To our knowledge, the first case of PRRT induced carcinoid crisis was reported by Davi et al.⁴ in a patient with metastatic bronchial NET (atypical carcinoid). The carcinoid crisis usually happens during the first PRRT cycle, either during the infusion or 12–48 hours' post-administration.³

Several mechanisms have been postulated for carcinoid crisis after PRRT. Acute tumour lysis mediated by radiation cellular damage, resulting in sudden release of supra-physiological amount of hormonally active substances, leads to profound carcinoid symptoms.^{3,4} Discontinuation of somatostatin analogue (SSA) prior to therapy may also contribute to the rebound increase in bioactive peptides. Other identified mechanism also includes emotional stress response to hospitalization and/or therapy. Lastly, administration of amino acids such as lysine and/or arginine as a renal protective measure may play a role in the pathophysiology of PRRT induced carcinoid crisis.³ These amino acids might be used as substrates for the synthesis of vasoactive hormones by the carcinoid cells.³ However, exact mechanism is yet to be elucidated, as there are only few reported cases.

De Keizer et al.³ reported that all 6 patients suffering from carcinoid symptoms following PRRT had extensive tumour

burden and liver metastases, and 3 had skeletal metastasis too. All of them suffered from severe carcinoid symptoms such as intense diarrhoea or flushing even prior to PRRT. In two of the patients, hormonal symptoms were so severe that discontinuation of SSA before PRRT was impossible. In all 6 patients, the hormonal crisis occurred during the first PRRT cycle; 3 of them during or directly after ¹⁷⁷Lu-octreotate infusion, and in the other 3 crisis, 48 hours after PRRT. Cg A levels were elevated in all the patients and 5-HIAA elevation was reported in the 3 carcinoid patients.

Our patient was at high risk of developing carcinoid crisis. He had extensive tumour burden with liver metastasis as well as high levels of both Cg A and 5-HIAA. In addition, our patient has had multiple episodes of life-threatening carcinoid crisis even prior to commencement of PRRT. His post PRRT carcinoid crisis occurred 10 hours after PRRT which is probably due to emotional stress in combination to amino acid infusion. It is unlikely that this crisis was induced by tumour lysis secondary to beta irradiation as it is observed to occur relatively late, more than 24 hours post therapy.³

Treatment of a carcinoid crisis aims at preventing the release of the mediators from tumour tissue and/or blocking their effects on target organs. Gonzalo et al.⁵ had proposed a protocol for carcinoid crisis prevention and management post PRRT. Identification of high-risk patients is the important first step.⁵ The high-risk cases include those with previous history of carcinoid crisis, those with carcinoid symptom flare after cessation of long-acting SSA 4–6 weeks before PRRT requiring short acting SSA to control symptoms, or any patient with high tumour burden especially within the liver. Our patient had all the mentioned high-risk factors.

Correction of electrolyte disturbance, dehydration and hypoproteinemia before PRRT is also a crucial step.⁵ PRRT pre-medications typically should include corticosteroid, a selective 5-HT₃ receptor antagonist, parenteral ranitidine and chlorpheniramine for H₁ and H₂ antagonism, respectively.⁵ In case of high tumour burden and therefore risk of tumour lysis, allopurinol can be included in the premedication protocol chart if renal function is satisfactory⁵, but it was not given in this case.

Though long acting SSA is avoided 4 weeks prior to PRRT, to overcome competitive somatostatin receptor binding, administration of high boluses (250–500 mcg) or infusion (50 mcg/hour) of short acting octreotide is advisable. In the event of carcinoid crisis developing during or immediately after PRRT infusion, IV bolus as high as 500–1000 mcg octreotide can be administered, with treatment repetition at 5-minute intervals until control of symptoms is achieved. Alternatively, following an IV bolus dose, continuous infusion of octreotide at a dose of 50–100 mcg/hour may be started.⁵ Long-acting SSA should be then resumed 24–48 hours post-PRRT, followed by tapering off the short-acting octreotide infusion. There were some limitations pertaining to the management of this patient. The short acting octreotide infusion was commenced only after he developed carcinoid symptoms. It should be given earlier when the PRRT started, knowing that he is at very high risk of developing carcinoid crisis.

CONCLUSIONS

Although well tolerated, ¹⁷⁷Lu-labelled PRRT may trigger carcinoid crisis, and clinicians need to be aware of this fact. In patients who develop a carcinoid crisis with their first PRRT cycle, additional precautions need to be taken before the administration of further cycles, including continuation of SSA with the doses and protocol mentioned above, corticosteroids, prolonged observation in hospital after therapy including planned intensive care monitoring in selected cases.

REFERENCES

1. Grahame-Smith DG. The carcinoid syndrome. *Am J Cardiol* 1968; 21: 376-87.
2. Del Olmo-Garcia MI, Muros MA, Lopez-de-la-Torre M, Agudelo M, Bello P, Soriano JM, et.al. Prevention and management of hormonal crisis during theragnosis with LU-DOTA-TATE in neuroendocrine tumours. A systemic review and approach proposal. *J Clin Med* 2020; 9(7): 2203.
3. de Keizer B, van Aken MO, Feelders RA, de Herder WW, Kam BL, van Essen M, et al. Hormonal crises following receptor radionuclide therapy with the radiolabeled somatostatin analogue [¹⁷⁷Lu-DOTA0, Tyr3] octreotate. *Eur J Nucl Med Mol Imaging* 2008; 35:749-55.
4. Davi MV, Bodei L, Francia G, Bartolomei M, Oliani C, Scilanga L, et al. Carcinoid crisis induced by receptor radionuclide therapy with ⁹⁰y-dotatoc in a case of liver metastases from bronchial neuroendocrine tumour (atypical carcinoid). *J Endocrinol Invest.* 2006; 29:563-7.
5. Tapia Rico G, Li M, Pavlakis N, Cehic G, Price TJ. Prevention and management of carcinoid crises in patients with high-risk neuroendocrine tumours undergoing peptide receptor radionuclide therapy (PRRT): literature review and case series from two Australian tertiary medical institutions. *Cancer Treat Rev.* 2018; 66:1-6.