

# Sudden sensorineural hearing loss in COVID-19: A case series from the Wrightington, Wigan and Leigh Teaching Hospitals, United Kingdom

Saumil Mehul Shah, MBBS<sup>1,3</sup>, John Rocke, MBChB<sup>2,3</sup>, Kathryn France, FRCS<sup>3</sup>, Moustafa Izzat, FRCS<sup>3,4</sup>

<sup>1</sup>Hull York Medical School, United Kingdom, <sup>2</sup>University of Sheffield, United Kingdom, <sup>3</sup>Wrightington, Wigan and Leigh NHS Trust, <sup>4</sup>Royal College of Surgeons, Edinburgh, Scotland

## ABSTRACT

**Sudden sensory neural hearing loss (SSNHL) needs to be identified and managed correctly in a secondary or tertiary centre. Whilst 45% of presentations are said to be idiopathic in nature, several viruses have been linked to its aetiology. It was noted, anecdotally, that more patients were presenting with SSNHL during the COVID-19 pandemic to our ENT service at Wrightington Wigan and Leigh teaching hospitals, UK (WWL). We identified 4 COVID-19 positive patients who presented to our ENT service with SSNHL. Despite normal findings on external ear examination, three of the patients showed bilateral hearing loss, whilst one had a predominantly unilateral loss. Given our findings we would like to present these four cases, as well as providing hypotheses on possible aetiology of this association. This may aid in research, diagnosis and treatment of future COVID positive patients with SSNHL.**

## INTRODUCTION

Sudden sensory neural hearing loss (SSNHL) has traditionally been defined as a 30 dB or greater hearing loss over less than 72 hours.<sup>1,2</sup> However, lack of access to pure tone audiometry (PTA) means General Practitioners (GPs) can only rule out conductive causes and refer to specialist clinics for investigation.

The most prevalent identifiable causes are: infectious (13%) otologic (5%), traumatic (4%), vascular or haematologic (3%) and neoplastic (2%).<sup>3</sup> It has long been thought that viral infection may be one of the causes of SSNHL.<sup>3</sup> It is hypothesised that viral reactivation and inflammation causes damage to critical inner ear structures such as the organ of Corti, tectorial membrane and stria vascularis.<sup>4</sup>

Severe acute respiratory syndrome coronavirus 2 (SARS-CoV-2) is a large, enveloped single stranded RNA virus that first appeared in Wuhan, China in December 2019, primarily with respiratory manifestations. It primarily binds through spike proteins to ACE2 receptors in the respiratory tract.<sup>5</sup> A small study has isolated SARS-CoV-2 in the mastoid air cells and middle ear of cadavers of known positive patients.<sup>6</sup> SARS-CoV-2 was also found in the brains of 21 (53%) of 40 deceased patients and viral proteins were detected in cranial nerves originating from the lower brainstem.<sup>7</sup> The proven presence of this virus in various parts of the brain and

peripheral nervous system suggests there may be neurological manifestations of SARS-CoV-2 which could affect auditory pathways.

Olex-Zarychta et al. report a case of a 52-year-old patient who developed left sided SSNHL between 3kHz and 8kHz with a normal right ear. The case subsequently improved with intratympanic corticosteroids.<sup>8</sup> Munro et al. observed 138 adults with SARS-CoV-2, 16 (13.2%) and reported a change in hearing and/or tinnitus following diagnosis.<sup>9</sup> Koumpa et al. report a case of a 45-year-old asthmatic male requiring ITU care for SARS-CoV-2 who reported left sided sensory neural hearing loss with a PTA that confirmed 2, 3, 4 and 6kHz frequencies being the most affected. His symptoms improved with intratympanic steroid injection, with partial improvement of his PTA thresholds.<sup>10</sup> Mustafa et al. showed that in 20 cases with proven SARS-CoV-2 there was significant deterioration of hearing to high frequency pure tone thresholds and worsened TEOAE amplitudes.<sup>11</sup>

Anecdotally our ENT department noticed that the number of patients presenting with SSNHL has increased since the beginning of the COVID-19 pandemic. Given the propensity for viruses to cause sensory neural hearing loss, we have described a retrospective observational case series of four patients with proven COVID positive PCR testing, that presented to our ENT clinics with SSNHL.

## METHODS

We retrospectively analysed our clinic logs to identify patients who had been referred to ENT Clinic after 11 March 2020 with SSNHL. This was 2 weeks before the first national lockdown in the UK. Patients could be referred through GP, A+E or the ENT casualty clinic for suspected SSNHL.

Patients with a detectable cause for SSNHL were excluded from the study as were patients who have no official positive result for SARS-2-Cov.

Retrospective data was collected using the electronic patient record system (EPR), the electronic notes and reporting system (HIS) and PTAs. All data was collected on pre-designed proforma, and any additional information for each patient was recorded separately.

Corresponding Author: Dr Saumil Mehul Shah  
Email: saumil.shah@doctors.net

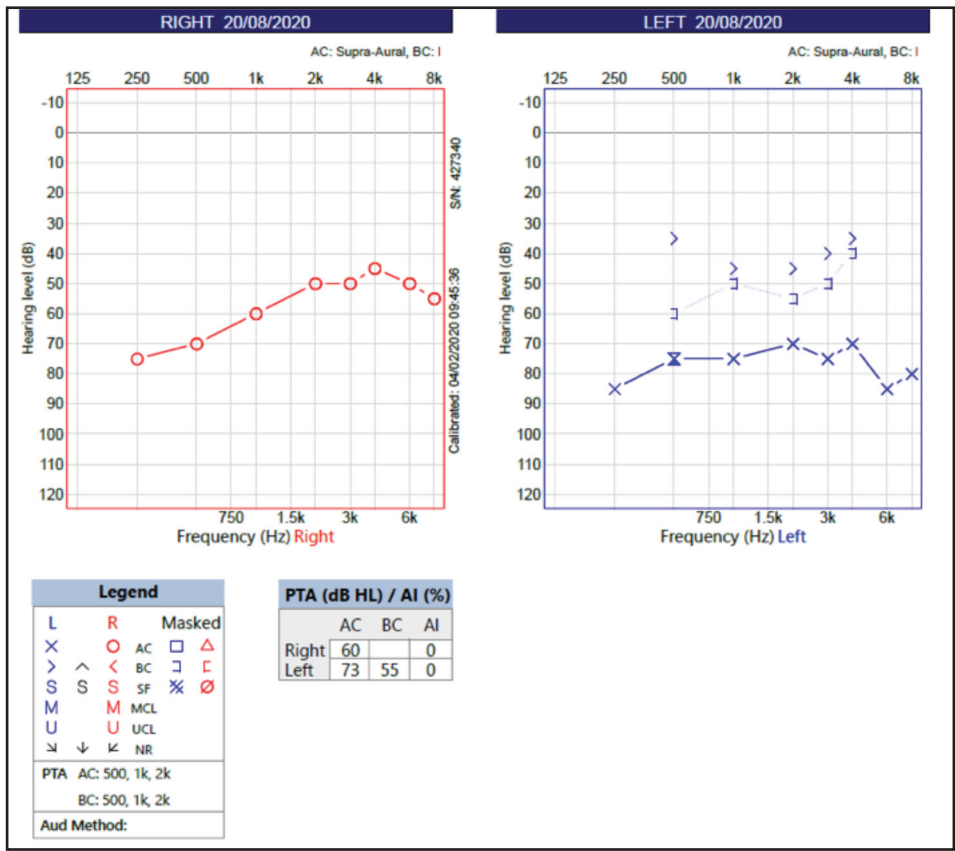


Fig. 1: Pure Tone Audiometry for Patient 1.

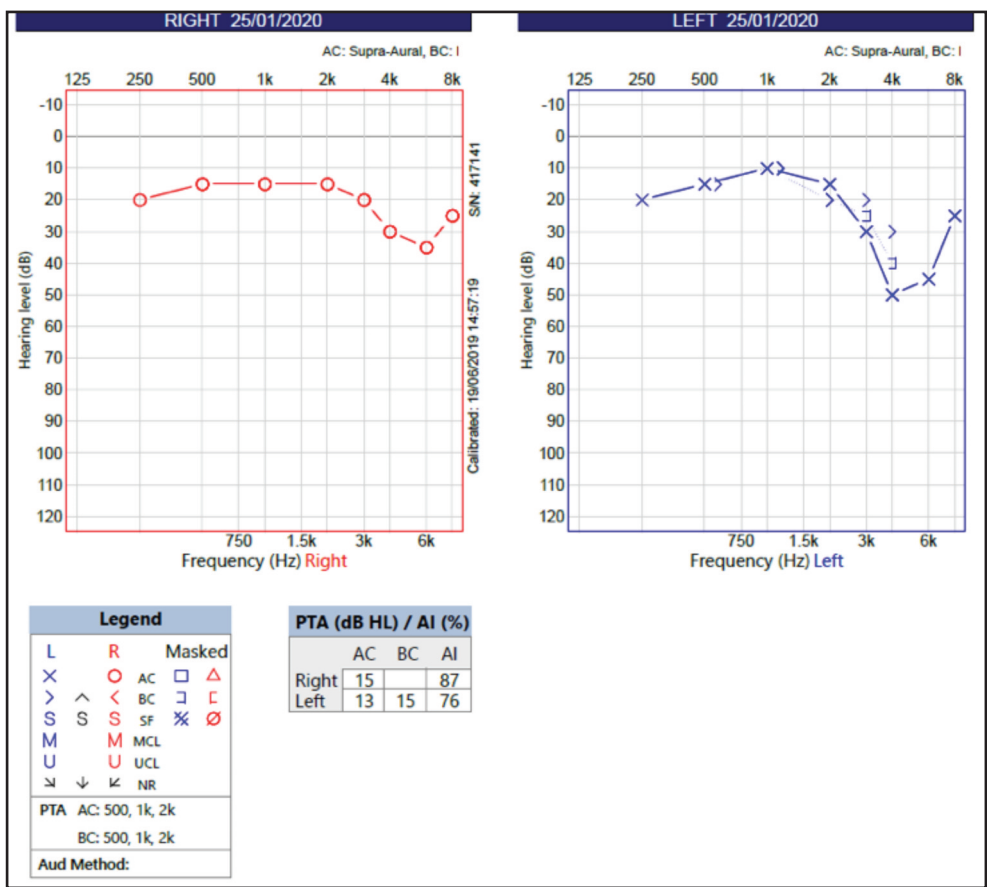


Fig. 2: Pure tone audiometry for patient 2.

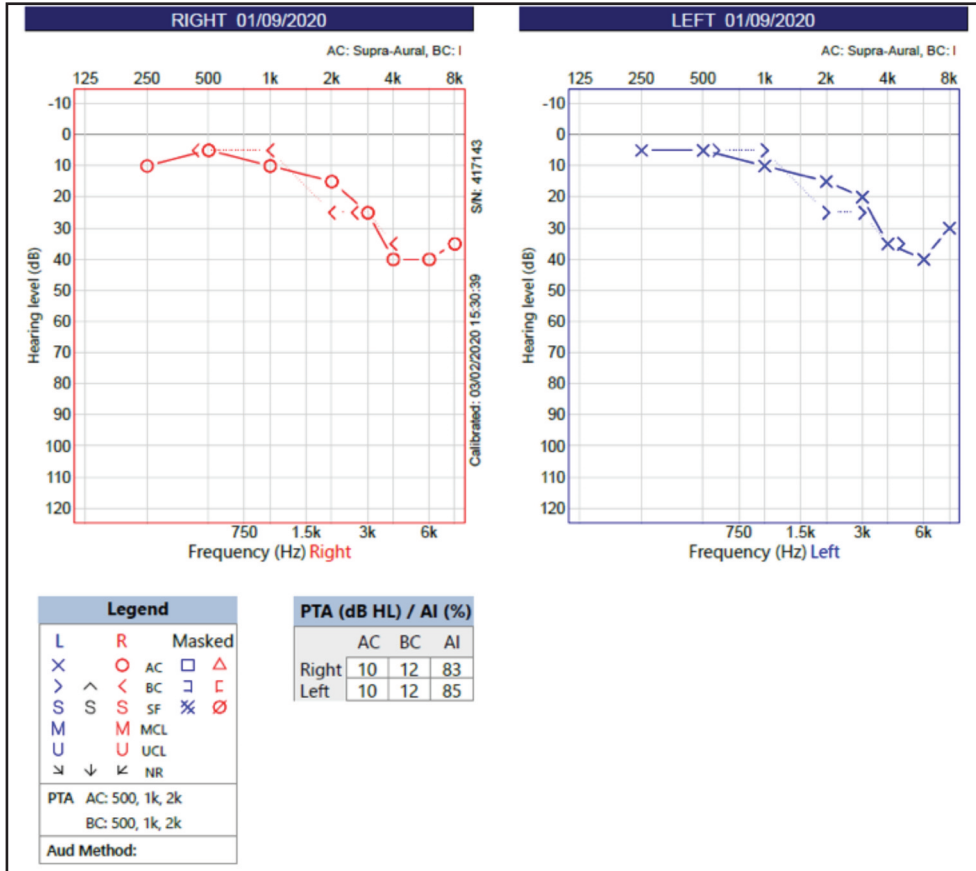


Fig. 3: Pure Tone Audiometry for Patient 3.

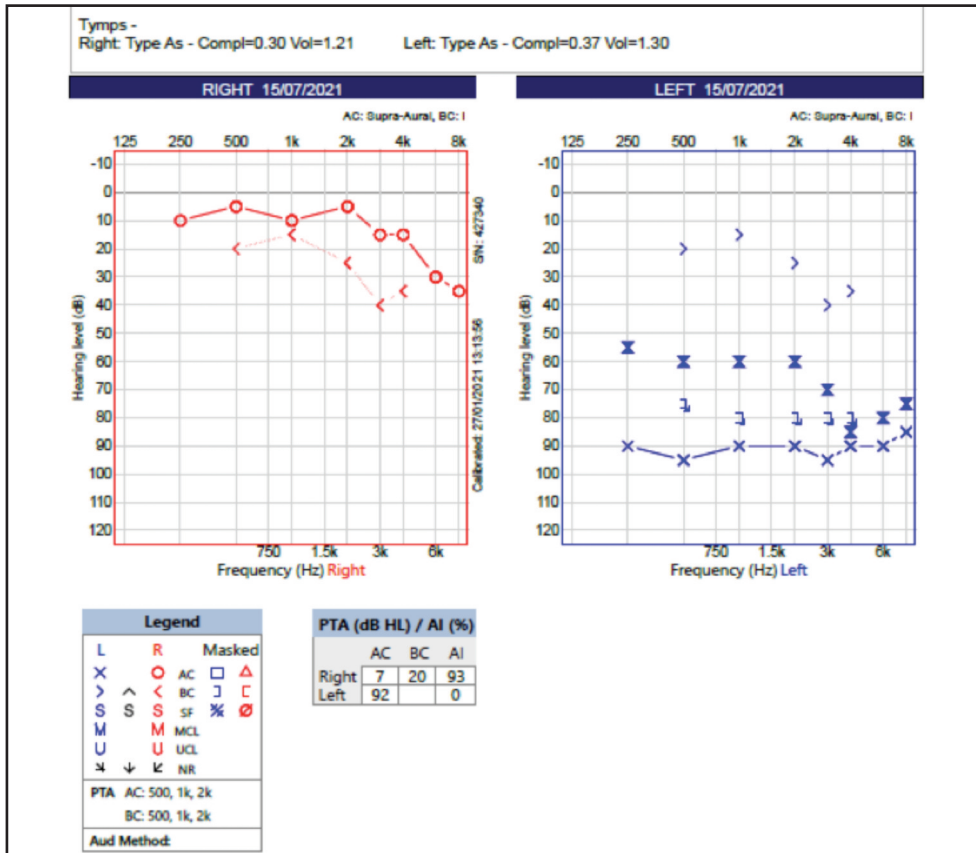


Fig. 4: Pure Tone Audiometry for Patient 4.

**Results:**

A total of three patients met the criteria for selection.

**Patient 1**

This 46-year-old female presented after contracting SARS-COV-2 in April 2020. During which she developed anosmia, loss of taste and 'flu-like' symptoms. She subsequently recovered.

Approximately 3 weeks after initial onset, she developed bilateral muffled hearing, pulsatile tinnitus and dizziness. Her imbalance was exacerbated when moving from a lying to sitting position.

Due to the persistent symptoms, she was referred by her GP to the ENT clinic, where she was assessed 7 weeks after onset of symptoms. Her initial assessment was with a telephone consultation. At this point the working diagnosis was otitis media with effusion and Otovent was prescribed. Patient was not prescribed oral steroids.

At the subsequent face-to-face appointment, she denied otalgia or discharge from either ear. On examination both tympanic membranes were normal. A pure tone audiogram demonstrated right sided moderate to severe sensorineural hearing loss, and on the left the PTA showed a mixed picture. She had type B tympanometry bilaterally (Figure 1). The patient was not given oral steroids as it was more than 8 weeks from onset of her hearing loss.

A grommet was inserted to help improve the conductive aspect in the left ear. She was also referred for hearing aids as the sensorineural component had not improved.

**Patient 2**

This patient was a 43-year-old female. She presented to her GP with a short history of vertigo. She was seen by the ENT department face to face two weeks later. She has previously tested COVID positive, her predominant symptom was loss of smell and flavour.

At the face-to-face clinic she was assessed for other possible causes of vertigo, however, she showed no signs of benign positional paroxysmal vertigo (BPPV), or Meniere's disease. Her neurological exam was normal. A full ENT exam was performed which was normal. She was prescribed balance exercises, advised to avoid vestibular sedatives and referred for tinnitus therapy. No steroids were prescribed.

Pure tone audiometry revealed a sensorineural loss bilaterally in the range of 4000 to 8000 Hz (fig. 2). An MRI IAM was normal.

**Patient 3**

A 54-year-old lady presented with right unilateral pulsatile tinnitus and hearing loss for 2 months. The onset was a few weeks after she was diagnosed with SARS-CoV-2 and she had recovered from mild associated symptoms. Due to COVID 19 a telephone consultation was conducted. She did not report of any other ENT symptoms at the time.

As she presented 2 months after onset of symptoms, it was decided not to start the patient on oral corticosteroids. MRI IAM was normal. Pure tone audiometry once again showed a decreased hearing threshold in the range of 4000 to 8000 Hz (Fig. 3). Due to the prolonged hearing loss this patient was referred for fitting of hearing aids.

**Patient 4**

A 51 year-old male presented with increased dyspnoea cough who had recently tested positive via a COIVD PCR test. His chest x-ray confirmed the diagnosis of SARS CoV-2 with bilateral patchy infiltrates. He was started on oxygen to maintain saturations, dexamethasone, remdesivir, thiamine, dalteparin and ascorbic acid. He had no significant past medical history. Over the course of the next two months the patient was managed in our intensive care unit for respiratory support.

After being stepped down from ICU the patient complained of sudden unilateral right sided hearing loss and tinnitus. The patient did not complain of any vertigo, ear fullness, otorrhoea or otalgia. On examination the tympanic membranes were intact and healthy bilaterally. The patient was commenced on oral prednisolone 40mg for 1 week. After 4 days there was no improvement with the steroid treatment and an MRI of the internal auditory meatus was performed which was normal. The patient's pure tone audiogram demonstrated a profound sensory neural hearing loss on the left side. Unfortunately, the patient's hearing did not improve when subsequently reviewed in ENT clinic. As a result, he has been referred to audiology for CROS – aids and appropriate symptom management.

**DISCUSSION:**

Interestingly, three of the patients showed hearing loss bilaterally. Patients two and three only showed this loss at higher frequencies while patient 1 had decreased hearing in both ears, worse at higher frequencies. This result is similar to patients observed in the study by Mustafa et. al.<sup>11</sup> Patient four developed a unilateral dead ear, and had the most severe reaction to COVID-19. Unilateral hearing loss is generally more typical of viral illnesses, but various viruses have shown bilateral hearing loss too.<sup>4</sup> It should be noted the fourth patient developed hearing loss despite various courses of IV and Oral steroids through the course of his treatment.

ACE-2 is not shown to be well expressed in the endothelium of the neural structures and vessels.<sup>12</sup> Instead, the receptors basigin (BSG) and neuropilin-1 (NRP-1) have been shown as potential docking receptors for SARS-CoV-2.<sup>13,14,15</sup> Knockout of NRP-1 has been shown to lead to progressive hearing loss in mice, due to disorganized outer spiral bundles and enlarged micro vessels of the stria vascularis in the cochlea.<sup>15,16</sup> Destruction of the outer spiral bundles would lead to hearing loss at higher frequencies. Hearing loss at higher thresholds was seen in 3 of our patients, correlating to these areas identified in animal studies. While in the fourth patient all frequencies were equally effected. In cases 2 and 3 the hearing loss is specifically in the higher frequencies; it could be due to other pathologies such as noise induced hearing loss. However, given the onset of complaint of hearing loss

(within weeks of the COVID-19 infection) and descriptions from other papers such as Musafa et. al, Koumpa et. al, and Olex-Zarychta et. al, who have reported hearing loss as similar ranges. This SSNHL may be secondary to the viral infection within the outer spiral bundles.<sup>8,10,11</sup>

In more advanced stages the virus is shown to compromise the endothelial barrier (NRP-1 and NSG are both expressed here) leading to infiltration of monocytes and neutrophils causing oedema in addition to triggering an intravascular coagulation response leading to thrombotic complications such as myocardial ischaemia, pulmonary embolisms and limb ischaemia.<sup>17</sup> Additionally, Lowenstein et. al. postulate that it may simultaneously be causing a microvascular inflammatory response as well as a microvascular thrombotic response.<sup>18,19</sup> Interestingly, SSNHL has been shown to have a significant association with the prospective development of cardiovascular disease (HR, 2.18; 95% CI, 1.20-3.96).<sup>20</sup> This suggests that SSNHL could present as an early sign for a patients in hypercoagulable states.

It has also been suggested that SARS-CoV-2 may also shed proteins of damaged cells into the blood stream that can act as PAMPs and damage associated molecular patterns inducing an innate immune response from cells expressing toll-like receptors.<sup>15</sup>

SARS-CoV-2 has also shown delayed manifestations due to immune responses that typically take a few weeks to manifest.<sup>15</sup> Various studies have noted an increase in patients presenting with Guillain-Barré Syndrome (GBS)/ Miller-Fisher syndrome and one study in particular presented a case of a patient who presented with miller-fisher like symptoms twenty days after contracting SARS-CoV-2. In the CSF, presence of anti-ganglioside antibodies may have been implicated in causing an immune response in the peripheral nervous system.<sup>21</sup> Hence SARS-CoV-2 may be affecting the peripheral nervous system without infecting the CNS, as part of the post COVID syndrome.

We have presented here four patients in this retrospective case series who developed SSNHL around the time they had SARS-CoV-2. As there is a lack of pre-infection audiograms it is difficult to ascertain for sure if SARS-CoV-2 was the direct cause of their otological pathology. All patients are between the ages of 40-50 with few other comorbidities, no previous otological complaints and no history of previous significant noise exposure. The timing of their onset of SSNHL with relation to the infection, would lead us to propose that there may be an association between SSNHL and SARS CoV-2 infection. We have also discussed various pathophysiological mechanisms that may explain this association but further work is required to confirm or refute this.

## REFERENCES

- Cunningham LL, Tucci DL. Hearing loss in adults. *N Engl J Med* 2017; 377(25): 2465-73.
- Kuhn M, Heman-Ackah SE, Shaikh JA, Roehm PC. Sudden sensorineural hearing loss. *Trends Amplif* 2011; 15(3): 91-105.
- Chau JK, Lin JR, Atashband S, Irvine RA, Westerberg BD. Systematic review of the evidence for the etiology of adult sudden sensorineural hearing loss. *Laryngoscope* 2010; 120(5): 1011-21.
- Cohen BE, Durstenfeld A, Roehm PC. viral causes of hearing loss: a review for hearing health professionals. *Trends Hear* 2014; 18: 2331216514541361.
- Wiersinga WJ, Rhodes A, Cheng AC, Peacock SJ, Prescott HC. Pathophysiology, transmission, diagnosis, and treatment of Coronavirus Disease 2019 (COVID-19). *JAMA* 2020; 324(8): 782-93.
- Frazier KM, Hooper JE, Mostafa HH, Stewart CM. SARS-CoV-2 virus isolated from the mastoid and middle ear. *JAMA Otolaryngol Head Neck Surg* 2020; 146(10): 964-66.
- Matschke J, Lütgehetmann M, Hagel C, Spherhake JP, Schröder AS, Edler C et al. Neuropathology of patients with COVID-19 in Germany: a post-mortem case series. *The Lancet Neurol* 2020; 19(11): 919-29.
- Olex-Zarychta D. Successful treatment of sudden sensorineural hearing loss by means of pharmacotherapy combined with early hyperbaric oxygen therapy: case report. *Medicine (Baltimore)* 2017; 96(51): e9397.
- Munro KJ, Uus K, Almufarrij I, Chaudhuri N, Yioe V. Persistent self-reported changes in hearing and tinnitus in post-hospitalisation COVID-19 cases. *Int J Audiol* 2020; 59(12): 889-90.
- Koumpa FS, Forde C, Manjaly JG. Sudden irreversible hearing loss post COVID-19. *BMJ Case Rep* 2020; 13(11): e238419.
- Mustafa MWM. Audiological profile of asymptomatic Covid-19 PCR-positive cases. *Am J Otolaryngol* 2020; 41(3): 102483.
- Chen R, Wang K, Yu J, Howard D, French L, Chen Z et al. The spatial and cell-type distribution of SARS-CoV-2 receptor ACE2 in human and mouse brain. *Front Neurol* 2021; 11: 573095.
- Wang K, Chen W, Zhou Y, Lian JQ, Zhang Z, Du P et al. CD147-spike protein is a novel route for SARS-CoV-2 infection to host cells. *Signal Transduct Target Ther* 2020; 5: 283.
- Cantuti-Castelvetri L, Ojha R, Pedro LD, Djannatian M, Franz J, Kuivanen S et al. Neuropilin-1 facilitates SARS-CoV-2 cell entry and infectivity. *Science* 2020; 370(6518): 856-60.
- Iadecola C, Anrather J, Kamel H. Effects of COVID-19 on the nervous system. *Cell* 2020; 183(1): 16-27.e1.
- Salehi P, Ge MX, Gundimeda U, Michelle Baum L, Lael Cantu H, Lavinsky J et al. Role of Neuropilin-1/Semaphorin-3A signaling in the functional and morphological integrity of the cochlea. *PLoS Genet* 2017; 13(10): e1007048.
- Klok FA, Kruij MJHA, van der Meer NJM, Arbous MS, Gommers DAMPJ, Kant KM et al. Incidence of thrombotic complications in critically ill ICU patients with COVID-19. *Thromb Res* 2020; 191: 145-47.
- Lowenstein CJ, Solomon SD. Severe COVID-19 is a microvascular disease. *Circulation* 2020; 142(17): 1609-11.
- Kasal DA, De Lorenzo A, Tibiriçá E. COVID-19 and microvascular disease: pathophysiology of SARS-CoV-2 infection with focus on the renin-angiotensin system. *Heart Lung Circ* 2020; 29(11): 1596-602.
- Kim JY, Hong JY, Kim DK. Association of sudden sensorineural hearing loss with risk of cardiocerebrovascular disease. *JAMA Otolaryngol Head Neck Surg* 2018; 144(2): 129.
- Senel M, Abu-Rumeileh S, Michel D, Garibashvili T, Althaus K, Kassubek J et al. Miller-Fisher syndrome after COVID-19: neurochemical markers as an early sign of nervous system involvement. *Eur J Neurol* 2020; 27(11): 2378-80.