

Massive penile lipogranuloma following olive oil injections

Fadya Nabiha A.S Ahmad Shariffuddin, MBBS, Fam Xeng Inn, MS, Fatimah Mohd Nor, MS (Plastic), Muhamad Hud Muhamad Zin, MD

Department of Surgery, Hospital Canselor Tuanku Muhriz, University Kebangsaan Malaysia Medical Center, Kuala Lumpur, Malaysia

SUMMARY

Penile self-injections are performed with the purpose of increasing the size of the penis. Commonly, mineral oils or mineral oil-like substances are used for this purpose. However, there are very few publications describing on the complications from vegetable oil injections especially olive oil. Following the injection, the resulting deformity of the male genitalia is described as penile paraffinomas lipogranuloma of the penis. We would like to report a case of penis augmentation by a 50-year-old gentleman using olive oil injections that caused a massive, severely deformed of the penis and scrotum. Surgical excision and reconstruction was done. The patient was discharged after five days post-operatively, with full graft take.

Injecting any oily substances into the human body is hazardous. The differential diagnosis of nodules following injections should be kept in mind and in doubtful cases, biopsy should be done. Regular follow-up is essential to prevent the further inflammatory event. Safe and legal procedures should be implemented for penile enlargement so as to avoid self-injections and in the prevention of such debilitating problems.

INTRODUCTION

Penile self-injections are performed with the purpose of increasing the size of the penis. Commonly, mineral oils or mineral oil-like substances are used for this purpose. However, there are very few publications describing on the complications resulting from vegetable oil injections especially olive oil. Following the injection, the resulting deformity of the male genitalia is described as penile paraffinomas lipogranuloma of the penis. We would like to report a case of penis augmentation by using olive oil injections causing massive, severely deformed of the penis and scrotum.

CASE REPORT

A 50-year-old gentleman was given subcutaneous olive oil injections into his penile shaft by some unknown personnel. It was done in 1 session with an unknown amount and was given in a non-sterile environment. After 3 months of the injection, the penis began to swell, deform, and harden. Over this time, the penile shafts gradually became deformed, swollen, and hard. He was able to achieve an erection, however, the erection and sexual intercourse became painful at one year after the injection. He started to seek for treatments after 1 year of the injection. Physical

examinations showed that the penile shaft was massively swollen and disfigured, measuring 7cm x 10cm with irregular semi-mobile masses extending into the scrotum. The overlying skin was diffusely dark with no cutaneous ulceration. After a full history taking and physical examination, followed by patient counselling, the decision was made to proceed with a surgical excision of the mass and penile reconstruction. Full skin excision was required in this patient because the granulomas were extensive; involving subcutaneous tissue of the penile shaft with extension into the overlying penile skin. The fibrotic skin and subcutaneous tissue were circumferentially excised from the corona distally to the scrotum proximally down to the level of Buck's fascia. Thick split skin grafts, harvested from the inner thigh, was used to cover the bare penile shaft. The patient was discharged after five days post-operatively, with full graft take. At the outpatient review, one month postoperatively the wound was well healed. Histopathological examination showed multiple lipid vacuoles occupying almost the entire pieces of skin tissue with surrounding numerous granulomas but with no malignant cells seen, consistent with a diagnosis of lipogranuloma.

DISCUSSION

There are many publications about granuloma formation and other tissue reactions following mineral oil injections for body augmentation but there are very few publications describing complications from vegetable oil injections, especially olive oil. Granuloma formations after intramuscular injections using sesame seed oil¹ and oleomas due to sunflower oil injections² in bodybuilders have been previously reported.

Olive oil has been reported to be used together with other augmentation solutions such as industrial-grade silicone or paraffin for breast augmentation before the 1960's when medical-grade silicon was not yet available. Olive oil contains phenol that acts as a sclerosing agent, thus the purpose of using olive oil in breast augmentation at that time was to cause a sclerosis reaction in the breasts, to contain the liquid silicone or paraffin, and to hopefully prevent it from migrating through the breast tissue to other sites. Nevertheless, the adverse effects of the injected liquid were very similar to those of paraffin and industrial-grade silicon. These included the following adverse effects: migration of silicone to other parts of the body, inflammation, discoloration, and the formation of granulomas, ulceration, and fistulae formation. To the best of our knowledge, there are no reports describing lipogranuloma due to olive oil as a

This article was accepted: 01 August 2021

Corresponding Author: Nabiha A.S Ahmad Shariffuddin

Email: blackgaura0404@gmail.com

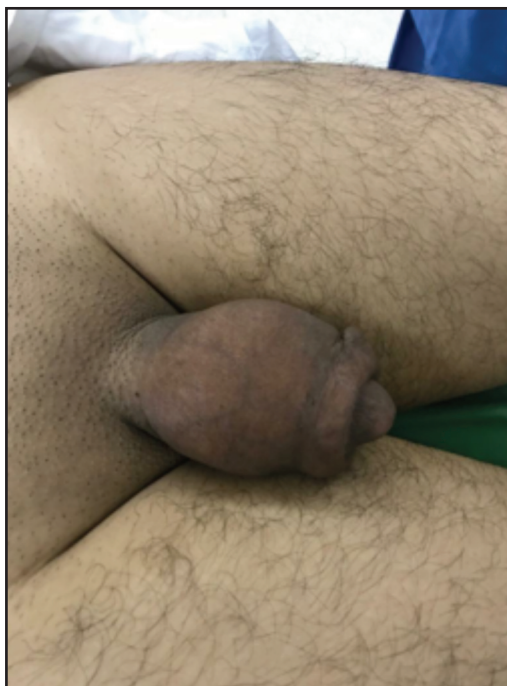

Fig. 1: Massively swollen penis measuring 7cm x 10cm with irregular semi-mobile masses extending into the scrotum.

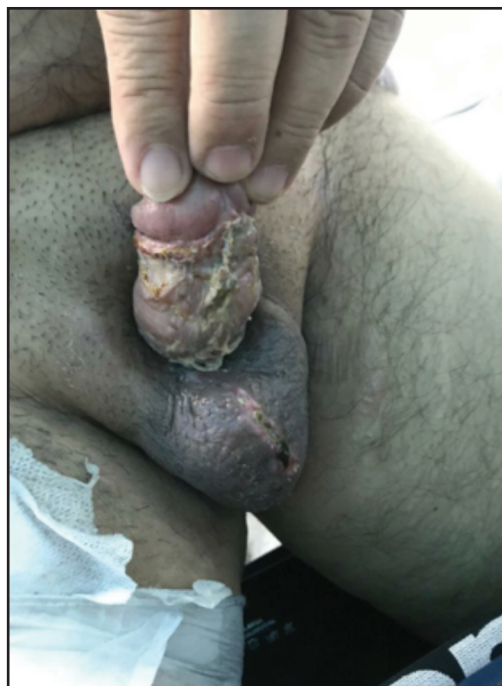


Fig. 2: Post-operative Day 14 photo demonstrates the end results after excision of the lipogranuloma and closure with Split-thickness Skin Graft.

single agent for body augmentation. There is also no study reporting factors that can influence the amount or size of lipogranuloma which develops from olive oil is as the same as the foreign-body reaction from the administration of mineral or other vegetable oils, involving macrophages that react to the foreign material by surrounding it and forming giant multinucleated cells.³ However, in comparison with clinical presentation, inflammatory reactions and histopathological findings in our patient are similar with other mineral oil. Olive oil has been shown to cause lipogranulomas not only on the subcutaneous injection site but also appeared on the capsular or serosal surface of the abdominal organs in a study using rodents when injected subcutaneously. The olive oil may have reached the peritoneal cavity from the subcutaneous tissue passively via the lymphatic vessels or actively after engulfment by antigen-presenting cells via the lymphatic or blood vessels.³ However, whether olive oil can cause a massive reaction surrounding the injection site or not, remains unknown.

The diagnosis is however challenging if the patient does not reveal the information and misdiagnosis of malignancy that may happen. Some studies have shown that magnetic resonance imaging (MRI) to be effective in diagnosing paraffinomas aside from biopsy and this depends on the time interval before its presentation.⁴ Various methods of treatment from conservative management such as steroid injection and hot water baths to radical surgical management like excision with skin grafting repair are available. A complete surgical excision of the nodule is the definitive treatment in order to prevent recurrence.

Antibiotics and topical and or systemic steroids can be used for the medical treatment of primary sclerosing lipogranuloma, however success has never been reported for treatment of foreign body induced lipogranuloma. Surgery is the best treatment for penile lipogranuloma for both primary and foreign body induced. Granulomatous skin needs complete excision. Common options for wound closure are scrotal skin flap, Cecil's inlay operation, and a Split thickness Skin Graft (SSG).⁵ The most successful management technique for a denuded penis is penile split-thickness skin grafts which demonstrates a good graft survival 5 and are able to achieve full erection with normal sexual intercourse after the surgery.⁵

CONCLUSION

Injecting any oily substances into the human body is hazardous. The differential diagnosis of nodules following injections should be kept in mind and in doubtful cases, biopsy should be done. Regular follow-up is essential to prevent the further inflammatory event. Safe and legal procedures should be implemented for penile enlargement so as to avoid self-injections and in the prevention of such debilitating problems.

CONFLICT OF INTEREST

The authors have no conflicts of interest to declare.

INFORMED CONSENT

Written informed consent was obtained from the patient for the publication of this article.

ACKNOWLEDGEMENT

The authors would like to thank the Director General of Health Malaysia to publish this article.

REFERENCES

1. Darsow U, Bruckbauer H, Worret WI, Hofmann H, Ring J. Subcutaneous oleomas induced by self-injection of sesame seed oil for muscle augmentation. *J Am Acad Dermatol* 2000; 42: 292-4.
2. Sarca Ö, Kayhan A, Demirkürek HC, İğdem AA. Subcutaneous Oleomas Following Sunflower Oil Injection: A Novel Case and Review of Literature. *J Breast Health* 2016; 12(3): 141-4.
3. Ramot Y, Ben-Eliahu S, Kagan L, Ezov N, Nyska A. Subcutaneous and intraperitoneal lipogranulomas following subcutaneous injection of olive oil in Sprague-Dawley rats. *Toxicol Pathol* 2009; 37(7): 882-6.
4. Cormio L, Di Fino G, Scavone C, et al. Magnetic resonance imaging of penile paraffinoma: case report. *BMC Med Imaging* 2014; 14:39.
5. Inn FX, Imran FH, Ali MF, Ih R, Z Z. Penile augmentation with resultant foreign material granuloma and sequalae. *Malays J Med Sci* 2012; 19(4): 81-3.