

# Internal jugular vein thrombosis in a child

Pui Ling Thong, MMed, Azyati Yusoff, MMed, Melissa Nunis, MMed, Khairon Nisa Mohamed Nashrudin, MBBS

Department of Paediatrics, Faculty of Medicine and Health Sciences, Universiti Putra Malaysia

### SUMMARY

Venous thrombosis is a potentially life-threatening condition with varied aetiology. First described in 1912 as a complication of peritonsillar abscess, internal jugular vein (IJV) thrombosis is a rare entity in children with very few cases reported until now. Among the leading causes of this condition are prolonged use of IJV for venous access and central venous catheterisation, acute mastoiditis and Lemierre's syndrome.<sup>1</sup> IJV thrombosis can also occur as a complication of head and neck infections, but rarely appears as its first presentation. The clinical manifestations are often vague and ambiguous, thus requiring a high index of suspicion to diagnose IJV thrombosis. We describe here a case of internal jugular vein thrombosis (IJVT) and the management of this rare condition in an otherwise healthy 8-year-old boy. The patient was investigated thoroughly to rule out possible pathological causes of IJV thrombosis and managed holistically with a multidisciplinary team approach. Although the occurrence is rare, it should be recognised as a complication of deep neck infections in order to initiate prompt and accurate therapy.

### CASE REPORT

A healthy 8-year-old boy was admitted with a 3-day history of enlarging, painful left sided neck swelling preceded by intermittent fever and cough for 2 weeks. There were no constitutional symptoms or weight lost, and his appetite was good. He had no significant history of contact with tuberculosis patients, prolonged central venous catheterisation or trauma. There were no known family history of haematological malignancies or pro-thrombotic disorders.

Clinically he was stable with no signs of tachypnoea or respiratory distress. He was febrile with temperature of 39°C and neck examination revealed a tender, firm, diffuse swelling over the left anterior triangle, measuring approximately 3cm x 5cm. There were multiple small cervical lymph nodes palpable bilaterally but there were no axillary or inguinal lymphadenopathy. BCG scar was present and he had moderate congestion of his throat. Respiratory examination revealed clear lung fields bilaterally on auscultation and examination of other systems were unremarkable. Following his clinical presentation, differential diagnoses of lymphadenitis and deep neck infections were sought and worked up.

Initial laboratory test revealed white blood cell count of  $22.5 \times 10^9/L$  predominantly neutrophils 89% with an elevated C-reactive protein of 70.9 mg/L and erythrocyte sedimentation

rate (ESR) of 78 mm/hr. Platelet count and liver enzymes were within normal ranges apart from serum albumin of 25g/L. Tuberculosis (TB) workup which included Mantoux test, gastric lavage for acid fast bacilli (AFB) smear and culture were negative. Chest radiograph performed was normal with no evidence of consolidation or widened mediastinum. Serial bacterial cultures in the blood and nasopharyngeal aspirates, as well as polymerase chain reaction (PCR) tests for common viruses yielded no growth. Titres were negative for *Burkholderia pseudomallei* and *Bartonella henselae*. Urgent ultrasound of the neck demonstrated a deep heterogenous collection over the left sternocleidomastoid (SCM) extending into the left thyroid lobe and isthmus, with thrombosis of the left internal jugular vein. Following the findings of venous thrombosis on the ultrasound report, thrombophilia and autoimmune screening were initiated. Blood tests were sent for protein C and S, antithrombin III, antiphospholipid antibody, antinuclear antibody, rheumatoid factor as well as complement levels, and results were within normal limits. Screening for primary and secondary immunodeficiency were unremarkable. Chest radiograph did not show any consolidation or widened mediastinum.

Following that, antimicrobial therapy comprising of intravenous ceftriaxone and cloxacillin was initiated to provide appropriate antimicrobial coverage. Further radiological evaluation with computed tomography (CT) scan and echocardiography reported similar findings of left IJV thrombosis and soft tissue inflammation, with the involvement of the oropharynx, thyroid lobe and sternomastoid muscle. Referral to surgical and cardiology team was sought. Intravenous heparin infusion was initiated and subsequently converted to subcutaneous enoxaparin after one week. The patient improved clinically while on treatment, did not required surgical drainage and was ultimately discharged with a total of 8 weeks subcutaneous enoxaparin and two weeks of antibiotics (consisting of intravenous ceftriaxone and cloxacillin for one week, followed by oral cefuroxime and coxacillin). Repeated doppler ultrasonography after 2 months showed resolution of the neck abscess and IJV recanalization with residual short segment thrombosis. Anticoagulant treatment was discontinued at this junction as he was asymptomatic and well. Unfortunately, his clinical course was later complicated with recurrent abscess formation. He was readmitted 4 months after his initial hospitalisation with similar presentation of neck swelling associated with pain and compressive symptoms. Ultrasonographic examination demonstrated the presence of a left neck collection with persistent unilateral short segment IJV devoid of colour signal, in keeping with chronic thrombosed IJV. A contrast

This article was accepted: 01 April 2021

Corresponding Author: Dr Thong Pui Ling

Email: t\_puiling@upm.edu.my

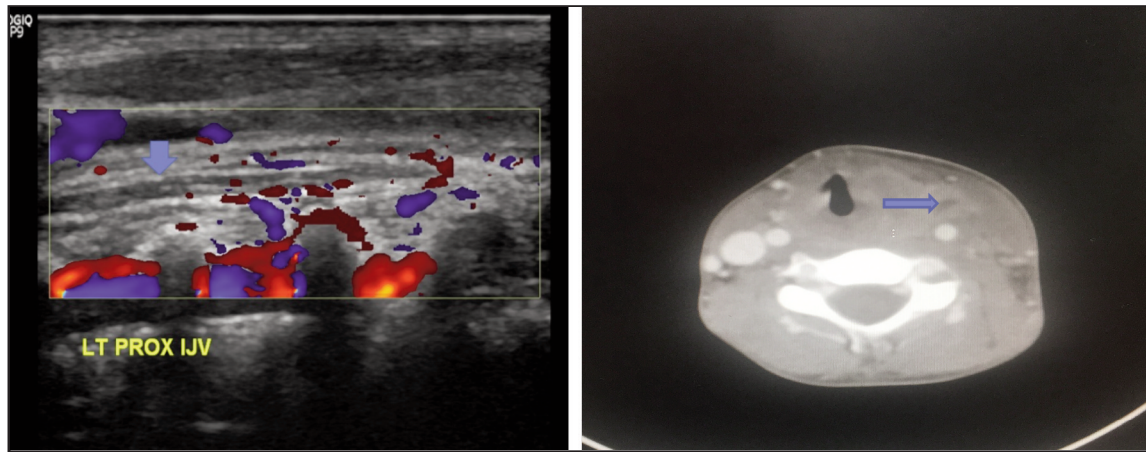


Fig. 1: (a), (b): Short segment IJV thrombosis (blue arrow) noted on the ultrasound doppler of neck. CT scan of neck (axial view) demonstrating a partially occlusive thrombus in the left internal jugular vein (blue arrow) with diffuse soft tissue thickening.

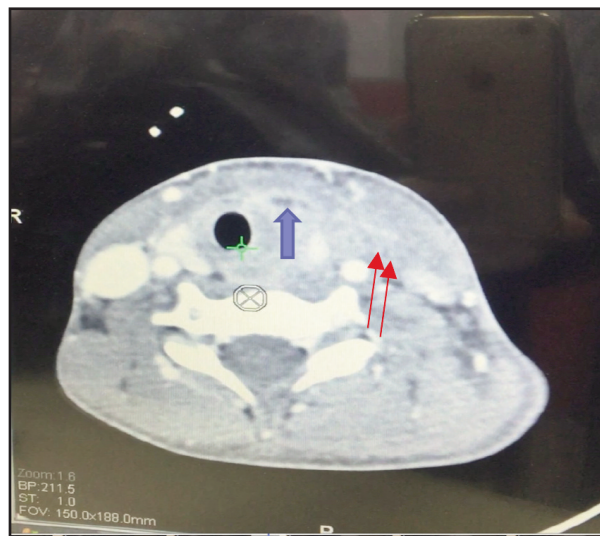


Fig. 2: A repeated CT scan of the neck showing compressed thrombus in the left internal jugular vein (blue arrow) with multi-loculated abscess measuring 2.1 x 1.9 x 2.5 cm (red arrow). Trachea is displaced to the right.

enhanced CT of the neck showed the presence of multi-loculated left neck abscesses causing mass effect to the trachea, thyroid gland and left IJV. Otherwise, there was no reported transverse sinus thrombosis or mediastinal extension involvement. He subsequently underwent incision and drainage of the abscess, with total of 30mls pus drained. Intraoperative samples sent for bacterial and TB culture, TB PCR and cytology were negative. In addition to intravenous ceftriaxone and cloxacillin, oral clarithromycin was initiated as his serum titre of *Mycoplasma pneumoniae* antibody was 1:320. There was rapid resolution of fever and he was discharged 2 weeks later upon completion of intravenous antibiotics. Oral clarithromycin and cloxacillin was continued for a total four weeks respectively. The patient eventually made gradual recovery with complete resolution of his abscesses and remained well 12 months later during his routine follow-up.

## DISCUSSION

Internal jugular vein thrombosis is commonly seen in adult patients and very few cases are reported in children. The pathophysiology behind the inherited and acquired causes of venous thrombosis is the impaired local or systemic blood flow based on the Virchow triad of stasis, hypercoagulable state and vascular injury.<sup>2</sup> In our case, all three factors may be in operation and contributed to the development of IJV thrombosis. The unresolved neck abscess with the surrounding matted lymph nodes in this patient led to venous stasis and vascular obstruction. The ongoing infection and inflammation are risk factors for hypercoagulable state, attributed by an increased rate of fibrinogen production and platelet activity which developed secondary to an acute phase response. Venous thrombosis also occurs as a result of infection induced vascular damage when the vein is affected by an adjacent septic focus. The adventitia, which is the

initial site of involvement usually becomes congested and infiltrated by inflammatory cells. Thrombus formation occurs when the inflammation reaches the intima and involves all the layers of the vein where the adherence of fibrin, blood cells and platelet take place.

Despite the increasing awareness of *M. pneumoniae* infection, IJV thrombosis is an extremely rare extrapulmonary manifestation described in the literature. Our patient's IJV thrombosis occurred at the same time he had a serologically proven *M. pneumoniae* infection. The question remains if the Mycoplasma infection happens to be a casual or causal relationship to the development of venous thrombosis in this patient. Although there were reports detailing the thrombotic manifestations associated with *M. pneumoniae* infections, the exact mechanism of the venous thrombosis remained obscure.<sup>3</sup> Hypothetical mechanisms postulated are the direct invasion by the organism causing toxin production, autoantibody with immune complex formation, microthrombosis and impaired immunity. *In vitro* experimental studies have previously suggested the production of lipoglycans from *M. pneumoniae* infection can induce procoagulant activity and potentially trigger the mechanism of intravascular coagulation.<sup>4</sup>

In most cases, venous thrombosis occurs in patients with generalized hypercoagulable state which may be inherited or acquired. However, retrospective history and extensive laboratory screening for antithrombin III deficiency, deficiency of protein C or S, and antiphospholipid syndrome in our patient did not revealed any significant contributors to the pathogenic mechanisms. General guidelines for the treatment of thromboembolic events in children include intravenous heparin or subcutaneous low molecular weight heparin for several days and subsequent overlapping with anticoagulants until the target therapeutic value of prothrombin time is achieved. Anticoagulant therapy is stopped after three to six months when risk factors for thrombotic events are eliminated. Despite the presence of residual short segment thrombosis, anticoagulants were discontinued after 2 months as there was documented evidence of jugular vein recanalization and the patient was asymptomatic. When a second recurrence of thromboembolic event is present, indefinite oral anticoagulant therapy should be considered though some investigators dispute the usefulness of anticoagulants that are thought to carry significant potential risks. Intravenous antibiotic treatment against targeted infective organisms should be started and

tailored accordingly to the culture results. Should a favourable resolution be observed after approximately 2 weeks of intravenous antibiotics, oral administration can be started and continued for a total duration of four to six weeks.<sup>5</sup> Surgical drainage is indicated for non-resolving, loculated abscesses or other adverse sequelae, which occurs as a result of poor response to medical therapy.

#### CONCLUSION

We propose that the present case demonstrates the importance of identifying IJV thrombosis as an important differential diagnosis in children who present with painful neck swelling, especially in the course of any oropharyngeal or deep seated neck infections. Successful management rests on the awareness of the condition, a high index of suspicion and prompt intervention with a multidisciplinary team approach. Antibiotic treatment for four to six weeks associated with anticoagulant treatment can be considered as safe and effective. Surgical intervention should be performed to eliminate the source of infection if there is failure to respond to appropriate and adequate duration of antimicrobial therapy.

#### ACKNOWLEDGEMENT

The author(s) thank Department of Paediatrics, Faculty of Medicine and Health Sciences Universiti Putra Malaysia for the support.

#### DECLARATION OF CONFLICTING INTERESTS

The author(s) declared no potential conflicts of interest with respect to the authorship and/or publication to this article.

#### REFERENCES

1. Sengupta S, Kalkonde Y, Khot R, Paithankar M, Salkar R, Salkar H, et al. Idiopathic bilateral external jugular vein thrombosis – a case report. *Angiology* 2001; 52(1): 69–71.
2. Yang JY, Chan AK. Pediatric thrombophilia. *Pediatr Clin North Am* 2013; 60(6): 1443–62.
3. Joo CU, Kim JS, Han YM. Mycoplasma pneumoniae induced popliteal artery thrombosis treated with urokinase. *Postgrad Med J* 2001; 77(913): 723-4.
4. Fumarola D. Intravascular coagulation and Mycoplasma pneumoniae infection. *Pediatr Infect Dis* 1997; 16(10): 1012–3.
5. Agarwal A, Lowry P, Isaacson G. Natural history of sigmoid sinus thrombosis. *Ann Otol Rhinol Laryngol* 2003; 112(2): 191-4.