

# Concurrent Influenza A and Pulmonary Melioidosis in pregnancy

Wen Foong Tan, MRCP, Heng Gee Lee, MRCP

Department of Medicine, Queen Elizabeth Hospital, Kota Kinabalu, Sabah, Malaysia

## SUMMARY

Melioidosis is endemic in Sabah. It causes significant morbidity and mortality if diagnosis and treatment is delayed. Important risk factors include diabetes, chronic kidney diseases, chronic lung diseases, thalassaemia, immunosuppressive therapy, and hazardous alcohol consumption. Influenza A is usually a self-limiting disease but is associated with high morbidity and mortality in high-risk populations especially during pregnancy. Both melioidosis and influenza A commonly present in patients with pneumonia. Secondary bacterial pneumonia is a known complication in approximately one third of patients with severe pneumonia due to influenza A, resulting in intensive care unit admissions. However, melioidosis is not commonly recognized as an aetiology in secondary bacterial pneumonia complicating influenza A infection. This is important as empirical antibiotics that are used to treat secondary bacterial pneumonia due to influenza A often do not cover melioidosis. Here we report a rare case of concurrent pulmonary melioidosis and influenza A in a 30-year-old primigravida at 27 weeks of pregnancy in the Queen Elizabeth Hospital, Sabah, Malaysia to highlight the challenge in the recognition and management of both infections in a melioidosis endemic area.

## INTRODUCTION

Influenza A and melioidosis are common community acquired infections with pulmonary involvement, both with significant morbidity and mortality in pregnant patients if the treatment is delayed. A review by the World Health Organization (WHO) working group reported that the incidence of symptomatic laboratory confirmed influenza infection ranged from 0.1 per 10,000 pregnancies to 486 per 10,000 pregnancies with the incidence of ICU admission ranging from 0.01 per 10,000 pregnancies to 6.8 per 10,000 pregnancies.<sup>1</sup> With regard to melioidosis in Sabah, the incidence rate was 2.57 per 100,000 population in 2013.<sup>2</sup> Herein, we report the first case of concurrent Influenza A with pulmonary melioidosis in a pregnant lady in Sabah, Malaysia.

## CASE REPORT

A 30-year-old primigravida at 27 weeks of pregnancy presented with two days history of fever, productive cough, coryza and myalgia. She had no difficulty in breathing and also denied any history of contact with patients with

respiratory illness or animals. There was no recent history of travel. Her past medical history included hypertension and papillary thyroid carcinoma for which she had a total thyroidectomy, lymph node excision and radioiodine therapy three years prior to the current presentation. She was a housewife.

On examination, she was febrile (38°C), tachypnoeic with a respiratory rate of 28 breaths/minute with oxygen saturation of 98% on nasal oxygen 3L/min, blood pressure was 124/85mmHg and pulse rate was 90 beats/minute. Examination of the lungs revealed bilateral coarse crepitations. The rest of the physical examination was unremarkable. Blood investigations revealed WBC  $9.2 \times 10^9/L$  (predominantly neutrophils), haemoglobin of 11.9g/dL, platelet  $252 \times 10^9/L$ , and CRP was 28 mg/L. Renal and liver function tests were normal. Arterial blood gas on ambient air showed type 1 respiratory failure – pH 7.4,  $pO_2$  77mmHg,  $pCO_2$  28mmHg, and  $HCO_3^-$  18.6mmol/L. HIV test was negative. Admission electrocardiogram showed sinus rhythm and chest radiograph showed bilateral basal pulmonary infiltrates. Bedside echocardiography was normal. She was treated for severe influenza with superimposed bacterial pneumonia with intravenous ceftriaxone, azithromycin and oseltamivir.

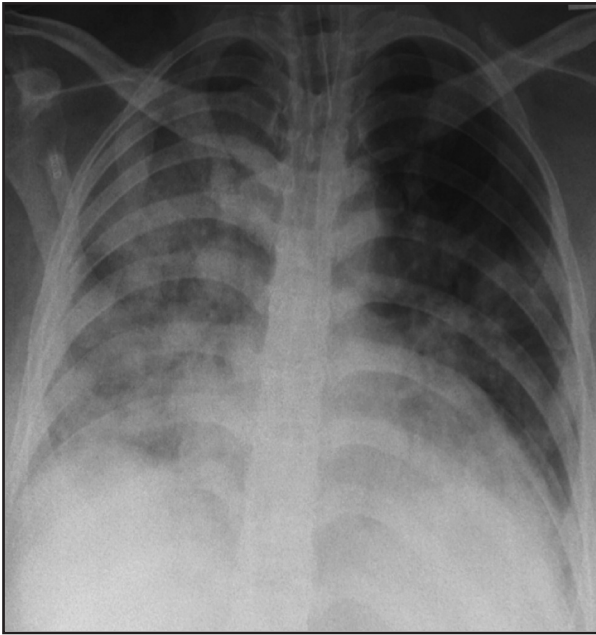
Over the next three days, her fever persisted with increasing oxygen requirement and a repeat chest radiograph (Figure 1) showed worsening pulmonary infiltrates. Antibiotics were escalated to piperacillin/tazobactam on the same day for treatment of superimposed nosocomial pneumonia. Initial sputum cultures and blood cultures were sterile. Sputum for H1N1 PCR was positive for influenza A. However, her condition continued to deteriorate, and she required mechanical ventilation on day-7 of illness. Both the chest radiograph and arterial blood gases were consistent with acute respiratory distress syndrome, and therefore a decision was made to further escalate the antibiotics to intravenous meropenem the following day. A computed tomography (CT) of the chest on day 11 of illness (Figure 2) showed ground glass opacities of both lung fields consistent with pneumonitis.

Subsequently, her fever subsided after three days of intravenous meropenem, and she was extubated on day 14 of illness. Sputum culture on day 16 of illness grew *Burkholderia pseudomallei* which was sensitive to ceftazidime, meropenem and imipenem. Sputum was inoculated on blood

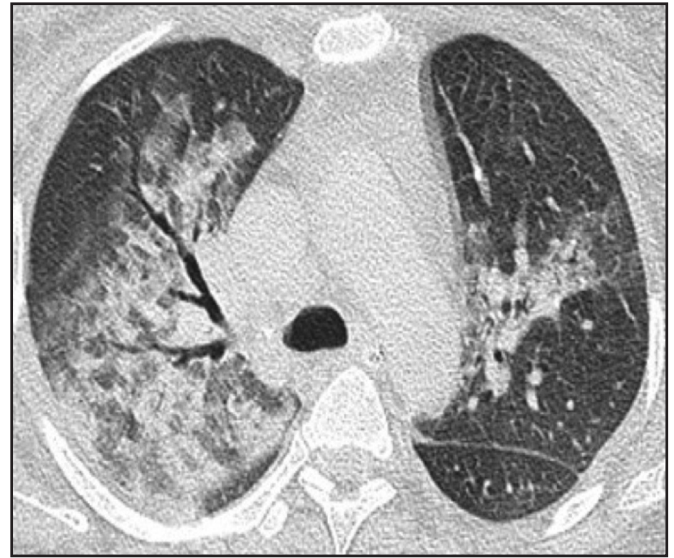This article was accepted: 17 January 2021

Corresponding Author: Heng Gee Lee

Email: henggee77@gmail.com



**Fig. 1:** Chest radiograph on day 3 of illness showed worsening opacities over bilateral lung fields.



**Fig. 2:** Computed tomography of the chest on day 11 of illness showed ground glass opacities involving both lungs, but worse on the right.

agar and MacConkey agar. Identification of *B. pseudomallei* was done with VITEK 2 compact system (BioMerieux, Lyon, France) and antibiotic sensitivity test was performed with Etest. Repeated blood culture was sterile and melioidosis serology (IgM ELISA) was negative. Antibiotics was de-escalated to intravenous ceftazidime in view of clinical improvement on day 20 of illness. Following this, she had an emergency lower segment caesarean section for foetal distress and delivered a preterm baby on day 32 of illness. She completed two weeks of intravenous ceftazidime and was discharged well after five weeks of hospital stay with oral trimethoprim/sulphamethoxazole for another three months. Both mother and child remained well in 2019, two years after discharged.

**DISCUSSION**

Influenza in pregnancy is known to cause significant morbidity and mortality. Immunological and physiological adaptations that occur in pregnancy make them particularly vulnerable to the complications. Pregnancy-associated complications include hyperthermia, low birthweight, preterm delivery, and perinatal mortality. Hyperthermia in early pregnancy is associated with neural tube defects and other congenital anomalies; and in late pregnancy is associated with neonatal seizures, neonatal encephalopathy, cerebral palsy and death.<sup>3</sup> Case series reported that about half of the influenza cases in pregnant women were complicated by bacterial pneumonia, with a quarter of them resulting in death, especially in the third trimester. Initiation of neuraminidase inhibitors within 48 hours of onset of symptoms confers a lower risk of severe disease and complications. Therefore, influenza vaccination is advocated to prevent as well as minimise the severity of the infection in pregnant women, thus improving both maternal and foetal outcomes.<sup>3</sup>

Melioidosis is a disease caused by *B. pseudomallei* and is endemic in Malaysia. Clinical manifestations range from asymptomatic carriage, chronic infection to acute disseminated bacteraemia and septicæmic shock.<sup>2,4</sup> The mode of infection include inhalation and contact via cutaneous wounds. The most common presentation is pneumonia which accounts for approximately half the number of the total cases. Impaired host defence in conditions such as diabetes mellitus, chronic kidney disease, chronic lung disease, thalassaemia, and malignancy have been implicated as risk factors for contracting melioidosis.<sup>4</sup>

Our patient had severe H1N1 influenza A complicated by pulmonary melioidosis. There are two possibilities to explain this concurrent infection. The first is that our patient had acquired both influenza A and *B. pseudomallei* at about the same time. Initial cultures were negative on admission as the melioidosis infection was probably in the incubation phase of the disease. Melioidosis serology (IgM) was likely to be a false negative result. Furthermore, it is not a routine practice to send serology for *B. pseudomallei* in Malaysia and serology is not a reliable method of diagnosis. An article by Shirley et al., reported that the sensitivity of in-house IgM ELISA was only 76.14% and IgG ELISA was a better diagnostic test. Culture remains the gold standard of diagnosis.<sup>5</sup> Another consideration would be reactivation of melioidosis from a latent focus. In the Darwin study, it was reported that about 4% (19) of 540 cases had reactivation of disease.<sup>4</sup> Latency of up to 29 years from exposure to *B. pseudomallei* to development of clinical disease, had been reported. The most common clinical presentation of reactivation was pulmonary melioidosis.<sup>4</sup> In our patient, her risk factor for acquiring melioidosis was due to environmental exposure to *B. pseudomallei* in the soil during gardening. A similar case of reactivation of melioidosis in a Vietnam veteran with acute influenza had been described. Pregnancy is not a known risk factor for melioidosis infection.

**CONCLUSION**

Influenza is frequently complicated by bacterial pneumonia, thus there should be a high index of suspicion of melioidosis as a cause of concurrent bacterial pneumonia in endemic areas as earlier empirical treatment of melioidosis will lead to better outcome.

**REFERENCES**

1. Fell DB, Azziz-Baumgartner E, Baker MG, Batra M, Beauté J, Beutels P, et al. Influenza epidemiology and immunization during pregnancy: Final report of a World Health Organization working group. *Vaccine* 2017; 35(43): 5738-50.
2. Suleiman M, Kundayis F, Polin P, Gindono J, Ed. Guideline for Clinical and Public Health management of melioidosis in Sabah. Kota Kinabalu, Sabah. Public Health Division, Sabah State Health Department 2014.
3. Rasmussen SA, Jamieson DJ, Uyeki TM. Effects of influenza on pregnant women and infants. *Am J Obstet Gynecol* 2012; 207(3): 3-8.
4. Currie BJ, Ward L, Cheng AC. The epidemiology and clinical spectrum of melioidosis: 540 cases from the 20 year Darwin prospective study. *PLoS Negl Trop Dis* 2010; 4(11): 900.
5. Hii SYF, Ali NA, Ahmad N, et al. Comparison of in-house IgM and IgG ELISAs for the serodiagnosis of melioidosis in Malaysia. *J Med Microbiol* 2017; 66(11): 1623-27.