

# First case of pulmonary hydatid cyst in a pregnant Syrian refugee woman in Malaysia

Azlin Mohd Yasin, MPH/TH<sup>1</sup>, Habib Abdul Hakim Esa, MBBS<sup>2</sup>, Ahneez Abdul Hameed, MPath<sup>2</sup>, Wathiqah Wahid, MMedSc<sup>1</sup>, Pakeer Oothuman Syed Ahamed, PhD<sup>1</sup>

<sup>1</sup>Department of Parasitology & Medical Entomology, Faculty of Medicine, Universiti Kebangsaan Malaysia, WP Kuala Lumpur, Malaysia, <sup>2</sup>Hospital Selayang, Lebuhraya Selayang, Kepong, Batu Caves, Selangor, Malaysia.

## SUMMARY

**Pulmonary hydatid cyst (PHC) in pregnancy is a very rare pathology. We report here a case of ruptured PHC during pregnancy in a 26-year old Syrian (refugee) woman who presented with complaints of productive cough with metallic taste and dyspnoea. PHC was suspected due to her clinical and radiological findings. Interestingly, the sputum examination confirmed the diagnosis as numerous protoscolecemes were present. Serology for *Echinococcus* infection revealed positive at high titre. Early diagnosis and prompt treatment by providing care improves the patient outcome. Parasitological examination of the respiratory specimen in suspected ruptured PHC is desirable as a valuable detection tool.**

## INTRODUCTION

Echinococcosis (hydatidosis or hydatid disease) is a zoonotic infection that is acquired by the ingestion of eggs from the tapeworm *Echinococcus* spp. There are several species that cause echinococcosis such as *Echinococcus granulosus* in most cases while others such as *Echinococcus multilocularis*, *Echinococcus vogeli* and *Echinococcus oligarthrus* also infect humans. Echinococcosis is rarely reported in Malaysia but is one of a major public health concerns throughout the Mediterranean region, northern Africa, and Asia region, where domesticated animals are commonly raised. In these countries, the incidence rate is about 50 per 10,000 person-years, whilst about 1 in 20,000 to 30,000 cases are reported in pregnancy.<sup>1</sup> There are only few reports of pulmonary hydatid cyst, especially in pregnant women. Thus, insufficient data is available to have guidelines based on the clinical presentations, diagnosis, and management of echinococcosis infection especially in non-endemic countries such as Malaysia. There are only two reported cases of echinococcosis from Malaysia, both involving the liver. This is the first case report of a ruptured pulmonary hydatid cyst (PHC) in a pregnant refugee lady from Syria residing in Malaysia.

## CASE REPORT

A 26-year-old Syrian lady, primigravida at 32 weeks of pregnancy; presented to the emergency department of the Selayang Hospital, Selangor, Malaysia with chief complaints of productive cough and shortness of breath for two months. She complained of experiencing oral metallic taste especially whilst coughing. There was no fever, abdominal pain,

nausea, vomiting, haemoptysis, night sweat, loss of weight or loss of appetite. She had no other previous medical illness. Social history included arrival in Malaysia two years prior to the appearance of the symptoms. She denied previous contact or travel history associated with animal hosts particularly sheep, dogs, or cattle. However, she had a twin sister who had presented with similar symptoms and was diagnosed to have large bilateral lung cysts; who was treated with anti-parasitic medication and the cysts removed surgically. On physical examination of our patient, her vital signs were stable with 95% oxygen saturation under room air. Her lungs were clear on auscultation but there was reduced breath sound on the left middle and lower zone. Other systemic examinations were unremarkable and foetal condition was stable.

During admission, her full blood count showed leukocytosis ( $13.5 \times 10^9/L$ ) with neutrophil predominant (93%). There was no anaemia, thrombocytopenia or eosinophilia. On the fourth day of admission, her eosinophilic count rose from 0.2% to 1.21%. Her chest radiograph (Figure 1A) revealed a large cavitation with thick wall on the left lung involving the mid and lower zones. There was also consolidation of bilateral lung lower zone with pleural effusion. Computed tomography pulmonary angiography (CTPA) (Figure 1B-1D) was performed which showed a large solitary cavitating lesion in the left lower lobe measuring  $9.7 \times 7.7 \times 12.3$ cm. A communication of the large cyst with lower lobe bronchiole of the left lung was observed but there was no evidence of pulmonary embolism.

The sputum test for acid-fast bacilli was negative. Parasitological microscopic examination of her sputum confirmed *Echinococcus* infection with protoscolecemes of hydatid sand present in the wet mount (Figure 2A, 2B) and with Giemsa stain (Figure 2C-2F). There were also fragments of the laminated membrane of the cyst (Figure 2E, 2F). Further diagnostic test was performed with enzyme-linked immunosorbent assay (ELISA). Serology sample for *Echinococcus* IgG antibody showed positive at a very high titre of 49.35 DU.

Thus, a diagnosis of pulmonary hydatid cyst (PHC) was made. She was started on oral albendazole and referred to a tertiary hospital with a cardiothoracic unit. She underwent induction of labour at 35 weeks. She delivered a healthy baby via forceps assisted vaginal delivery and with a plan of

This article was accepted: 05 November 2020

Corresponding Author: Wathiqah Wahid

Email: wathiqah.wahid@ppukm.ukm.edu.my

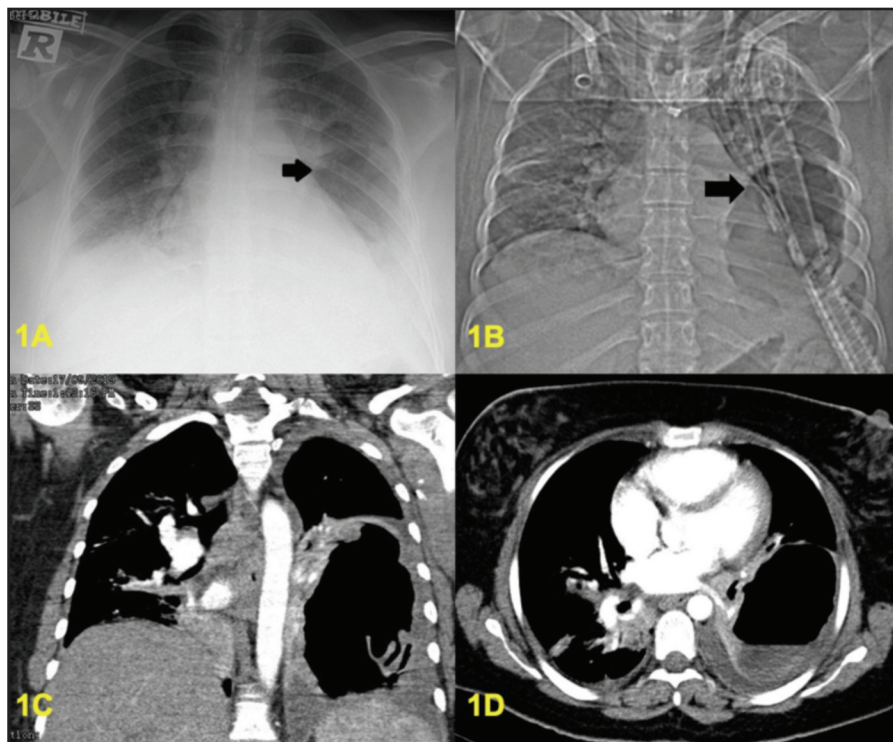


Fig. 1: A). Chest radiograph showing the large *Echinococcus* cyst in the left lung (black arrow). B,C,D). CTPA scan showing the complicated large cavitation with onion peel sign.

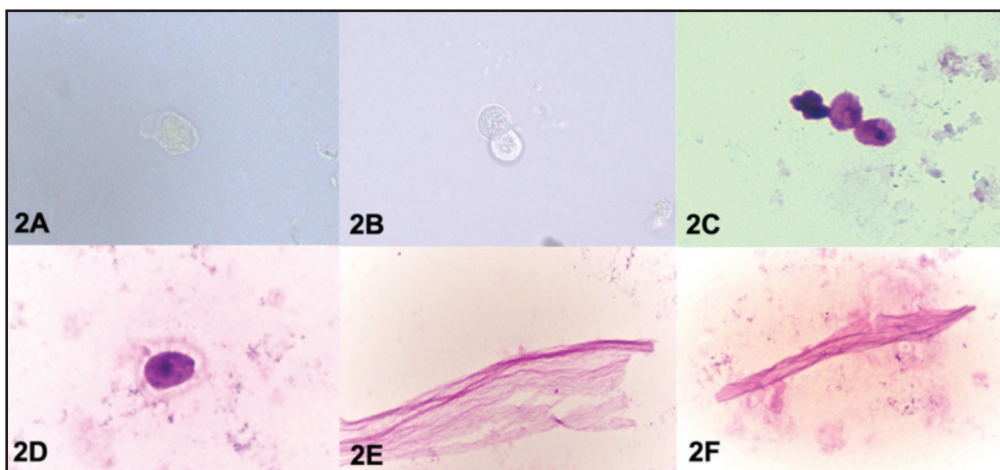


Fig. 1: A,B). Direct smear of sputum in saline showing invaginated protoscolex/protoscoleces with refractile row of hooklets/rostellum in the centre (30–45µm x 25–35µm), under x40 magnification. C,D) Giemsa stain of sputum revealed protoscolex/protoscoleces from hydatid cyst were oval measuring about 42–45µm x 30–32µm, had rostellum/hooklets in the centre, under x1000 magnification. E,F) Giemsa stain of sputum seen fragments of outer, acellular laminated membrane, remnant of the cyst wall, under x1000 and x40 magnification respectively.

surgical removal of cyst postpartum. Albendazole was administered 400mg twice daily for 28 days. Successful surgical resection of the cyst was done six months postpartum.

**DISCUSSION**

Hydatid cysts (HC) are commonly seen in the liver.<sup>2</sup> Compared to the dense liver tissue, pulmonary HC can grow swiftly and expand due to less physical resistance in the lung

tissue. Some reports state that during pregnancy, suppression of cellular immunity may cause rapid increase in parasite growth and steroids secreted from the placenta causing the cysts to enlarge.<sup>3</sup> Thus, those factors may explain the reason why the *Echinococcus* cysts grew larger and produced symptoms suddenly in our patient.

Commonly, HC is reported to enlarge steadily to approximately 1 to 5cm per year and fully mature in about 20 years or more. Most cysts do not cause any symptoms

initially in the infected person and usually takes several years to reach the size to cause clinically symptoms. In our patient, the infection perhaps had been present for decades earlier, possibly during her childhood, in the same environment as her twin sister.

The diagnosis of PHC is usually made by taking full medical history involving social background, travel history, radiographical findings of the patient and subsequently confirmed by laboratory tests. Our patient a Syrian refugee, has a twin sister with a past history of PHC. She experienced oral metallic taste, which may perhaps be a salty or peppery taste just as experienced by other patients of ruptured HC cases. Hydatidosis is defined as vomiting out of hydatid fluid through the mouth. Complication of HC such as ruptured cyst was reported seen in 27.6% of cases, but relatively rare in pregnant women. Rupture of HC may occur during pregnancy due to enlarging uterus that compresses the cyst, trauma or secondary infection. This may also be due to decreased cell mediated immunity in the patient that facilitate rapid parasitic growth of the organism.<sup>4</sup> PHC tends to rupture into the bronchus and trigger expectoration of cyst fluid, causing cough, chest pain and abdominal pain. Serious pleural complications may occur, although rare, which may become life-threatening due to anaphylactic shock.

Hydatid fluid is highly toxic and antigenic which contains acidic fluid with pH 6.7, salt, protein and colourless. Thus, spillage of the hydatid fluid into the circulation of the infected person may give rise to eosinophilia and expose the patient to risk of anaphylaxis. Fortunately, our patient did not have eosinophilia or anaphylaxis reaction when she presented to the emergency and remained stable through her pregnancy. Her initial full blood count investigation did not show any specific results. Studies showed less than 15% of HC cases present with eosinophilia and this generally occur when the cysts have ruptured. While other studies report that only 2% of cases had anaphylactic reaction,<sup>5</sup> and patients rarely had anaphylactic reaction during pregnancy. The eosinophil count of our patient rose only on the fourth day of admission which could have been due to the cysts rupturing during her admission. This complication was anticipated by the clinician as the patient was given medication to prevent anaphylactic prophylaxis and anthelmintic. Such prompt and efficient patient management does improve PHC patient prognosis.

To this date, the diagnosis of echinococcosis mainly relies on radiological findings and further supported by serological confirmation. Serological test is very helpful and is available in the form of direct haemagglutination test, immunoblot and enzyme-linked immunosorbent assay (ELISA). Only ELISA for the detection of IgG against *Echinococcus* is available in Malaysia. The antigen used in the serological test is mainly derived from protoscoleces of *E. granulosus* or *E. multilocularis*. The sensitivity is highest for infection in multiple organs (90-100%) followed by liver (85-95%) and lowest for pulmonary (50-60%). Even though so, detection of high titre in our pulmonary case was most likely due to ruptured HC.

Examination of ova and parasite in the stool of the infected patients is not diagnostic as parasite eggs are not shed by humans, since humans are the accidental dead-end host. Confirmation of *Echinococcus* via microscopy respiratory sample is not widely done. In this case study, we would like to address an interesting aspect of the diagnosis *Echinococcus* i.e. the presence of protoscoleces during microscopic examination. Diagnostic aspiration of hydatid sand from patients is seldom indicated in view of the invasiveness of the procedure and the possible risk of seeding of the hydatid. But in our case, the patient coughed out protoscoleces and we were able to diagnose by basic parasitological examination and subsequently confirmed by the serological test. Microscopic examination of the respiratory specimen in cases of ruptured HC and hydatidosis is important because the procedure is practical, non-invasive, cheap, and also diagnostic of infection. A wet unstained mount procedure is simple to perform and often adequate for confirmatory diagnosis especially if protoscoleces are seen with or without hooklets.

Furthermore, our case was more complex as the patient was pregnant at 32 weeks and thus the management was risky. Surgical treatment remains the main choice of HC disease. However, medical treatment is just as important. In our case, a combination of anthelmintic and anaphylactic medication was given. Albendazole remains the anthelmintic of choice for this disease. It can penetrate the complex cyst wall and prevents the eggs from hatching. Thus, administration of albendazole is recommended preoperatively in order to sterilise the cyst, to decrease the tension in the cyst so that there are less chances of seeding from the spillage and subsequently preventing anaphylaxis reaction. It needs to be noted that albendazole is teratogenic and not recommended to be used in the first trimester. Postoperative medical treatment for up to 30 days is recommended to reduce the high recurrence rates and hydatidosis considerably. Treatment with albendazole results in 30% resolved response rate and generally, the prognosis with anthelmintic remains varies. Some studies recommend that HC during pregnancy should be managed conservatively with courses of albendazole after the first trimester of pregnancy. Some other cases which had great prognosis and outcome treated with anthelmintic postnatally without antenatal anthelmintic course.

Surgical removal is also controversial, especially in pregnant women. When there is a potential risk and complication of the HC interfering with normal labour, delivery should be by caesarean section and, whenever possible the cysts removed later when safe. As in this case, prophylaxis against anaphylaxis during labour should be anticipated and shortening the second stage of labour can reduce the risk of rupture of HC.

#### CONCLUSION

Our case highlights the non-specific and mild clinical presentation of a ruptured PHC in a pregnant lady. Timely diagnosis and management of ruptured hydatid cysts in pregnant women will improve the prognosis. In symptomatic and cases of suspected ruptured PHC, microscopic

examination of respiratory specimen is a faster and cheaper diagnostic method to confirm the infection, especially in non-endemic countries. We recommend anthelmintic therapy during antenatal (second and third trimester) and postnatally in managing pregnant women with ruptured PHC.

#### ACKNOWLEDGEMENTS

We would like to thank the patient for kind permission to publish this case report and the staff in Hospital Selayang for their clinical management and Laboratory technicians in the Department of Parasitology & Medical Entomology, Faculty of Medicine, UKM for their laboratory technical support.

#### CONFLICT OF INTEREST

The authors declare no conflict of interest to disclose.

#### REFERENCES

1. Junghanss T, Da Silva AM, Horton J, Chiodini PL, Brunetti E. Clinical management of cystic echinococcosis: State of the art, problems, and perspectives. *Am J Trop Med Hyg* 2008; 79(3): 301-11.
2. Hayati MPS, Eugene CBT, Jin BJ, Rose IM. Chronic hydatid cyst in Malaysia: A rare occurrence. *Malaysian J Med Sci* 2015; 22(1): 79-83.
3. Kain KC, Keystone JS. Recurrent hydatid disease during pregnancy. *Am J Obstet Gynecol* 1988; 159(5): 1216-7.
4. Ekim H, Ekim M. Echinococcal tension pneumothorax in a pregnant woman. *Pakistan J Med Sci* 2009; 25(1): 159-61.
5. Ye J, Zhang Q, Xuan Y, Chen S, Ma L, Zhang Y, et al. Factors associated with echinococcosis-induced perioperative anaphylactic shock. *Korean J Parasitol* 2016; 54(6): 769-75.