

# A review of heart valve disease research in Malaysia

Paul LZ Khoo, MBBS<sup>1</sup>, Jun S Poon, MBBS<sup>1</sup>, Gerald JS Tan, MBBS<sup>2</sup>, Yahya Awang, FRCS<sup>3</sup>, KM John Chan, FRCS CTh<sup>3,4</sup>

<sup>1</sup>Newcastle University Medicine Malaysia, Iskandar Puteri, Johor, Malaysia, <sup>2</sup>The Ipswich Hospital, East Suffolk and North Essex NHS Foundation Trust, Suffolk, United Kingdom, <sup>3</sup>Cardiac Vascular Sentral Kuala Lumpur (CVSKL) Hospital, Kuala Lumpur, Malaysia, <sup>4</sup>National Heart and Lung Institute, Imperial College London, Royal Brompton Campus, Chelsea Wing, London U.K.

## ABSTRACT

**Introduction:** Heart valve disease comprises a cluster of conditions affecting the aortic, mitral, pulmonary and tricuspid valves. This paper reviews all the research on heart valve disease in Malaysia published between the years 2000-2016.

**Methods:** The methodology was based on the search process described in the paper, "Bibliography of clinical research in Malaysia: methods and brief results". The search databases included PubMed, Scopus and several Malaysian journals such as MyJurnal and UKM Journal Repository, by using the following keywords: (heart valve disease OR infective endocarditis OR rheumatic heart disease) and (Malaysia).

**Results:** In all 94 papers were identified of which 39 papers were selected and reviewed on the basis of their relevance. The local studies contributed to the knowledge and understanding of the epidemiology, aetiology, pathophysiology, clinical presentations, investigations, treatment, and outcomes of heart valve disease in the country.

**Discussion:** The clinical relevance of the studies performed in the country is discussed along with recommendations for future research.

### KEY WORDS:

*Heart valve disease; infective endocarditis; rheumatic heart disease; Malaysia*

## INTRODUCTION

Heart valve disease (HVD) is one of the leading causes of cardiovascular mortality and morbidity in the world. Rheumatic heart disease continues to be the major cause of HVD in developing nations. However, there have been recent major shifts from a rheumatic to a degenerative aetiology in developed nations.<sup>1</sup> Due to the increase in life expectancy and atherosclerotic risk factors, the risk of acquiring age-related degenerative HVD has increased significantly. The correlation between HVD with the rise of an ageing population suggests that this could potentially be the 'new cardiac epidemic'.<sup>2</sup> With the requirements for long-term follow up, substantial costs incurred for the investigations

and management, this will be a significant burden on the healthcare system in Malaysia. Hence, it is of importance to review the relevant research conducted in Malaysia with the aim of understanding the disease burden, current clinical practice and outcomes in the country.

## METHODS

This review summarises all the available publications on HVD research conducted in Malaysia from the year 2000 to 2016. The PICO (patients, interventions, comparisons, outcomes) framework for this review is detailed according to the respective inclusion and exclusion criteria in Table I.

### Literature search

A literature search was performed using methods as described in the paper "Bibliography of clinical research in Malaysia: methods and brief results" where search databases included PubMed, Scopus and several Malaysian journals such as MyJurnal and UKM Journal Repository, by using the following keywords: (heart valve disease or infective endocarditis or rheumatic heart disease) and (Malaysia).<sup>3</sup>

### Eligibility criteria

All articles had to be original research or case reports involving humans and be written in the English language whereas reviews and letters were excluded. Only articles where studies were conducted in Malaysia and specifically on HVD were included. There were no restrictions on factors such as age, ethnicity, gender or social background on the patients included in the review. Additionally, articles on methodologies and articles for which no full text was available through a license at our institutes were also excluded.

### Screening process

Initially, two reviewers (PKLZ & PJS) independently screened all the retrieved articles based on the inclusion and exclusion criteria, firstly on the title and subsequently on the abstracts. Any discrepancies in the content was then resolved after subsequent rounds of screening. After the resolution of discrepancies, full-text articles were retrieved and one reviewer (GJST) screened the full-text articles and extracted data. A final screening outcome was agreed upon after discussion with the fourth and fifth reviewers (KMJC & YA).

This article was accepted: 07 September 2020

Corresponding Author: KM John Chan

Email: KMJohnChan@yahoo.com

After the process of screening, a total of 94 articles were identified after duplicates were removed from the original search results of 140 articles. 39 articles were then selected with the agreement of all authors based on their relevance. A PRISMA flow diagram showing the selection process of articles is presented in Figure 1.

## EPIDEMIOLOGY

There were no epidemiological studies published on the incidence and prevalence of HVD in Malaysia. In a population-based study conducted in the United States of America (USA), HVD had a prevalence of 0.7% among those aged 18-44 years, compared to 13% in the 75 years and older group, showing that prevalence increases with age.<sup>4</sup>

Levin et al., conducted a 3-year review on the epidemiology of severe rheumatic heart disease (RHD) from 2010-2012 that was presented to the National Heart Institute, Kuala Lumpur found 552 patients presented with severe RHD, of which 473 patients (403 adults, 70 children) or 85.7% underwent surgical valve repair or replacement.<sup>5</sup> In this study the most commonly involved valve in the adult population was the mitral valve (90%) followed by the aortic valve (65%). There was a predominance of females among the adult surgery patients (66%).

A retrospective study conducted in the East Coast of Peninsular Malaysia had an estimated incidence of infective endocarditis of 10 cases per 100,000 per year, with the majority of cases attributed to intravenous drug use.<sup>6</sup>

## AETIOLOGY AND PATHOGENESIS

The aetiology of HVD can be categorised into congenital, degenerative, infective, immunological, functional, and neoplastic causes. A total of 20 local case reports and one retrospective observational study were reviewed, and their aetiologies are summarised below. Seven articles described aortic valves, eight studies involved the mitral valve, and the remaining two described tricuspid valve disease.

### ***Congenital***

#### *Aortic valve*

A bicuspid aortic valve is a form of congenital heart anomaly, in which there are two aortic cusps instead of three. In congenital bicuspid valves, this predisposes the patients to both aortic stenosis and aortic regurgitation.<sup>7</sup> Two local case reports describe three patients with bicuspid valves complicated with aortic regurgitation. Kim et al., described infective endocarditis as a cause of aortic regurgitation in a patient with bicuspid valve. In contrast, Ngaw et al did not identify a definitive mechanism for aortic regurgitation in patients with bicuspid valves in their study. However, the author did suggest possible mechanisms such as prolapse of the larger unequal cusp, infective endocarditis, and secondary aortic pathologies.<sup>8,9</sup>

#### *Mixed heart valve*

In another congenital anomaly, chromosomal in nature, a case report by Tamin et al. describes a patient with Turner syndrome who was diagnosed with subvalvular aortic

stenosis at age seven.<sup>10</sup> When the patient was aged 20, transthoracic echocardiography demonstrated aortic regurgitation due to left ventricular outflow tract obstruction by an accessory mitral valve leaflet.

### ***Degenerative***

#### *Aortic valve*

Degenerative aortic valve disease is comparable to all degenerative pathology and it is a disease due to the process of ageing. This degenerative process involves aortic valve calcification and the resulting consequence is reported in a local case report that describes a patient with severe calcific trileaflet aortic valve that led to aortic valve stenosis.<sup>9</sup>

#### *Mitral valve*

A Malaysian article reported Barlow's disease, one of the two main types of degenerative mitral valve disease, with the other being fibroelastic deficiency.<sup>11</sup>

### ***Infection***

Infective endocarditis (IC) is an infection of the innermost layer of the heart (endocardium), which usually involves the heart valves. Seven local cases described the typical and rare organisms implicated in IC. According to these studies, the typical organisms such as *Staphylococcus aureus* and *Streptococcus viridans* were isolated and identified in patients with various risk factors. However, infection with other organisms such as *Bacillus cereus*, *Klebsiella pneumoniae*, *Providencia stuartii*, and candida were also reported. It is essential for physicians to be aware of the common and various organisms involved in infective endocarditis in Malaysia to ensure that effective antimicrobial treatment in accordance to clinical practice guidelines is used for management.

There were also case reports of IC involved in the various heart valves (four mitral valves, two aortic valves, and one case involving mixed valves), which had led to valve regurgitation and incompetency via tissue destruction and vegetation formation.

Patients in these local case reports had various risk factors for IC. In these patients the modifiable risk factors present were intravenous drug use and poor dentition, while non-modifiable risk factors were tooth extraction, hemodialysis, and rheumatic heart disease. The healthcare teams in Malaysia play a vital role in reducing these risk factors through patient education and preventive interventions.<sup>12-18</sup>

### ***Immunological***

Wong et al., described a case of chronic rheumatic heart disease, a long-term complication of rheumatic fever. Antigenic mimicry, the hallmark pathogenesis in rheumatic fever, had led to permanent lesions of both aortic and mitral valves of the patient resulting in severe aortic and mitral regurgitation.<sup>19</sup>

### ***Functional***

A multicentre retrospective study in Malaysia entailed surgical outcomes for functional mitral valve disease. The study population showed that patients with this disease had a high incidence of previous ischaemic heart disease and its

risk factors such as chronic kidney disease, hyperlipidemia, and diabetes mellitus.<sup>20</sup> These findings suggest the role of myocardial ischaemia in the pathogenesis of functional mitral valve disease.

### Neoplasia

#### *Marantic endocarditis affecting the aortic valve*

A case study reported a 68-year-old woman with underlying Stage IV lung adenocarcinoma who had presented with a neurological deficit. She was noted to have non-infectious thrombin vegetation measuring 7cm x 6cm on the non-coronary cusp of the aortic valve with evidence of mild aortic regurgitation. The case described a typical presentation of marantic endocarditis, a non-infectious lesion of the heart valve that is most commonly seen in advanced malignancy due to its hypercoagulable state.<sup>21</sup>

#### *A primary tumour affecting the mitral and tricuspid valve*

In Malaysia, three case reports of rare primary heart tumour have been described. These primary tumours had affected the function and integrity of the heart valve via various mechanisms, i.e., indirect obstructive effect or direct involvement of the heart valve. Harris et al reported a 67 years old female with atrial myxoma, a rare condition reported amongst the Asian population. The progressive growth of the atrial myxoma had led to mitral valve obstruction and subsequently acute cardiac failure.<sup>22</sup>

Two other case studies described the direct involvement of the heart valve by papillary muscle tumours. Murty et al demonstrated a case of papillary cystic tumour in a Burmese migrant in Malaysia while The Heart and Lung Centre of University Kebangsaan Malaysia reported a case of papillary fibroelastoma, both of which represent extremely rare primary tumours of the heart valve.<sup>23,24</sup>

#### *A secondary tumour affecting the mitral and tricuspid valve*

Abdullah et al reported a case of cardiac metastasis in a 46-years-old man. He presented with heart failure symptoms and further investigations revealed cardiac infiltration with tricuspid valve involvement, secondary to large B-cell lymphoma.<sup>25</sup>

#### *Mimics of cardiac neoplasia*

An interesting local case report described a 54-years-old Malay man with mitral stenosis and biatrial mass which mimicked myxoma or other tumours. The patient declined surgical intervention and anticoagulation was initiated. Surprisingly, during the follow-up, echocardiography revealed regression of the mass. This suggested that the biatrial mass is thrombi secondary to mitral stenosis.<sup>26</sup>

## CLINICAL PRESENTATION

A total of 11 case reports described the clinical features of HVD that were noted in several Malaysian patients. The clinical presentation of these cases is explored according to the aetiologies, type of valves and their respective lesions, and complications.

## Clinical features of heart valve disease: Aetiologies

### *Infective endocarditis*

Clinical features of IC in five Malaysian case reports will be explored to describe and differentiate the typical and atypical presentations of infective endocarditis.

Three local case reports demonstrated a typical clinical picture of an infective endocarditis affecting the aortic and mitral valves. These patients had a prolonged history of vague constitutional symptoms such as fever, chills and generalised muscle aches with an auscultated heart murmur. On cutaneous examination, the authors noted vascular and immunological phenomena of infective endocarditis, such as Osler nodes, Janeway lesions, necrotic distal extremities, and splinter hemorrhages.<sup>13,14,16</sup> Thorough cardiovascular and cutaneous examination are essential in patients with prolonged non-specific constitutional symptoms to rule out life-threatening IC.

In comparison, another Malaysian case report reported a rare and atypical case of endocarditis due to *Bacillus cereus* affecting a native aortic valve. The patient presented with features of decompensated congestive cardiac failure without typical constitutional symptoms or stigmata of infective endocarditis. Such a case is rarely observed with an occasional presentation within the Malaysian community.<sup>12</sup>

In addition, Tan et al described another atypical presentation of IC, which was misdiagnosed as pyelonephritis in a pregnant lady during her first trimester. She presented with classical features of pyelonephritis such as fever, vomiting, back pain, tender left loin, and microscopic haematuria. However, empirical antibiotic therapy for pyelonephritis failed to resolve the symptoms. Despite the absence of heart murmur, echocardiography had detected vegetation at the mitral valve, thus empirical infective endocarditis treatment was initiated. Due to the delayed diagnosis and treatment, an infective-vegetative embolus resulted in an ischaemic stroke, a common and fatal complication of infective endocarditis. The authors discussed with regards to the initial phase of infective endocarditis, 24% did not have an audible heart murmur.<sup>18</sup> This could be attributed to the absence of significant valve regurgitation in the early stages. Additionally, features such as back pain and tender left loin could be ascribable to epidural abscess secondary to the infective emboli, while the microscopic haematuria might be due to glomerulonephritis secondary to infective endocarditis. Swift recognition and treatment of these atypical and occult presentations by the physicians is vital in preventing irreversible cardiovascular and neurological complications.

### *Rheumatic heart disease*

There were no articles from Malaysia describing the typical clinical features of rheumatic heart disease which are well recognised such as pancarditis, Sydenham's chorea, migratory polyarthritis, erythema marginatum, and subcutaneous nodules.

### **Clinical features of heart valve disease: Type of valves and their respective lesions**

Based on six case reports, clinical features specific to aortic and mitral valves is explored below according to the type of lesions such as regurgitation or stenosis.

#### *Aortic valve disease*

A case report described the classic clinical signs of aortic regurgitation such as collapsing pulse, soft second heart sound, and an early diastolic murmur heard best at the lower left sternal edge.<sup>12</sup>

Another case study described a patient exhibiting two of the three classical triads of aortic stenosis, namely angina, and dyspnoea. The patient denied having syncope, the third classical triad. On auscultation of the chest, a harsh ejection systolic murmur was heard over the aortic region, radiating to the neck.<sup>9</sup>

#### *Mitral valve disease*

Choon et al presented a case of mitral regurgitation with classical harsh pansystolic murmur heard loudest at the apical region. However, other typical signs such as radiation of the murmur towards the axilla, soft S1, and S3 were not noted.<sup>17</sup>

Another Malaysian study entailed a case of mitral stenosis with secondary pulmonary arterial hypertension. On chest palpation and auscultation, there were typical findings of mitral stenosis such as a loud S1 and apical mid-diastolic murmur. However, there were no signs of malar flush, which represents a red discolouration of the cheeks due to carbon dioxide-mediated vasodilation secondary to pulmonary congestion.<sup>16</sup>

An enlarged left atrium is a typical finding in mitral valve disease. Two local cases describe compressive symptoms secondary to grossly enlarged left atrial such as dysphagia (compression of the oesophagus), hoarseness of voice (compression of recurrent laryngeal nerve), cough, and dyspnoea (compression of airway, i.e., trachea and bronchus).<sup>27,28</sup>

#### *Tricuspid valve disease*

There were no articles that described the classical features specific to tricuspid valve lesions such as jugular vein distention with giant V wave and pulsatile tender hepatomegaly.

### **Clinical features of heart valve disease: Complications**

#### *Congestive heart failure*

Four case reports described unfortunate cases of aortic, mitral, and tricuspid valve disease that were complicated with congestive cardiac failure. The presenting complaints were symptoms of congestive cardiac failure such as dyspnoea, reduced exercise tolerance, cough, chest pain, and leg oedema. Features of poor renal perfusion and resultant fluid overload secondary to the overactive renin-angiotensin-aldosterone axis were manifested as reduced urine output, leg swelling, elevated jugular venous pressure, and features suggestive of pulmonary oedema such as fine crepitations over the lung bases.<sup>8,12</sup>

#### *Neurological signs and symptoms*

Five Malaysian case reports described the neurological complications of aortic and mitral valve disease, and four of them were cases of IC, while one described marantic endocarditis. Heart valve vegetation is described as abnormal growth and is often associated with endocarditis. Such patients are predisposed to embolic stroke as these abnormal growths lack structural integrity and are prone to detach, thus forming life-threatening emboli. Table II summarises the neurological signs and symptoms, ranging from mild deficits to debilitating and life-threatening events, as entailed in the case reports above.<sup>13,16,18,21</sup> Early recognition of the neurological manifestations in patients with heart valve disease may allow prompt and accurate diagnosis, management and better prognosis.

### **INVESTIGATIONS**

Three experimental and one prospective international multicentre study explored the investigations of HVD. The discussion below will be based on the gold standard investigation, echocardiography, and other novel investigations.

#### ***Echocardiography role in the management of heart valve disease***

Echocardiography plays a pivotal role in the management of HVD. The role of echocardiography will be explored in terms of diagnostic function, contribution to pre- and intra-operative investigations, and prognostication of aortic valve disease. The accuracy of echocardiography will also be discussed to understand its reliability in clinical practice.

#### ***Diagnostic role of echocardiography in heart valve disease***

The previous local case reports provided their perspectives on the importance and contribution of two-dimensional transthoracic and transoesophageal echocardiography in facilitating the diagnosis of heart valve disease in Malaysia. The Department of Bioengineering, University of Malaya conducted a study involving the development of a registration framework to facilitate the fusion of two-dimensional echocardiography of the aortic valve with pre-operative cardiac CT volumes. The fusion of the two imaging modalities will facilitate the diagnostic process of aortic valve disease.<sup>29</sup>

#### ***Pre-and intra-operative role of echocardiography in heart valve disease***

In addition, the fusion of the echocardiography and cardiac CT could also provide invaluable intra-operative guidance during transcatheter aortic valve replacement. The proposed image registration method consisting of two main steps, temporal synchronization, and spatial registration, has been applied to the parasternal short and long axis views in ten patients. The accuracy of the automated registration method by the authors is comparable to the gold standard manual registration, with an accuracy of  $0.81 \pm 0.08$  and  $1.30 \pm 0.13$  mm in terms of Dice coefficient and Hausdorff distance for the short-axis aortic valve view registration and  $0.79 \pm 0.02$  and  $1.19 \pm 0.11$  mm for the parasternal long axis view. There was no significant difference in the measurement of the aortic annulus dimension between the automatically and manually registered CT images. The accurate pre-operative



assessment of the aortic annular dimension measurements is essential for a successful catheter-based surgery as any erroneous sized prosthesis could lead to fatal complications. Therefore, the authors successfully demonstrated the potential application of the proposed registration framework for effective fusion of echocardiography and cardiac CT to aid transcatheter aortic valve replacement and implantations.<sup>29</sup>

#### **Prognostication of heart valve disease**

A prospective international multicentre study (17 sites in nine countries), where one of the centre was the National Heart Institute Malaysia (NHIM), was conducted to determine whether echocardiographic findings can predict the prognosis of left-sided native valve S. aureus infective endocarditis (LNIE). The study found intracardial abscess to be an independent echocardiographic predictor of both in-hospital and one-year mortality in such patients. Additionally, left ventricular ejection fraction less than 40% and valve perforation were independent echocardiographic predictors for in-hospital and one-year mortality respectively.<sup>30</sup> Therefore, identification of these independent echocardiographic prognostic markers and subsequent escalation of the management plan in such patients with LNIE, would lead to more favorable outcomes.

#### **The accuracy and reproducibility of echocardiography findings in heart valve disease**

An international collaborative study, which involved University Malaya, was conducted to determine the reproducibility of infective endocarditis echocardiographic variables using echocardiograms from subjects enrolled in the international collaborative registry. The reproducibility of the variables was reflected by intra- and inter-observer agreements. Statistical analysis indicated excellent intra-observer agreement for left ventricular ejection fraction. In terms of infective endocarditis categorical echocardiographic variables, intra- and inter-observer agreements were best for aortic abscess and vegetation location respectively, while vegetation mobility had the lowest inter-observer agreement. The moderate to excellent intra- and inter-observer agreements, reflected the reproducibility and therefore accuracy of echocardiography in the diagnostic assessment of infective endocarditis.<sup>31</sup>

#### **Novel investigations**

Heart murmurs are normally detected via chest auscultation and confirmed by echocardiography. However, echocardiography is not widely available in the rural areas in Malaysia and requires technical expertise. The specificity and sensitivity of chest auscultation are low and are largely user dependent. Various audiology studies were conducted to automatically distinguish normal heart sounds from abnormal heart sounds with murmurs. Fatemah et al conducted a study to evaluate the role of proposed wavelet packet entropy in the analysis and classification of various heart sounds. The data set collected from auscultation training material had comprised of 350 heart sounds which were divided into five categories: 50 normal heart sounds, 80 mitral regurgitation murmur, 100 aortic stenosis murmur, 50 aortic regurgitation murmur, and 70 mitral stenosis murmur. The analysis managed to achieve results with an accuracy of up to 96.94%. The promising results suggest the effectiveness

of the proposed wavelet packet entropy in the classification of heart sounds.<sup>32</sup> Similarly, another Malaysian experimental study attempted to ascertain the accuracy of stethoscopes based on Mel-frequency cepstral coefficient-hidden Markov model (MFCC-HMM) in the diagnosis of heart sounds and murmurs. Based on the proposed methods, the experiment was successful with an accuracy of 98.9%.<sup>33</sup> Therefore, the clinical applicability of both the novel devices to detect and confirm heart murmurs could potentially reduce the incidence of missed diagnoses or incorrect diagnoses in HVD.

#### **SURGICAL INTERVENTION IN HEART VALVE DISEASE**

This section will explore the surgical interventions in heart valve disease based on seven retrospective research studies, two case reports, and an article which discuss leaflet augmentation procedures. The discussion entails the techniques, procedures, and outcomes of heart valve surgery in Malaysia.

##### ***Trans-septal approach versus the standard left atriotomy***

A study carried out in Penang Hospital, compared the effectiveness of a trans-septal approach in mitral valve surgery against conventional left atriotomy. Concomitant procedures included aortic valve replacement and repair, tricuspid annuloplasty and coronary artery bypass grafting. In terms of the New York Heart Association (NYHA) class, all patients had NYHA class I and II during the follow-up for the first 18 months. The authors suggested that the trans-septal approach to the mitral valve is superior to the standard left atriotomy in selected patients that require mitral valve surgery such as those undergoing repeat surgery and who requires concomitant tricuspid valve surgery.<sup>34</sup>

##### ***Mitral valve repair for congenital valve disease in children: "Is biodegradable ring superior to non-ring annuloplasty techniques?"***

Standard commercial annuloplasty rings are not usually used in young children who require mitral valve repair due to the lack of availability of small-sized rings and increased risk of valve dysfunction due to fibrous tissue overgrowth. Two types of annuloplasties, biodegradable rings and non-rings are alternatively available for such cases. Azhari et al conducted a single centre retrospective non-randomised study which compares biodegradable ring and non-ring annuloplasty for congenital valve disease repair in 68 children. At a median follow-up of 3.8 years, freedom from valve failure and reoperation were significantly better in those with the biodegradable ring (90% and 100% respectively) compared to the non-ring annuloplasty group (74% and 84% respectively,  $p < 0.05$ ). Mitral valve repair using the biodegradable ring was found to be superior to non-ring annuloplasty repair techniques.<sup>20</sup>

##### ***The mitraclip Asia Pacific registry***

A multicentred retrospective study that also involved Malaysia was conducted to evaluate the use of MitraClip therapy for percutaneous edge-to-edge repair in 163 patients with degenerative and functional mitral regurgitation. The following data were extracted and analysed post-surgery: heart failure symptoms and echocardiographic evaluation, one-month outcome in terms of survival and major

**Table I: Patients, interventions, comparisons and outcomes (PICO) framework**

	<b>Inclusion criteria</b>	<b>Exclusion criteria</b>
<b>Patients</b>	Studies on patients in Malaysia with heart valve disease	Studies on patients in international countries with heart valve disease
<b>Interventions</b>	Any medical or surgical intervention treating heart valve disease	Any adjunct treatment methods treating non-valvular heart disease
<b>Comparisons</b>	Treatment interventions performed with in Malaysia	Treatment interventions performed outside of Malaysia
<b>Outcomes</b>	Not applicable	Not applicable

**Table II: Neurological manifestation of cardiogenic emboli**

<b>Authors</b>	<b>Arterial territory affected</b>	<b>Neurological symptoms and signs</b>
Choon, et al. <sup>17</sup> and Anuradha, et al. <sup>16</sup>	Left and right middle cerebral arteries respectively	Two cases of unilateral muscle with upper motor neurone features.
Choon, et al. <sup>17</sup>	Left middle cerebral artery territory	Expressive dysphasia
Choon, et al. <sup>17</sup>	Left middle cerebral artery territory	Incontinence
Mei, et al. <sup>21</sup>	Occipital artery territory	Visual blurring on the right eye attributed to right homonymous hemianopia
Mei, et al. <sup>21</sup>	Posterior circulation territory	Diplopia with right-sided nystagmus on looking to the right
Choon, et al. <sup>17</sup>	Left middle cerebral artery territory	Acute confusion and reduce conscious level with a low Glasgow Coma Scale (E3V2M5)
Tan, et al. <sup>17</sup>	Basilar artery territory	Generalized tonic-clonic seizures secondary to hydrocephalus
Kuan, et al. <sup>22</sup>	Right middle cerebral artery territory	Two cases of fatal stroke

**Table III: Indications for tricuspid leaflet augmentation**

<b>Procedure</b>	<b>Indication</b>
Anterior leaflet augmentation	The vertical height of anterior leaflet < 26mm or leaflet area < 26mm annuloplasty ring sizer.
Posterior leaflet augmentation	Severe posterior leaflet retraction

complications, and acute procedural success. In terms of patients' safety, the 30-day mortality rates were 4.5% and 6.7% for functional and degenerative mitral regurgitation, respectively. There were significant improvements based on the symptoms (quantified using the NYHA classification) and echocardiographic findings (significant improvement in the severity of mitral regurgitation, reduction in left ventricular end-diastolic and end-systolic diameters).<sup>35</sup>

**Leaflet augmentation in rheumatic mitral valve regurgitation**

The repair of type IIIa mitral regurgitation secondary to rheumatic heart disease poses a challenge to surgeons due to leaflet surface restrictions. To overcome this limitation, leaflet augmentation procedures with autologous pericardium will increase the surface area to aid coaptation, therefore potentially improving the surgical outcome. An article discussed the indications, safeguards, pitfalls, and techniques of leaflet augmentation in rheumatic heart valve regurgitation at the NHIM.<sup>36</sup> Table III shows the suggested indications of tricuspid leaflet augmentation. The authors also emphasised that the final dimension of the anterior leaflet post-leaflet augmentation determines the annuloplasty ring size. In posterior leaflet augmentation, one could erroneously determine the size of the annuloplasty ring based on the entire annular dimension instead of the suggested anterior leaflet dimension, resulting in an oversized prosthetic ring.<sup>36</sup> Another article evaluated the

outcomes of leaflet augmentation procedure in 62 patients with rheumatic heart disease from this centre. The procedure resulted in excellent early and late outcomes (mean follow up was 36.5±25.6months) with no major complications or mortality.<sup>37</sup>

**OUTCOME AND COMPLICATIONS OF HEART VALVE SURGERY**

**Comparison of the outcome between rheumatic and degenerative heart valve repair in adults**

Two retrospective studies conducted at the NHIM discussed the long-term outcomes of mitral valve repair for rheumatic heart disease based on in-hospital mortality, late mortality, and durability (incidence of reoperation and valve failure). In-hospital and late mortality values were 2.4% and 0.3% respectively. The durability of rheumatic heart disease valve repair, which is perceived to be lower, was compared with the well-known outstanding durable degenerative valve repair. Statistical analysis showed no significant difference between the durability of both types of valve repair, suggesting improvement in the durability of mitral valve repair as it is comparable to the more durable degenerative valve repair. Predictors of reduced durability, determined by Logistic and Cox regression analyses, were found to be commissurotomy procedure and residual mitral regurgitation greater than 2+.<sup>38,39</sup>

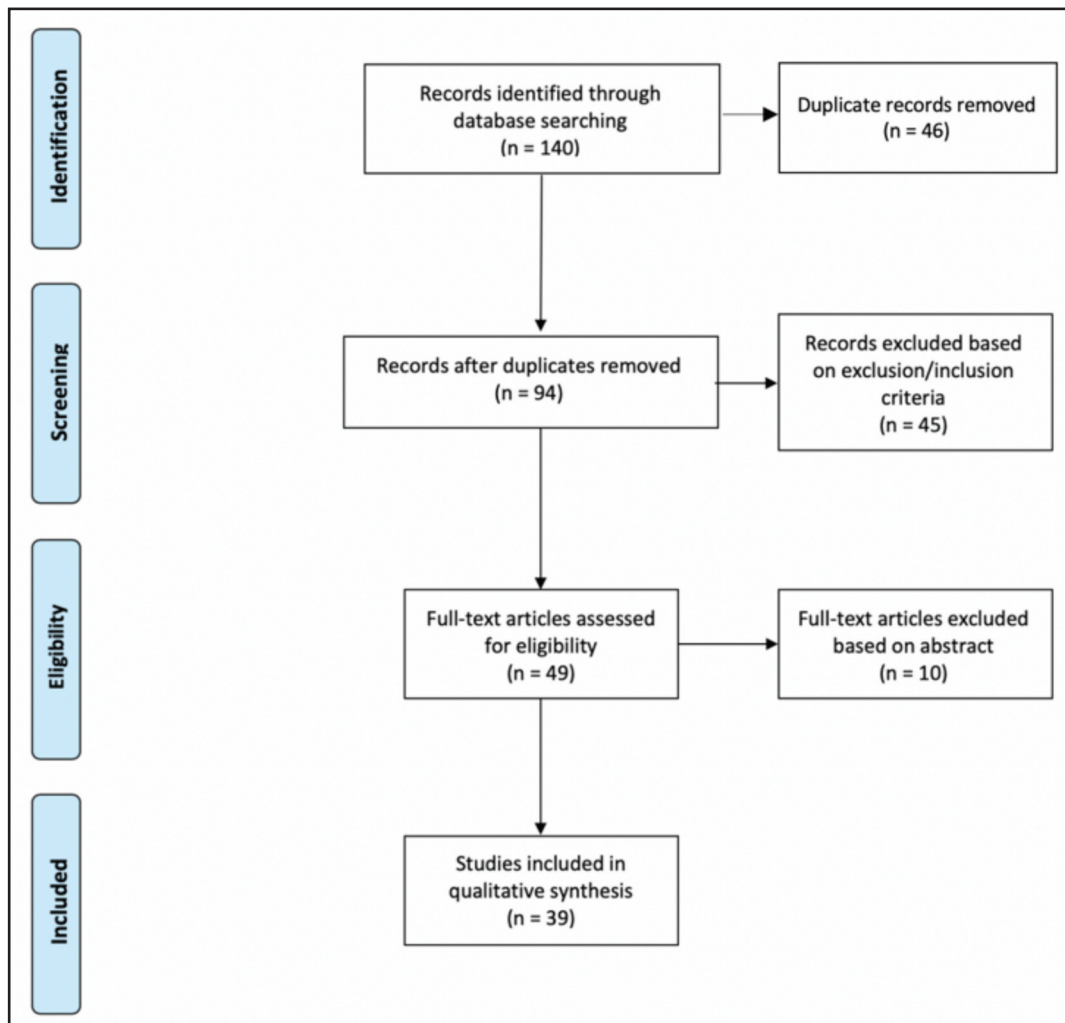


Fig. 1: PRISMA flow diagram illustrating the selection process of articles.

### **Comparison of the outcome between congenital and acquired heart valve repair in children**

Another retrospective study conducted at the NHIM reviewed 634 children who underwent mitral valve repair. The objectives were to assess the outcomes of mitral valve repair in the children sample while making a comparison between the outcomes of repaired congenital (43%) and acquired (57%) mitral valve lesion. Generally, early and late mortality values were 2% and 4% respectively. 56 patients needed reoperation, while all survivors had no pacemaker insertion, symptomatic features of heart failure, or thromboembolic events. There was no significant difference in the 10-year survival and rate of freedom from reoperation between those with repaired congenital and acquired mitral valve lesions. Hence, modified and aggressive surgical repair techniques can be applied as effective definitive treatment for congenital and acquired mitral valve lesions in children for better outcome and prognosis.<sup>40</sup>

### **“Does the duration of myocardial ischaemia adversely affect the postoperative outcome in left sided valve replacement?”**

During a heart valve replacement, aortic cross clamping will lead to some degree of myocardial ischaemia. Prolonged duration of myocardial ischaemia could potentially have

adverse effects on the postoperative cardiac function. An observational study by University Kebangsaan Malaysia Medical Centre involving 44 patients was conducted to determine the effect of myocardial ischaemia duration on the left ventricular ejection fraction six months after mitral or aortic valves replacement. Statistical analysis indicated no significant correlation between the aortic cross-clamping time and the six month- postoperative left ventricular ejection fraction. Therefore, in this local study, the duration of myocardial ischaemia during mitral or aortic valve replacement had no significant adverse effects on postoperative outcomes such as ejection fraction.<sup>41</sup>

### **Mechanical heart valve obstruction as a complication of heart valve replacement**

Pau et al reviewed data from the Cardiothoracic Department of Kuala Lumpur General Hospital and the NHIM between 1982 and 1992. Out of 2970 patients who underwent heart valve replacement, eight patients presented with features of cardiac failure or haemodynamic instability. The mean duration from heart valve replacement to presentation was 2.5 years. Future investigation of these patients, with transthoracic and transoesophageal echocardiography, revealed mechanical valve obstruction. There were seven

patients with mitral valve obstruction and one with aortic valve obstruction. Out of the eight patients, four had poor anticoagulation status. Therefore, a thorough assessment of patients' INR and compliance is crucial in preventing such complications. In terms of treatment and its outcome, seven patients underwent redo valve replacement while one patient was treated conservatively. Unfortunately, the patient with conservative treatment and one patient who underwent delayed redo valve replacement did not survive. Clinicians must have adequate knowledge and awareness of this post-operative complication to enable swift detection and treatment for better prognosis and outcome.<sup>42</sup>

#### **Early and late complications of post heart valve replacement and Ross operation**

A case study reported a 79 years old gentleman with anaemic symptoms two months post mechanical aortic valve replacement. Further investigations revealed marked haemolytic anaemia with a haemoglobin of 80g/l. Paravalvular aortic regurgitation, a common postoperative complication, was identified to be the cause of the haemolysis. The defect was successfully repaired percutaneously with a vascular plug under fluoroscopic and echocardiographic guidance.<sup>43</sup>

Another case reported a 48-year-old woman with a past surgical history of a Ross operation twelve years ago. The Ross operation is a procedure to replace the pathological aortic valve with an autologous pulmonary valve. She displayed symptoms of heart failure and further investigations had revealed severe aortic regurgitation with incomplete coaptation and mild dilatation of the aortic root. She subsequently underwent an aortic valve replacement to repair the secondary aortic root disease, a late complication of Ross operations.<sup>44</sup>

#### **RELEVANCE OF FINDINGS FOR CLINICAL PRACTICE**

This review of research studies published in Malaysia on HVD has provided a useful insight on the epidemiology, aetiology, clinical presentation, management and outcomes of this condition in the country. The identification of rheumatic heart disease as a major cause of heart valve disease in the country is important and suggests the need for better efforts towards reducing and eradicating this disease in Malaysia. The various case reports of the different presentations of HVD is useful as a reminder to the clinician to consider this in the differential diagnosis.

Various surgical techniques and procedures to treat HVD were published, some of which were novel. Publication of these studies is useful to the cardiothoracic surgical community to expand the surgical armamentarium to treat this challenging condition. The improved results with surgery should hopefully encourage more surgeons to explore these newer techniques. At the same time, studies on the complications from heart valve surgery should remind clinicians that these patients require continued care for many years after their surgery to ensure freedom from valve related complications.

#### **FUTURE RESEARCH DIRECTION**

The relatively few numbers of research studies published in Malaysia on HVD underlies the need for more research in this area. Only 39 research studies on HVD were published from Malaysia in the last 16 years. A majority of the research (n=22) were case reports. Further studies are necessary to investigate the aetiologies, risk factors, clinical presentations, management and outcomes of heart valve disease in the country.

Rheumatic heart disease remains a major cause of HVD in Malaysia, particularly in the less developed regions of the country. Studies are essential to determine the cause of this and how it can be reduced and eradicated. Studies are also required to determine if screening for HVD in these regions of the country could help lead to earlier diagnosis and treatment, and better outcomes for the patient.

Interesting and novel techniques for heart valve repair for rheumatic heart valve disease have been published in Malaysia. Further research on this area, in particular on the long-term outcomes and comparison with the more conventional heart valve replacement surgery is needed. The choice of heart valve prosthesis also needs further study particularly as the life expectancy in Malaysia is different compared with developed countries, and compliance with medications and access to regular blood tests may not be as good. The optimal timing of surgery for rheumatic heart valve disease also needs to be studied further. In this regard, it is hoped that useful information can be obtained from the National Cardiovascular and Thoracic Surgical Database (NCTSD) registry.

#### **REFERENCES**

1. Manjunath CN, Srinivas P, Ravindranath KS, Dhanalakshmi C. Incidence and patterns of valvular heart disease in a tertiary care high-volume cardiac center: a single center experience. *Indian Heart J* 2014; 66(3): 320-6.
2. d'Arcy JL, Prendergast BD, Chambers JB, Ray SG, Bridgewater B. Valvular heart disease: the next cardiac epidemic. *Heart* 2011; 97: 91-3.
3. Teng CL, Zuhannariah MN, Ng CS, Goh CC. Bibliography of clinical research in malaysia: methods and brief results. *Med J Malaysia* 2014; 69: 4-7.
4. Nkomo VT, Gardin JM, Skelton TN, Gottdiener JS, Scott CG, Enriquez-Sarano M. Burden of valvular heart diseases: a population-based study. *Lancet* 2006; 368(9540): 1005-11.
5. Levin B, Solong M, Jaffar N, Safari S, Ramli M, Rosli M. Epidemiology and Clinical profile of severe rheumatic heart disease in malaysia. *Cardiol* 2014; 128(2): 114.
6. Yousuf RM, How SH, Fauzi AR, Shah A. Infective endocarditis in the East coast of peninsular Malaysia: A two year retrospective survey from Kuantan. *JK Pract* 2006; 13(1): 5-8.
7. Michelena HI, Prakash SK, Della Corte A, Bissell MM, Anavekar N, Mathieu P, et al. Bicuspid aortic valve: identifying knowledge gaps and rising to the challenge from the International Bicuspid Aortic Valve Consortium (BAVCon). *Circ* 2014; 129(25): 2691-704.
8. Ngow HA, Wan Khairina WMN. Undiagnosed Bicuspid Aortic Valve: A Silent Danger. *Int Med J Malays* 2012; 11(2).
9. Ling PK. Pulmonary artery aneurysm associated with severe degenerative aortic stenosis. *Singapore Med J* 2009; 50(10): e350-e352.
10. Tamin SS, Dillon J, Aizan K, Kadiman S, Latiff HA. An accessory mitral valve leaflet causing left ventricular outflow tract obstruction and associated with severe aortic incompetence. *Echocardiogr*, 2011; 29(2): E34-E38.
11. Mohd AA, Simon V, Taweesak C, Abdul IR. Barlow's Repair: Light in the Dark Tunnel: A Case Report Could Omit 'Light in A Dark Tunnel'. *Med J Malaysia* 2015; 70(2): 106-7.
12. Ngow HA, Khairina WW. Bacillus cereus endocarditis in native aortic valve. *J Infect Chemother* 2013; 19(1): 154-7.



13. Yew KL, Razali F. Florid peripheral stigmata of staphylococcus aureus infective endocarditis. *Acute Card Care* 2015; 17(2): 32-2.
14. Chiam KH, CT AH, Low LL. A forgotten clinical sign making a comeback. *Med J Malaysia* 2014; 69(1): 40-1.
15. Balakrishnan S, Aamar A, Rhee S, Zakaria S, Khaliq W. Gram-negative infection as an unusual cause of endocarditis in a hemodialysis patient. *Med J Malaysia* 2016; 71(3).
16. Anuradha S, Agarwal SK, Prakash A, Singh NP, Kaur R. Candida sake—A rare cause of fungal endocarditis. *Med J Malaysia* 2008; 63(1): 75.
17. Ng CS, Mohamad S, Maskon O. Medical therapy of a left-sided native valve endocarditis with neurologic sequela. *Saudi Med J* 2015; 36(6): 743.
18. Tan HJ, Rabani R, Noorfaizan S. Infective endocarditis in pregnancy complicated by septic embolization to the cerebellum. *Med J Malaysia* 2007; 62(3): 249.
19. Wong MH, Chee KH, Azman W. Symptomatic anaemia 17 years after double valve replacement. *Singapore Med J* 2009; 50(10): e362-e364.
20. Yakub MA, Sivalingam S, Dillon J, Matsuhama M, Latiff HA, Ramli MF. Mitral valve repair for congenital mitral valve disease: impact of the use of a biodegradable annuloplasty ring. *Ann Thorac Surg* 2015; 99(3): 884-890.
21. Tai ML, Tan CC, Ang CC, Liam CK. Recurrent cerebral infarcts secondary to marantic endocarditis in a patient with adenocarcinoma of the lung. *Singapore Med J* 2016; 57(9): 524.
22. Abdullah HN, Khairina WW. Pulmonary edema of an unexpected cause. *South Med J* 2008; 101(10): 1035-7.
23. Haron H, Yusof M, Maskon O, Ooi J, Rahman M. Tricuspid valve papillary fibroelastoma: a rare tumor with a diagnostic dilemma. *Heart Surg Forum* 2012.
24. Murty OP. Cystic tumor of papillary muscle of heart: a rare finding in sudden death. *Am J Forensic Med Pathol* 2009; 30(2): 201-3.
25. Abdullah HN, Nowalid WK. Infiltrative cardiac lymphoma with tricuspid valve involvement in a young man. *World J Cardiol* 2014; 6(2): 77.
26. Lu HT, Nordin R, Othman N, Choy CN, Kam JY, Leo BC, et al. Biatrial thrombi resembling myxoma regressed after prolonged anticoagulation in a patient with mitral stenosis: a case report. *J Med Case Rep* 2016; 10(1): 221.
27. Loch A, Sadiq MA, Wan Ahmad WA. Giant left atrium in a patient with prosthetic mitral valve. *Eur Heart J* 2013; 34(13): 981-1.
28. Mohamed AL, Zain MM. Hoarseness of voice in a patient with mitral stenosis and Ortner's syndrome. *Malays J Med Sci* 2004; 11(2): 65.
29. Khalil A, Faisal A, Lai KW, Ng SC, Liew YM. 2D to 3D fusion of echocardiography and cardiac CT for TAVR and TAVI image guidance. *Med Biol Eng Comput* 2017; 55(8): 1317-26.
30. Lauridsen TK, Park L, Tong SY, Selton-Suty C, Peterson G, Cecchi E, et al. Echocardiographic findings predict in-hospital and 1-year mortality in left-sided native valve staphylococcus aureus endocarditis: analysis from the international collaboration on endocarditis-prospective echo cohort study. *Circ Cardiovasc Imaging* 2015; 8(7): p. e003397.
31. Lauridsen TK, Selton-Suty C, Tong S, Afonso L, Cecchi E, Park L, et al. Echocardiographic agreement in the diagnostic evaluation for infective endocarditis. *Int J Cardiovasc Imaging* 2016; 32(7): 1041-51.
32. Safara F, Doraisamy S, Azman A, Jantan A, Ranga S. Wavelet packet entropy for heart murmurs classification. *Adv Bioinformatics* 2012.
33. Salleh SH, Tan TS, Sh-Hussain H, Oemar H. Heart Murmur Diagnostic System (HMDS). Acta Press 2012.
34. Eng JB. The trans-septal approach to the mitral valve. *Med J Malaysia* 2001; 56(2): 236-9.
35. Tay E, Muda N, Yap J, Muller DW, Santoso T, Walters DL, et al. The MitraClip Asia-Pacific registry: Differences in outcomes between functional and degenerative mitral regurgitation. *Catheter Cardiovasc Interv* 2016; 87(7): E275-E281.
36. Dillon J, Yakub MA, Pau KK, Taib ME. Leaflet extension for repairing rheumatic mitral valve regurgitation. *Ann Cardiothorac Surg* 2015; 4(3): 301.
37. Dillon J, Yakub MA, Nordin MN, Pau KK, Krishna Moorthy PS. Leaflet extension in rheumatic mitral valve reconstruction. *Eur J Cardiothorac Surg* 2013; 44(4): 682-9.
38. Dillon J, Yakub MA, Kong PK, Ramli MF, Jaffar N, Gaffar IF. Comparative long-term results of mitral valve repair in adults with chronic rheumatic disease and degenerative disease: Is repair for "burnt-out" rheumatic disease still inferior to repair for degenerative disease in the current era? *J Thorac Cardiovasc Surg* 2015; 149(3): 771-9.
39. Yakub MA, Dillon J, Krishna Moorthy PS, Pau KK, Nordin MN. Is rheumatic aetiology a predictor of poor outcome in the current era of mitral valve repair? Contemporary long-term results of mitral valve repair in rheumatic heart disease. *Eur J Cardiothorac Surg* 2013; 44(4): 673-81.
40. Yakub MA, Krishna Moorthy PS, Sivalingam S, Dillon J, Kong PK. Contemporary long-term outcomes of an aggressive approach to mitral valve repair in children: is it effective and durable for both congenital and acquired mitral valve lesions? *Eur J Cardiothorac Surg* 2015; 49(2): 553-60.
41. Izhm IN, Zamrin DM, Joanna OS, Ramzisham AR, Hairolfaizi H, Ishamuddin IM, et al. Myocardial ischaemic time and its relation with left ventricular ejection fraction after single valve replacement. *Clin Ter* 2011; 162(6): 521-5.
42. Pau KK, Yakub A, Sallehuddin A, Awang Y. Obstruction of mechanical heart valve-diagnosis, Surgical treatment and outcome. *Med J Malaysia* 2001; 56(2): 196-200.
43. Alawami M, Nicholas B, Watson T, Ruygok P, Pemberton J. Paravalvular leak after mechanical aortic valve replacement causing hemolytic anemia: closure with vascular plug. *J Cardiovasc Med (Hagerstown)* 2016; 17: e189-e190.
44. Kim MY, Na CY, Kim YM, Seo JW. Late aortic dilatation and regurgitation after Ross operation. *Malays J Pathol* 2010; 32(2): 129-35.