

Diagnosis of pulmonary embolism: A comparison between ventilation/perfusion SPECT/CT and perfusion-only SPECT/CT

Thanuja Mahaletchumy, MMed, Maimanah Muhamad, MSc, Sara Umar, MBBS

Department of Molecular Imaging and Nuclear Medicine, Universiti Kebangsaan Malaysia Medical Centre, Cheras, Malaysia

ABSTRACT

Background: The role of nuclear medicine in diagnosing pulmonary embolism (PE) is continuously evolving owing to advancements in imaging methods. In recent years, ventilation/perfusion single photon emission computed tomography-computed tomography (V/Q SPECT/CT) has established a synergistic role over conventional V/Q planar scintigraphy and V/Q SPECT in diagnosing pulmonary embolism.

Objectives: In this study, we aimed to assess the incremental value of V/Q SPECT/CT over conventional V/Q planar scintigraphy and V/Q SPECT, and to determine if Q only-SPECT/CT without the conventional ventilation component could replace the current imaging protocol in diagnosing pulmonary embolism.

Methods: We retrospectively assessed 73 patients with suspicion of pulmonary embolism who had undergone Q planar scintigraphy, V/Q SPECT and V/Q SPECT/CT consecutively. Combination of clinical follow-up, laboratory test results and correlative imaging were used as reference standard. Q-only SPECT/CT datasets were then analysed separately without the V-planar, V-SPECT and V-SPECT/CT datasets.

Results: A total of 66 patients fulfilled our initial inclusion and exclusion criteria, with 23 patients as positive for PE and 43 patients ruled out of having PE based on the reference standard. Sensitivity and specificity for V/P planar scintigraphy, V/Q SPECT, and V/Q SPECT-CT were 86.9% and 39.5%, 91.3% and 55.8%, and 100% and 97.6% respectively. Overall, SPECT/CT resulted in significantly higher diagnostic accuracy than planar and SPECT imaging respectively ($p < 0.05$). Q-only SPECT/CT significantly over diagnosed pulmonary embolism in 12 patients ($p < 0.05$).

Conclusion: Adding V/Q SPECT/CT to the algorithm of PE significantly improves the sensitivity and specificity. However, by eliminating the ventilation component, the diagnostic accuracy is significantly reduced.

KEYWORDS:

SPECT/CT, pulmonary embolism, ventilation/perfusion scintigraphy

INTRODUCTION

In recent years, there is evolution of imaging techniques in diagnosing pulmonary embolism (PE) with single photon emission/computed tomography (SPECT/CT) being one of latest addition. Although planar ventilation-perfusion (V/Q) scintigraphy and SPECT has long been used in the diagnosis of PE, its role has reduced mainly owing to its lack of specificity and weaknesses of the interpretation criteria.¹ The advent of SPECT/CT has opened new dimensions in diagnostic imaging of various disease conditions including PE. This hybrid imaging modality allows characterisation of a defect seen on planar and SPECT V/Q scan by providing both the functional and anatomical information. Along with the growing evidence regarding the use of V/Q SPECT/CT in various published data, its use in the diagnosis of PE continues to evolve owing to advancements in imaging techniques, equipment specifications and improvised interpretation criteria.^{2,3} This study is aimed at further validating this technique and increase the confidence of referring physicians to incorporate it in the management of patients with PE. According to some previous publications and based on our own preliminary experience, SPECT/CT may potentially serve as a substitute for ventilation scintigraphy.^{4,5} Therefore, we also aimed to determine if Q only-SPECT/CT without the conventional ventilation component could replace the current imaging protocol in diagnosing pulmonary embolism.

MATERIALS AND METHODS

A total of 73 patients who were referred to Department of Nuclear Medicine and Molecular Imaging, Universiti Kebangsaan Malaysia Medical Centre with suspicion of PE were retrospectively studied between January 2016 and June 2018. This study was approved by the institutional ethics committee. The inclusion criteria were patients with Wells' score of ≥ 2 or Wells' score of < 2 with positive D-dimer test and clinical follow-up available for at least six months.

Ventilation studies were performed after inhalation of 10-25mCi of Tc99m-Technegas over 3-5 respiratory cycles via a Technegas generator. Perfusion studies were performed immediately after the ventilation scan with intravenous injection of 5mCi of Tc99m-macroaggregated albumin (MAA) in the supine position.

This article was accepted: 29 June 2020

Corresponding Author: Thanuja Mahaletchumy

Email: mthanu@msn.com

Images were acquired on a hybrid SPECT/CT dual head gamma camera (GE Infinia Hawkeye, GE Healthcare) equipped with low energy high resolution (LEHR) parallel hole collimator, at 140keV photopeak with 20% symmetrical window. The planar scans were obtained in eight projections: anterior, posterior, left lateral, right lateral, right anterior oblique, right posterior oblique, left anterior oblique and left posterior oblique. The time per projection was 200 seconds. After completion of planar scans, all the patients underwent SPECT scans with the same gamma camera. SPECT data was collected in step-and-shoot mode with angular range of 180° in 3-degree increments and duration of 15 seconds per step. The image acquisition matrix was 128x128. Images were acquired on the 140keV photopeak with a 20% symmetrical window. SPECT images were iteratively reconstructed with 3D ordered subset expectation maximization (OSEM) with two iterations and 10 subsets on Xeleris workstation. Images were smoothed with Hann and Butterworth filter. Tomographic slices were displayed as transaxial, coronal and sagittal images.

A low-dose CT component was used for this study. The CT component of the SPECT/CT was acquired on the GE Infinia Hawkeye was done with an x-ray tube mounted within the same gantry on a 512x512 matrix, voltage 140kVp and current 2.5mA. Acquisition slice thickness is 5mm with rotation velocity of 2.6rpm. All the planar, SPECT and CT acquisitions were obtained with the patient in the same position.

Images were independently interpreted by two readers with more than five years of experience in V/Q scan reporting and who were blinded to the results from the reference standard. In cases of discrepancy, consensus was obtained by joint reading. They were interpreted separately: first the planar images, then the SPECT images and finally the fused SPECT-CT images. All the images were interpreted with Xeleris 1 and 2 workstations (GE Healthcare).

The diagnosis of PE was made based on the following criteria: at least one segmental or two subsegmental perfusion defects (wedge shaped, pleural based) without morphological abnormalities in the lung parenchyma on CT. The following scintigraphic criteria were established for excluding PE: normal perfusion pattern, perfusion defects that were not arranged in accordance with the pulmonary vasculature and perfusion defects caused by abnormalities in the lung parenchyma as seen on CT.

The final diagnosis was made based on the reference standard which included combination of laboratory test results, additional correlative imaging (chest radiography, CT Pulmonary Angiography [CTPA], echocardiography and lower extremity ultrasound) and follow-up of at least six months. PE was ruled out in patients who did not receive anticoagulant treatment and did not have clinical signs of PE (dyspnoea, haemoptysis, chest pain, syncope and deep vein thrombosis symptoms) within six months from the lung scintigraphy.

All the acquired data were expressed as numbers and percentages. Data comparison (planar and SPECT/ planar

and SPECT-CT/ SPECT and SPECT-CT) was done using McNemar's test. The sensitivity, specificity, negative predictive value (NPV) and positive predictive value (PPV) of the three imaging modalities was calculated with a confidence level of 95% ($p < 0.05$ was considered statistically significant).

RESULTS

A total of 73 patients with suspicion of PE were included in the study. There were 40 women and 33 men. All the patients were in the age group of 25-83 years old. Seven patients were lost to follow-up. Only data from 66 patients were available for further analysis.

The final diagnosis of PE for each patient was obtained from the reference standard which is combination of clinical follow-up which includes a follow-up of at least 6 months, laboratory test results and additional correlative imaging. Twenty-five of the patients whose data were analysed had correlative imaging available. Seventeen patients had follow-up chest radiography and eight patients had CTPA. The other 41 patients with no correlative imaging were followed up clinically for 6-9 months. Based on the reference standard, 23 patients (35%) were diagnosed with PE. PE was ruled out in the other 43 patients (65%).

V/Q planar scintigraphy, V/Q single-photon emission computed tomography, and V/Q single-photon emission computed tomography-computed tomography

The findings on V/Q planar scintigraphy, V/Q SPECT, and V/Q SPECT/CT are detailed in Figure 1. On V/Q planar scintigraphy, of the 46 patients who were interpreted as having PE, only 20 were true positive, and of the 20 patients who were interpreted as no PE, 17 were true negative.

The number of patients who were interpreted as having PE on V/Q SPECT was 40, which was lesser than on planar scintigraphy. Among these 40 patients, 21 were true positive. The other 26 patients were interpreted as not having PE, and among these patients, 24 were true negative (Figure 2). On V/Q SPECT/CT, 24 patients were interpreted as having PE, of which 23 were true positive (Figure 3). All the 42 patients who were interpreted as no PE, were accurately diagnosed based on reference standard. Overall, V/Q SPECT/CT resulted in significant reduction in the number of false positive and false negative cases ($p < 0.05$). (Table I)

Sensitivity, specificity, and predictive values were separately calculated for V/Q planar scintigraphy, V/Q SPECT, and V/Q SPECT/CT. (Table II)

Impact on patient management

Based on V/Q SPECT/CT findings, overall diagnosis was altered in 44 (66%) out of 66 patients. Twenty-two patients were over diagnosed on V/Q planar as compared to only one on V/Q SPECT/CT. Three patients were underdiagnosed on V/Q planar scintigraphy as compared to none on SPECT/CT. All the patients whose diagnosis was altered by V/Q SPECT/CT had correct diagnosis based on reference standard (98.5% accuracy).

Table I: False-positive and false-negative results of the imaging methods

	V/Q Planar	V/Q SPECT	V/Q SPECT/CT
False positive	26	19	1
False negative	3	2	0

Table II: Sensitivity, specificity, positive predictive value, negative predictive value and accuracy of the imaging methods

Parameters	V/Q Planar	V/Q SPECT	V/Q SPECT/CT
Sensitivity	86.9	91.3	100
Specificity	39.5	55.8	97.6
PPV	43.5	52.5	95.8
NPV	85	92.3	100
Accuracy	56.1	68.2	98.5

*PPV: positive predictive value; NPV: negative predictive value

Table III: Sensitivity, specificity, positive predictive value, negative predictive value and accuracy of Q-only SPECT-CT

Parameters	Q-only SPECT/CT
Sensitivity	100
Specificity	52
Positive predictive value	65.7
Negative predictive value	100
Accuracy	75

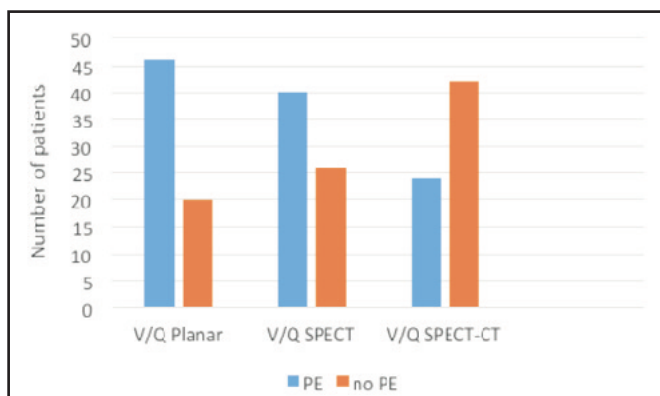


Fig. 1: Interpretation on the presence or absence of PE based on V/Q planar scintigraphy, V/Q SPECT, and V/Q SPECT/CT.

Q-only single-photon emission computed tomography-computed tomography

On Q-only SPECT/CT, 36 patients were interpreted as having PE, of which only 23 were true positive. Thirteen other patients were falsely diagnosed as PE (Figure 4). The other 30 patients who were interpreted as no PE were all accurately diagnosed based on reference standard. Overall, Q-only SPECT/CT significantly ($p < 0.05$) over diagnosed PE in 13 patients. However, the negative predictive value is high as none of the patients with PE were missed. The sensitivity, specificity, and predictive values for Q-only SPECT/CT are shown in Table III.

DISCUSSION

The aim of imaging in a patient with suspected PE is to accurately confirm or rule out the diagnosis. In recent years, there has been rapid advancements in the nuclear medicine imaging techniques for the diagnosis of PE. However, despite

these advancements, PE still remains a diagnostic challenge owing mainly to lack of standard interpretation criteria, limited availability and lack of ordering physician's familiarity with these techniques.

V/Q planar scintigraphy is a sensitive imaging modality to detect pulmonary embolism. However, the diagnostic dilemma remains due to its lack of specificity and high rate of non-diagnostic results.^{6,7} Addition of SPECT serves as a valuable tool to increase the diagnostic accuracy.⁸ Many studies demonstrate enhanced sensitivity and specificity, as well as a reduction in the non-diagnostic rate of V/P SPECT compared with planar V/P scintigraphy.⁹⁻¹¹ SPECT/CT, which enables the acquisition of V/Q SPECT and CT scans of the lung in a single imaging session, provides further advantage over SPECT alone. It allows visualisation of non-thromboembolic abnormalities such as atelectasis, emphysema, pneumonic infiltration, pleural fluid, or interlobar fissures which may explain V/Q SPECT defects.

In our study, V/Q planar scans detected PE with 86.9% sensitivity and 39.5% specificity. V/Q SPECT improved the detection with sensitivity of 91.3% and specificity of 55.8%. Our data is almost similar to those achieved by other authors using the SPECT V/Q method.^{7,9,11}

Combining CT component with V/Q SPECT, significantly improved the sensitivity and specificity to 100% and 97.6% respectively. Similarly, the diagnostic accuracy improved to 98.5% with the addition of CT component, as compared to 56.1% for V/Q planar and 68.2% for V/Q SPECT. A study by Gutte et al., who performed a head-to-head comparison of V/Q SPECT/CT, V/Q SPECT and CTPA showed that V/Q SPECT-CT had the highest accuracy rate (99%) among the three modalities.³ Another similar study by Le-Roux et al. also showed similar finding to our study.¹²

A false-positive or false-negative diagnosis of PE can have dire consequences on for the patient. A false-positive diagnosis will result in futile anticoagulation therapy for the patient and a false-negative diagnosis will increase the risk of recurrent PE or possible death. In this study, 44 (66%) out of 66 patients had their diagnosis altered based on V/Q SPECT/CT. Only one patient was misdiagnosed as PE on V/Q SPECT/CT and there were no false-negative diagnoses.

The addition of SPECT-CT also allows for an alternative diagnosis to be made on patients with negative PE. One of the advantages of CTPA over V/Q scintigraphy is the possibility of providing an alternative diagnosis. In our study, although the CT component is low-dose and inferior to CTPA (no contrast agent, breath-hold technique not applied), we were still able to identify alternative non-thromboembolic causes in 15% of patients with negative PE on V/Q SPECT. Similarly, a study by Le-Roux et al. was able to identify potential alternative diagnosis in 24% of patients with negative V/Q SPECT.¹² The radiation dose incurred from the addition of low dose CT as in our study is 3.5mSv, which is significantly lesser than CTPA.

In some patients especially those with shortness of breath, it is not possible to perform a ventilation scan due to inability of the patient to perform an inhalation correctly. This will result in inadequate inhalation of Technegas which will subsequently produce suboptimal images for interpretation. By omitting the ventilation component of the scan, the scan time can also be reduced to half of the total scan time. This is again beneficial for patients who are unable to lie in supine position for prolonged duration. Therefore, in this study, we also assessed the accuracy of Q only-SPECT/CT without the conventional ventilation component. However, based on our findings, nine patients (14%) were over-diagnosed with PE based on Q only-SPECT/CT. Our data is concordant with the results of Palmowski et al., in which a false-positive rate of 17.3% was found with Q only-SPECT/CT and a study by Le Roux et al., which similarly showed high false-positive rate when the ventilation component was omitted.^{12,13} Gutte et al., through his study demonstrated that Q only-SPECT/CT has a higher non-diagnostic rate (17%) and lower specificity than V/Q SPECT/CT (51% vs 100%).³ The findings from our study and several other studies show that by substituting the ventilation component with CT, the rate of overdiagnosis and subsequently overtreatment is increased.

The main limitation of this study, similar to many other studies, is the lack of common reference standard in all the patients as the decision on the method of follow-up for the patients was made by the referring physicians.

CONCLUSION

The results from this study show that V/Q SPECT/CT significantly improves the sensitivity, specificity and accuracy in diagnosing PE with resultant accurate alteration in patient management clinically. However, by substituting the ventilation component with low-dose CT, the risk of overdiagnosis and overtreatment is increased.

REFERENCES

1. PIOPED Investigators. Value of the ventilation/perfusion scan in acute pulmonary embolism: results of the Prospective Investigation of Pulmonary Embolism Diagnosis (PIOPED). The PIOPED Investigators. *JAMA* 1990; 263: 2753-59.
2. Mortensen J, Gutte H. SPECT/CT and pulmonary embolism. *Eur J Nucl Med Mol Imaging* 2014; 41: S81-90.
3. Gutte H, Mortensen J, Jensen CV, Johnbeck CB, von der Recke P, Petersen CL, et al. Detection of pulmonary embolism with combined ventilation-perfusion SPECT and low dose CT: head-to-head comparison with multidetector CT angiography. *J Nucl Med* 2009; 50: 1987-92.
4. Grandinscak DJ, Roach P, Schembri GP. Lung SPECT perfusion scintigraphy: can CT substitute for ventilation imaging? *Eur J Nucl Med Mol Imaging* 2009; 36: S300.
5. Mazurek A, Dziuk M, Witkowska-Patena E, Piszczek S, Gizewska A. The utility of hybrid SPECT/CT lung perfusion scintigraphy in pulmonary embolism diagnosis. *Respiration* 2015; 90: 393-401.
6. Anderson DR, Kahn SR, Rodger MA, et al. Computed tomographic pulmonary angiography vs ventilation-perfusion lung scanning in patients with suspected pulmonary embolism: a randomized controlled trial. *JAMA* 2007; 298: 2743-53.
7. Miles S, Rogers KM, Thomas P, Soans B, Attia J, Abel C et al. A comparison of single photon emission CT lung scintigraphy and CT pulmonary angiography for the diagnosis of pulmonary embolism. *Chest* 2009; 136: 1546-53.
8. Bajc M, Neilly JB, Miniati M, Scuemichen C, Meignan M, Jonson B. EANM guidelines for ventilation/perfusion scintigraphy: Part 2. Algorithms and clinical considerations for diagnosis of pulmonary emboli with V/P(SPECT) and MDCT. *Eur J Nucl Med Mol Imaging* 2009; 36: 1528-38.
9. Gutte H, Mortensen J, Jensen CV, von der Recke P, Petersen CL, Kristoffersen US, et al. Comparison of V/Q SPECT and planar V/Q lung scintigraphy in diagnosing acute pulmonary embolism. *Nucl Med Commun* 2010; 31(1): 82-6.
10. Bajc M, Olsson CG, Olsson B, Palmer J, Jonson B. Diagnostic evaluation of planar and tomographic ventilation/perfusion lung images in patients with suspected pulmonary emboli. *Clin Physiol Funct Imaging* 2004; 24(5): 249-56.
11. Reinartz P, Wildberger JE, Schaefer W, Nowak B, Mahnken AH, Buell U. Tomographic imaging in the diagnosis of pulmonary embolism: a comparison between V/Q lung scintigraphy in SPECT technique and multislice spiral CT. *J Nucl Med* 2004; 45(9): 1501-8.
12. Le Roux PY, Robin P, Delluc A, Abgral R, Palard X, Tissot V et al. Additional value of combining low-dose computed tomography to V/Q SPECT on a hybrid SPECT-CT camera for pulmonary embolism diagnosis. *Nucl Med Commun* 2015; 36: 922-30.
13. Palmowski K, Oltmanns U, Kreuter M, Mottaghy FM, Palmowski M, Behrendt FF. Diagnosis of pulmonary embolism: conventional ventilation/perfusion SPECT is superior to the combination of perfusion SPECT and nonenhanced CT. *Respiration* 2014; 88: 291-7.