

# Intestinal knotting: A case report and brief literature review

Sohail Mushtaq, FRCS<sup>1,2</sup>, Alyson Tan Su Yin, MB MCh Bao<sup>2</sup>, Sim Sze Kiat, MS<sup>1</sup>, Nik Azim Nik Abdullah, MS<sup>2</sup>

<sup>1</sup>Faculty of Medicine and Health Sciences, Universiti Malaysia Sarawak, Kota Samarahan, Sarawak, <sup>2</sup>Department of Surgery, Sarawak General Hospital, Jalan Hospital, Kuching, Sarawak

### SUMMARY

**Ileo-ileal knotting is a rare cause of intestinal obstruction. In this condition, one bowel loop makes a knot with an adjacent bowel loop, resulting in mechanical obstruction and even gangrene of the bowel. We present a case of a young girl with ileo-ileal knotting resulting in a closed-loop obstruction and gangrene of the small bowel loop. This is a difficult condition to diagnose; a high index of suspicion and early surgical intervention are essential to reduce morbidity and mortality.**

### INTRODUCTION

Strangulated intestinal obstruction is a common acute abdominal condition that requires urgent surgical intervention. Delay in treatment can result in perforation of the bowel, sepsis, and death. Common causes of small bowel strangulation are abdominal hernias, adhesions, bands, primary volvulus, and intussusception. Ileo-ileal knotting is a rare cause of strangulated bowel obstruction.<sup>1</sup> Other types of bowel knotting include ileo-caecal and ileo-sigmoid.<sup>1,2</sup> We present a rare case of acute strangulated intestinal obstruction caused by an ileo-ileal knot in a young woman who required emergency surgical treatment.

### CASE REPORT

A 17-year-old female patient presented to the emergency department of Sarawak General Hospital, Kuching, on 18 January 2020 with a 2-day history of colicky central abdominal pain and several episodes of vomiting. She had undergone an open appendectomy four years previously. The systemic review was unremarkable. On examination, she was tachycardic with a pain score of 7/10; otherwise, her vital signs were within the normal range (pulse rate 110beats/min, blood pressure 110/70mmHg, respiratory rate 14breaths/min, temperature 36.5°C). Abdominal examination revealed a transverse scar 5cm in length in the right lower quadrant. There was no distension, but the abdomen was very tender in the right lower quadrant. A digital rectal examination revealed no abnormalities. Full blood count showed leucocytosis (haemoglobin 12.1g/dL, white cell count  $29.9 \times 10^3/\mu\text{L}$ , platelets  $427 \times 10^3/\mu\text{L}$ ), and arterial blood gas analysis revealed mild metabolic alkalosis (pH 7.45, PO<sub>2</sub> 102mmHg, PCO<sub>2</sub> 39.5mmHg, base excess -3.6mmol/L, HCO<sub>3</sub> 18.6mmol/L). Serum electrolytes and renal and liver function were normal. Urine test for pregnancy was negative.

Abdominal X-ray showed dilated small bowel loops in the lower abdomen. A contrast-enhanced computed tomography (CT) scan of the abdomen and pelvis suggested a closed-loop obstruction of the distal ileum with suspicion of ischaemia (Figure 1).

The patient underwent emergency laparotomy through a lower midline incision after fluid resuscitation and nasogastric decompression. Haemorrhagic fluid was found in the peritoneal cavity. The caecum was adherent to the previous scar. One loop of the ileum was found to be knotted around another loop of the ileum 5cm from the ileo-caecal junction, resulting in gangrene of the entrapped loop (Figure 2). The proximal small bowel was dilated, while the distal bowel was collapsed. We did not unknot the involved bowel because this could risk perforation and spillage of its contents. About 60–70cm of bowel was resected, including the knotted ileum loops, the caecum, and part of the ascending colon. Functional end-to-end anastomosis between the viable ileum and ascending colon was performed using a linear stapler. The remaining length of viable small bowel, measured from the duodenojejunal flexure, was approximately 300cm. Peritoneal washout was performed with 0.9% saline and the abdomen closed with loop nylon. A 21-French tube drain was left in the pelvis. After surgery, cefoperazone and metronidazole were administered intravenously for 5 days. The patient's recovery was uneventful. She was allowed oral intake of clear fluids on post-operative day-1, nourishing fluids on day-2, and soft diet on day-3. She passed flatus on post-operative day-2 and stool on day-3. The abdominal drain was removed on post-operative day-3, and she was discharged on day-5. During the follow-up period, she reported no further problems, and the abdominal wound healed without any complications. The histopathology report was consistent with bowel ischaemia.

### DISCUSSION

Riverius first reported Intestinal knotting in the 16th century and subsequently by Rokitsansky in 1836.<sup>1</sup> Of the several types of intestinal knots, ileo-sigmoid knots are the most common and ileo-ileal knots the rarest.<sup>1,3</sup> Predisposing factors for ileo-sigmoid knotting include having a redundant sigmoid colon with a long narrow mesentery and consuming a high-fibre, bulky diet,<sup>1,3,4</sup> but predisposing factors for ileo-ileal knotting are not well known.

Table I: Comparison of previously described cases of ileo-ileal knotting and ours

Authors/year	Age/sex	Chief complaint	Past surgical history	Knot point	Duration until operation	Operation	Outcome
Pendse et al. <sup>6</sup> 1988	11 months/ND	Vomiting, constipation, abdominal distension	None	20cm from ileo-caecal junction	48h	En bloc resection of gangrenous segment, anastomosis	Survival
Uday et al. <sup>5</sup> 2012	68/M	Vomiting, constipation, abdominal distension	None	15cm from ileo-caecal junction	48h	Untying of knot, resection of gangrenous segment, anastomosis	POD 8 discharge
Andromanakos et al. <sup>3</sup> 2014	26/M	Abdominal pain	None	Ileum-ileum, sigmoid-ileum	6h	Untying of knot after decompressive enterotomy, resection of gangrenous segment, anastomosis	POD 15 discharge
Kumar <sup>2</sup> 2015	75/F	Abdominal pain, distention, vomiting, constipation	Left inguinal hernia, vaginal hysterectomy	Ileum-ileum	72h	Untying of knot after decompressive enterotomy	Survival
Abebe et al. <sup>4</sup> 2015	55/F	Abdominal pain	None	8cm from ileo-caecal junction	48h	En bloc resection of gangrenous segment, anastomosis	POD 6 discharge
Gopivallabh et al. <sup>7</sup> 2016	54/M	Swelling in the right groin, abdominal distension, constipation	Appendectomy	30cm proximal to ileo-caecal junction	ND	En bloc resection of gangrenous segment, anastomosis	POD 14 discharge
Taniguchi et al. <sup>1</sup> 2017	80/F	Abdominal pain	Colostomy, adnexectomy	10cm from ileo-caecal junction	6h	Untying of knot after decompressive enterotomy, resection of gangrenous segment, anastomosis	POD 12 discharge
Our case 2020	17/F	Abdominal pain, vomiting	Appendectomy	5cm from ileo-caecal junction	24h	Resection of gangrenous segment without untying the knot, anastomosis	POD 5 discharge

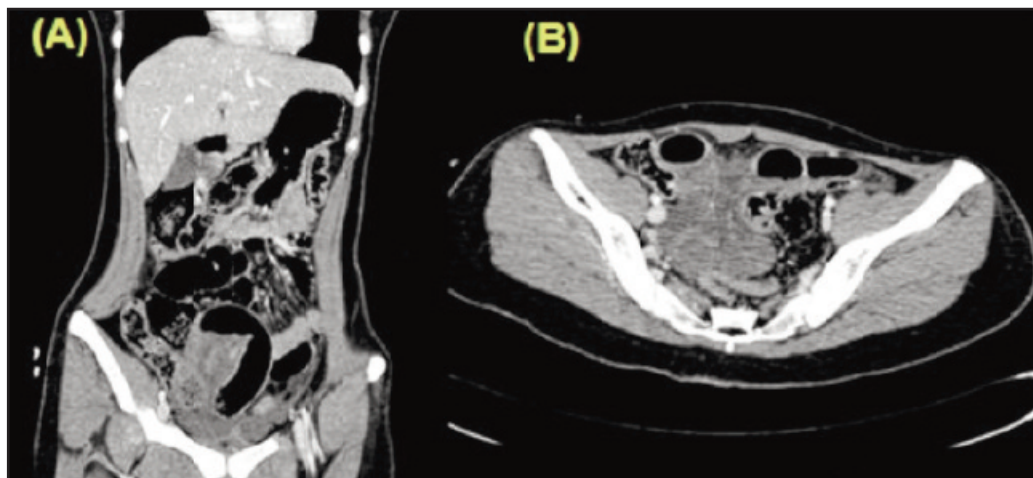
Table modified from Taniguchi et al.<sup>1</sup> ND, not described. POD, post-operative day.

Intestinal knotting presents with features of bowel obstruction and progresses rapidly. However, the classical features of intestinal obstruction (abdominal pain, vomiting, distension, and constipation) may not be evident. The presence on a CT scan of features such as dilated bowel loops, poorly enhancing bowel wall, and torsion of the mesentery (whirl sign) may help in diagnosis, but most of the time, the final diagnosis is made only intra-operatively.<sup>4,5</sup> Laparoscopy may help to confirm the diagnosis in selected cases. Rapid fluid resuscitation with crystalloids, nasogastric decompression, pain control, and systemic antibiotics are essential components of pre-operative management.

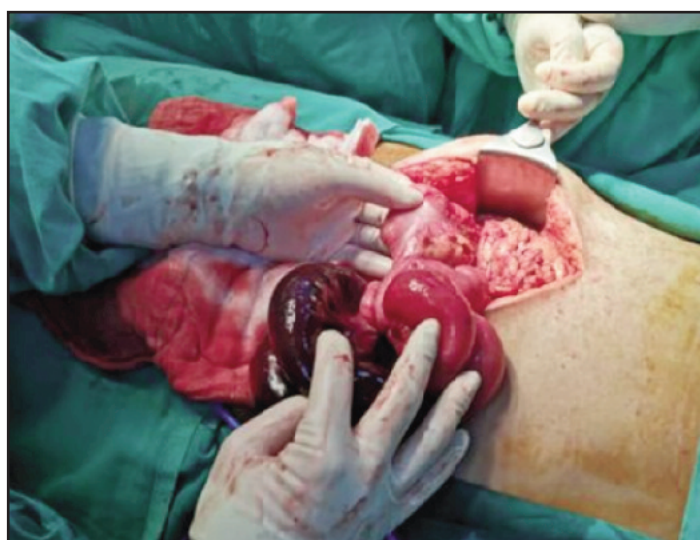Operation should proceed without unnecessary delay because the condition poses a high risk of morbidity and mortality. During surgery, if the bowel is viable, the knot should be untied to relieve obstruction and treat the underlying cause.<sup>1</sup> If the bowel loop is gangrenous, it is better not to untie the knot, because this can result in perforation of the bowel and spillage of the contents.<sup>1,4</sup> In our case, resection anastomosis of the involved bowel loops was performed without any attempt to untie the knot. The length of bowel remaining in the abdomen should always be documented, in addition to the length resected. Extensive resection of the small bowel may result in short bowel syndrome,

necessitating nutritional support on a long-term basis.<sup>4</sup> Post-operatively, administration of nasogastric decompression, intravenous fluids, and antibiotics should continue, and patients should be monitored for any signs of anastomotic leak. In elderly patients with multiple comorbid conditions, primary anastomosis after resection of the gangrenous bowel may be risky; therefore, these patients may require temporary ileostomy or colostomy. Early ambulation, adequate pain control, and chest physiotherapy are very important during the post-operative period. Deep vein thrombosis prophylaxis is recommended in high-risk patients.

There are not many cases of ileo-ileal knotting reported in the literature. Taniguchi et al.<sup>1</sup> summarised seven previous cases (Table I). Five of these cases were in patients above 50 years old, one in an infant, and one in a young adult. Thus, ileo-ileal knotting appears to be rare, especially in young patients. In the majority of cases, surgery was performed within 48 h of diagnosis, usually involving bowel resection with primary anastomosis; in one case in which the bowel was viable, decompressive enterotomy and untying of the knot were performed without resection. In four cases, including ours, the patient had a previous history of abdominal surgery.



**Fig. 1:** Computed tomography scan of the abdomen and pelvis (A, coronal view; B, axial view) showing twisting of the mesenteric pedicle of the distal ileum at the right iliac fossa; mildly dilated small bowel with poor bowel wall enhancement and oedematous mesentery demonstrated.



**Fig. 2:** Intra-operative findings: one loop of the ileum making a knot with an adjacent ileal loop, resulting in obstructed gangrene of the entrapped loop.

### CONCLUSION

Ileo-ileal knotting is a rare cause of intestinal obstruction. Patients may not present with typical features of intestinal obstruction. A high index of suspicion and early surgical intervention are needed to prevent morbidity and mortality.

### CONSENT

Written informed consent was obtained from the patient for the publication of this case report.

### REFERENCES

1. Taniguchi K, Iida R, Watanabe T, Nitta M, Tomioka M, Uchiyama K, et al. Ileo-ileal knot: a rare case of acute strangulated intestinal Obstruction. *Nagoya J Med Sci* 2017; 79(1): 109-13.
2. Kumar SS. A Rare Cause of Intestinal Obstruction – Ileoileal Knotting. *IOSR Journal of Dental and Medical Sciences* 2015; 14: 23-4.
3. Andromanos N, Filippou D, Pini S, Kostakis A. An unusual synchronous ileosigmoid and ileoileal knotting: a case report. *J Med Case Rep* 2014; 8: 200.
4. Abebe E, Asmare B, Addise A. Ileo-ileal knotting as an uncommon cause of acute intestinal obstruction. *J Surg Case Rep* 2015; 8: rjv102.
5. Uday SK, Venkata PKC, Bhargav PRK, Kumar S. Ileo-ileal knot causing small bowel gangrene: an unusual presentation. *Int J Case Rep Imag* 2012; 3(5): 28-30.
6. Pendse AK, Prajapat G, Sharma A, Sharma M. Ileo-ileal knotting causing intestinal obstruction. *Indian J Pediatr* 1988; 55: 639-40.
7. Gopivallabh MM, Jagannmaya K, Hanumanthaiah KS, Babannavar P, Crithic V. Ileoileal knot as a content of obstructed hernia: what are the odds? *Iran J Med Sci* 2016; 41: 238-40.