

# Dengue associated haemophagocytic lymphohistiocytosis: An often-missed complication of a common infection

**Panit Takkinsatian, MD, Panjarat Sowithayasakul, MD, Olarn Prommalikit, MD**

Department of Pediatrics, Faculty of Medicine, Srinakharinwirot University, Nakhon Nayok, Thailand

### SUMMARY

Hemophagocytic lymphohistiocytosis (HLH) is a severe and life-threatening condition causing multisystem involvement such as cytopenia, hepatosplenomegaly, and death. Dengue infection is one of the leading causes of HLH. We reviewed three cases of children at HRH Princess Maha Chakri Sirindhorn Medical Center, Faculty of Medicine, Srinakharinwirot University, Nakhon Nayok, Thailand, with dengue fever who subsequently developed HLH, based on the HLH-2004 diagnostic criteria. Following treatment with dexamethasone and intravenous immunoglobulin, there was a dramatic response including defervescence and improvement of cytopenia, hyperfibrinogenemia, and hyperferritinemia. Key features for diagnosis of dengue fever complicated by HLH include a history of prolonged fever exceeding seven days, splenomegaly, and worsening cytopenia. Early recognition and treatment are crucial for a successful outcome.

### INTRODUCTION

Hemophagocytic lymphohistiocytosis (HLH) is a severe life-threatening condition which comprises of primary and secondary forms. Secondary HLH occurs after an intense immunologic stimulation, such as an infection (infection-associated hemophagocytic syndrome-IAHS), autoimmune disease, or malignancy. For IAHS, the most common causative organisms are viral infections, especially the Epstein Barr and dengue viruses.<sup>1</sup>

Dengue is a mosquito borne disease commonly found in tropical and subtropical areas. It causes various complications including fluid overload leading to heart failure, bleeding, multi-organ failure. Atypical complications such as septic shock or HLH occasionally occur as well.<sup>2</sup> Missed or delayed diagnosis of these complications might cause death. Many cases of dengue-associated HLH have been reported from different areas worldwide. However, there are limited reports from Southeast Asian countries which are an endemic area for dengue infection. Recognising HLH can be difficult due to overlapping clinical manifestations with dengue fever itself. We report herein three cases of children at HRH Princess Maha Chakri Sirindhorn Medical Center, Faculty of Medicine, Srinakharinwirot University, Nakhon Nayok, Thailand, who were diagnosed with dengue-associated HLH and treated successfully.

### CASE REPORT

#### Case I

A 3-year-old girl presented with fever, watery diarrhoea, and vomiting for five days. Physical examination was unremarkable, without hepatosplenomegaly. Laboratory results revealed leukopenia, thrombocytopenia, and transaminitis. Dengue non-structural protein 1 (NS1) antigen was positive. She developed right pleural effusion on the seventh day of illness.

On the eighth day of disease, she experienced clinical deterioration, with persistent fever and splenomegaly. Blood tests revealed worsening leukopenia, thrombocytopenia and transaminitis. Due to concern for bacterial infections, cefotaxime was prescribed empirically; however, there was no clinical improvement. Further investigations revealed hyperferritinemia, hypofibrinogenemia, and a fasting triglyceride level of 205mg/dL (Table I). Bone marrow aspiration showed normocellular trilineage marrow with increased hemophagocytic activity (figure 1). HLH-2004 diagnostic criteria have been fulfilled in this patient. Intravenous Immunoglobulin (IVIG) 500 mg/kg and dexamethasone 10mg/m<sup>2</sup>/day were started. Within a day after starting treatment the fever subsided and CBC was normal within one week. She was hospitalized for seven days.

#### Case II

A 14-year-old boy presented with fever and headache for three days, with hepatomegaly. Blood tests were compatible with dengue infection, including positivity of dengue NS1 antigen, leukopenia less than 5,000 cells/mm<sup>3</sup>, and thrombocytopenia. On the seventh day of fever, splenomegaly and worsening cytopenia were detected (Table I). Hence, further blood tests were obtained to fulfil HLH-2004 diagnostic criteria. He had an extremely high level of serum ferritin, with hypofibrinogenemia; however, fasting triglyceride was not elevated at 136mg/dL. Bone marrow aspiration was compatible with HLH. Dexamethasone and IVIG were given on the 7th day of onset of fever. He rapidly responded to these medications. His blood tests seemed to get better within two days and returned to normal level within two weeks. According to HLH-2004 protocol, blood for PCR for CMV, EBV IgM/IgG, antinuclear Ab (ANA, ANF and FANA), Anti-dsDNA and Anti-SM were also obtained but the results were negative.

*This article was accepted: 25 June 2020*

*Corresponding Author: Panit Takkinsatian*

*Email: panit\_tak@hotmail.com*

Table I: Trends of laboratory results of patients with Dengue-associated HLH

Case I						
Day(s) of illness	6	7	8	9	13	22
Day(s) after HLH treatment			1	2	6	15
Hct (%)	42	35	31.1	25.3	30.5	35.4
WBC (x103cells/mm3)	4.6	7.3	7.8	6.1	9.4	22.7
Platelet (/mm3)	54	21	55	66 (8)	148	324
Ferritin (ng/mL)			>40,000		3366.9	271
Fibrinogen (mg/dL)		162.5	244.2			
Case II						
Day(s) of illness	3	6	7	8	9	15
Day(s) after HLH treatment			1	2	3	9
Hct (%)	35.2	35.3	34.4	35.6	34.7	35.5
WBC (x103cells/mm3)	4.6	3.0	3.8	1.8	5.1	11.4
Platelet (/mm3)	143	31	28	41	102	464
Ferritin (ng/mL)			>40,000		>40,000	1651.4
Fibrinogen (mg/dL)		149.3	240.1	322.6		
Case III						
Day(s) of illness	4	5	6	7	11	20
Day(s) after HLH treatment			1	2	6	15
Hct (%)	22.1	20.1	17.2	26.3	30.1	31.6
WBC (x103cells/mm <sup>3</sup> )	1.8	1.3	1.2	1.3	6.4	8.2
Platelet (/mm <sup>3</sup> )	161	136	129	196	386	435
Ferritin (ng/mL)			>40,000	23528	4441.4	574.6
Fibrinogen (mg/dL)			261	252.7	193.2	

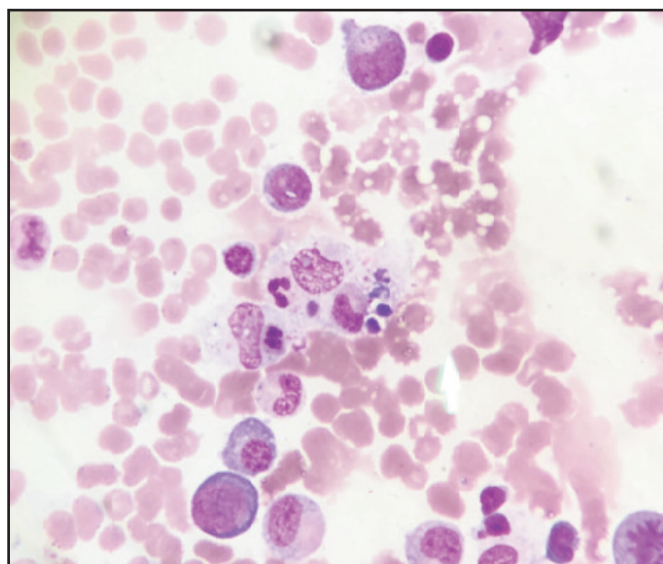


Fig. 1: Bone marrow aspirate showed increased hemophagocytic activity.

### Case III

A 10-year-old girl presented with fever, headache, myalgia and vomiting for four days. Physical examination was notable for hepatosplenomegaly. After the sixth day of fever, she developed noticeable splenomegaly, progressive anaemia with leukopenia. Hyperferritinemia and hypofibrinogenemia were also found, and fasting triglyceride was 205mg/dL (Table I). Bone marrow aspiration showed increased hemophagocytic activity.

Treatment with dexamethasone 10mg/m<sup>2</sup>/day and intravenous immunoglobulin (IVIG) were administered, resulting in rapid clinical response in the patient. Pancytopenia resolved within three days, and other

laboratory findings normalised within one week. According to HLH-2004 protocol, blood for polymerase chain reaction (PCR) for cytomegalovirus (CMV), EBV IgM/IgG, antinuclear antibody (ANA, ANF, and FANA), anti-dsDNA, and anti-SM were also obtained, but the results were negative. Treatment with dexamethasone 10mg/m<sup>2</sup>/day and intravenous immunoglobulin (IVIG) were administered, resulting in rapid clinical response. Pancytopenia resolved within five days, and other laboratory findings normalised within two weeks. Blood tests for CMV, EBV and autoimmune diseases were also negative.

### DISCUSSION

HLH is a severe, life-threatening condition. It causes excessive inflammation and tissue destruction due to abnormal immune activation, which involves natural killer cells, cytotoxic lymphocytes, and macrophages. Following activation of these cells, a cytokine storm [(interferon-gamma, tumour necrosis factor-alpha, interleukin (IL)-6, IL-10, IL-12; and soluble IL-2 receptor (CD25)] induces hemophagocytosis, wherein macrophages phagocytize their host cells. The most common causative organisms of IAHS are EBV and human herpesvirus (HHV). Previous study estimated the annual incidence of viral-induced HLH at 1 in 800,000 persons per year. However, dengue infection is also a leading cause of IAHS, accounting for 26% of virus-associated HLH.<sup>3</sup> It is difficult to differentiate HLH from severe dengue infection alone due to similar clinical and laboratory findings, such as fever, hepatosplenomegaly, leukopenia, and thrombocytopenia. According to a previous systematic review, patients' ages varied from neonate to 65 years old, and mean duration of fever was 11.3 days (95% Confidence Interval, 95%CI: 6.8, 15.8). Other significant findings were as follows: hepatomegaly 70.2% (95%CI: 51.1, 84.2), splenomegaly 78.4% (95%CI: 54.5, 91.6), anaemia 76.0% (95%CI: 56.4, 88.5), hyperferritinemia 97.1% (95% CI: 90.5,

99.2), prolonged thrombocytopenia 55.6% (95%CI: 40.9, 69.2), and coagulopathy 91.2% (95%CI: 54.7, 98.9).<sup>4</sup> Another study demonstrated that patients with HLH had significantly longer duration of fever (7 vs. 5 days,  $p<0.01$ ), longer duration of hospitalization (18 vs. 5 days,  $p<0.01$ ), and were more frequently admitted to the paediatric intensive care unit (100% vs. 15.9%,  $p<0.01$ ) than patients with dengue infection alone. They were also significantly more likely to have splenomegaly, hepatomegaly, and lymphadenopathy ( $p=0.02$ ). Maximum serum ferritin levels were higher in the HLH group (median=17,794 $\mu$ g/L) than controls (median=4,139 $\mu$ g/L).<sup>5</sup>

Our three patients had clinical clues for HLH, including fever exceeding seven days, marked splenomegaly, progressive anaemia, and worsening of leukopenia and thrombocytopenia. Additional blood tests according to HLH-2004 criteria led to early detection. All patients responded dramatically to treatment with dexamethasone and a single dose of IVIG. HLH-2004 protocol recommends initial therapy for eight weeks with etoposide and cyclosporine, combined with dexamethasone and IVIG, regardless of identified genetic mutation. However, in children, steroids and IVIG are the common regimens reported, while the use of cyclosporine and/or etoposide was very low.<sup>3</sup> Patients who do not receive appropriate and prompt treatment may be at risk of high morbidity and mortality. According to a previous study, the mortality rate of dengue-associated HLH was 14.6% (95%CI: 9.2, 22.4).<sup>4</sup>

## CONCLUSION

It is of utmost importance to recognize when HLH has developed in a patient with severe dengue haemorrhagic fever. Prolonged fever exceeding seven days, splenomegaly, and worsening cytopenia should raise clinical suspicion for HLH. Early diagnosis and treatment with steroids and IVIG are crucial for a successful outcome.

## ACKNOWLEDGEMENT

The authors like to thank the patients and their parents for the kind permission to publish of this case report.

## DECLARATION OF INTEREST

The authors report no conflict of interest.

## REFERENCES

1. Henter JI, Horne A, Arico M, Egeler RM, Filipovich AH, Imashuku S, et al. HLH-2004: Diagnostic and therapeutic guidelines for hemophagocytic lymphohistiocytosis. *Pediatr Blood Cancer* 2007; 48(2): 124-31.
2. Devaraj NK, Ragubathi MN, Er SY, Ching, SM. Septic shock as a differential diagnosis of severe dengue fever in a child in Malaysia - A case report. *Malays J Med Sci* 2019; 15(2): 154-6.
3. Rajagopala S, Singh N. Diagnosing and treating hemophagocytic lymphohistiocytosis in the tropics: systematic review from the Indian subcontinent. *Acta Med Acad* 2012; 41(2): 161-74.
4. Giang HTN, Banno K, Minh LHN, Trinh LT, Loc LT, Eltobgy A, et al. Dengue hemophagocytic syndrome: A systematic review and meta-analysis on epidemiology, clinical signs, outcomes, and risk factors. *Rev Med Virol* 2018; 28(6): e2005.
5. Ellis EM, Sharp TM, Pérez-Padilla J, González L, Poole-Smith BK, Lebo E, et al. Incidence and Risk Factors for Developing Dengue-Associated Hemophagocytic Lymphohistiocytosis in Puerto Rico, 2008 - 2013. *PLoS Negl Trop Dis* 2016; 10(8): e0004939.