

Decoding death by unknown causes using post-mortem image-guided virtopsy: A review of recent literature and the Malaysian experience

Tawfiq Yousef Tawfiq Zyoud, MS¹, Saiful Nizam Abdul Rashid, PhD^{1,2}, Subapriya Suppiah, MD^{1,3}, Ezamin Abdul Rahim, PhD¹, Rozi Mahmud, PhD^{1,3}

¹Department of Imaging, Faculty of Medicine and Health Sciences, Universiti Putra Malaysia, Serdang, Malaysia, ²Department of Radiology, Ramsay Sime Darby Health Care, Park City Medical Centre, Desa Park City, Kuala Lumpur, Malaysia, ³Centre for Diagnostic Nuclear Imaging, Universiti Putra Malaysia, Serdang, Malaysia

ABSTRACT

Introduction: Autopsy is one of the most important approaches to identify clearly the exact cause of death, whether it was due to natural causes, sudden death, or traumatic. Various studies have been done in different countries regarding ways to improve the diagnosis during autopsy. The imaging approach is one of the methods that has been used to complement autopsy findings and to enhance the diagnosis for achieving the most accurate post-mortem diagnosis. The aim of this study is to identify the role of imaging modalities that complement routine autopsy and correlate the findings of diagnostic imaging that can help improve the accuracy of diagnosing the cause of death.

Methods: We sourced articles from Scopus, Ovid and PubMed databases for journal publications related to post-mortem diagnostic imaging. We highlight the most relevant full articles in English that explain the type of modality that was utilised and the added value it provided for diagnosing the cause of death.

Results: Minimally invasive autopsies assisted by imaging modalities added a great benefit to forensic medicine, and supported conventional autopsy. In particular the role of post mortem computed tomography (PMCT), post mortem computed tomography angiography (PMMR) and positron emission tomography computed tomography (PMCTA) that have incremental benefits in diagnosing traumatic death, fractures, tissue injuries, as well as the assessment of body height or weight for corpse identification.

Conclusion: PMCT and PMMR, with particular emphasis on PMCTA, can provide higher accuracy than the other modalities. They can be regarded as indispensable methods that should be applied to the routine autopsy protocol, thus improving the findings and accuracy of diagnosing the cause of death.

KEY WORDS:

Post-mortem computed tomography, Autopsy, Cause of death, Forensic Radiology

INTRODUCTION

Historically, the word “autopsy” was first used in the 17th-century literature and it refers to the examination of the internal organs of the dead human body to find out illnesses and the main cause of death. Ancient Egyptians in the year 3000 BC were the first to practice the examination of the internal organs of humans, and they called as mummification.¹ Traditionally, dissection of the human body or more commonly known as conventional autopsy (CA) is performed to identify the cause of death. Nevertheless, post-mortem diagnostic imaging has recently gained popularity as a minimally invasive means of diagnosing the cause of death (COD). Notably, there is religious opposition to CA among the Muslim communities in Malaysia. Hence, the method of identifying the COD by performing minimally invasive autopsies (MIA) utilising imaging methods, i.e., by ‘virtual autopsy’ is preferred less mutilating of the human form is involved. There are different types of post-mortem imaging modalities that can be applied to perform MIA. The choices are based on the mechanism of death and the condition of the corpse i.e. the degree of decomposition or mutilation. These modalities include conventional x-ray, post-mortem computed tomography (PMCT), post-mortem computed tomography angiography (PMCTA), post-mortem magnetic resonance imaging (PMMR), fluoroscopy and positron emission tomography computed tomography (PET/CT).

MIA is commonly performed by PMCT, which is the most cost-effective and easy to interpret modality. There are different imaging techniques that are utilised, which can provide improved diagnostic accuracy for various types of injuries.² The main purpose of using radiology techniques in criminological sciences is usually to define traumatic COD such as lethal gunshot injuries. Historically, post-mortem radiology was performed using conventional x-ray modality, which lessens a 3D body to a 2D prediction. The detection of the location of the bullet or its remains in the body is the main role of this technique, although it has many limitations leading to erroneous interpretations.

Recently, there has been a great improvement in radiology techniques due to the introduction of cross-sectional imaging

Corresponding Author: Prof. Dr Rozi Mahmud

Email: rozi@upm.edu.my

techniques, such as Multi-Detector Computed Tomography (MDCT) and this can provide a means of improved resolution, 3D volume rendering techniques for pathology localisation, and optimal quantification of various disease processes.^{3,4} PMCT using MDCT techniques provides a detailed explanation about the bodily internal injuries to the forensic pathologists enabling them to define cases with gunshot wounds. Hence, there is improved localisation of bullets and/or the shrapnel in the corpse,² which enables improved accuracy of identifying the type of ballistic weapon and ammunition that had been used in the attack. Moreover, PMCT allows the pathologist to obtain critical information, such as accurate illustration of the wound, discriminating between entry and exit wounds, and the associated soft tissue and bone fractures inside the body.⁵

The aim of this review is to identify the incremental benefit of imaging modalities that complement routine autopsy, particularly PMCT, PMCTA, and PMMR. We also aimed to correlate the findings of these virtual autopsy methods with conventional autopsy results that can help improve the accuracy of managing the medicolegal aspects of unexplained or unnatural deaths. Additionally, we highlight the role of PMCT based on the Malaysian experience.

METHODOLOGY

Data used in this review article was collected as a narrative review sourced from Scopus, Ovid and PubMed databases. The data from 18 articles were extracted and categorised according to the imaging modalities and organs systems; to highlight the articles based on the incremental benefit provided by the type of imaging modalities and their indications, the number of cases recruited by the particular studies, and the potential advantages and limitations of the various techniques.

RESULTS AND DISCUSSION

Our results rely on the findings of post-mortem diagnostic imaging studies from literature, which can be classified according to modality types and organ systems in the body. The different modalities have their own unique advantages and limitations in the process of identifying the mechanism of injury and ultimately diagnosing the COD.

Post-mortem computed tomography (PMCT)

This is the most widely utilised technique ever since the development of MDCT scans that provide fast imaging with relatively affordable costs. MDCT scans allow tissue densities from various organs to be assessed for pathology based on their Hounsfield units.^{4,6} Previously post-mortem radiographs were taken and compared with antemortem x-rays for determining the identity of unknown dead corpses. Currently, the technology of PMCT enables experienced forensic radiologists to determine dental patterns and estimate weight and height for improved identification of macerated dead bodies.⁷ Some of the main indications of PMCT include identification of macerated corpses, determination of the COD, particularly in sudden death when the cause of death is unclear, and death from unnatural causes such as lethal gunshot injuries.⁸ The scan involves performing CT imaging

of the supine dead body taken from the vertex then extending caudally to the tip of the corpse's toes. Volume rendering techniques (VRT) are utilised to depict the skeletal system in a 3D form. A second scan is performed with a smaller field of view (FOV) covering the head and neck regions, to provide better resolution of these body regions.⁹ The third and last scan is performed with the arms elevated by the side of the head, to image the thorax and abdomen whilst minimising beam hardening artifacts.

Post-mortem computed tomography angiography (PMCTA) This technique was developed to address the limitations of PMCT, which include relatively poor soft-tissue contrast and difficulty in viewing and assessing vascular structures. Whole-body PMCTA using a heart-lung bypass machine and selective angiography i.e. targeted CT angiography of the coronary vessels have been successfully conducted to identify vascular injuries and assess cardiac COD.^{10,11} Multi-phase PMCTA is a technique developed by Grabherr et al., 2011 that utilizes a standardised method of injecting a pre-defined speed and volume of a specific lipophilic contrast-agent mixture into cadavers for post mortem CT imaging.¹² The mixture consists of the oily liquid Angiofil® (Fumedica AG, Muri, Switzerland) and paraffin oil (paraffinum liquidum), that has the advantage of being retained in the vascular compartment and not affected by the transudation process, which generally affects pre-existing hydrophilic body fluids.^{12,13} Frankenberg et al, 2015 described a multiphase PMCTA scan which included an unenhanced scan, an arterial phase that was taken directly after the contrast media was injected through the cannulated femoral artery, and a venous phase which was taken during continuous injection of the contrast media.¹³ Scanning was performed using a dual-source CT scan technique and 1mm-slice thickness images were reconstructed in soft/smooth and medium-hard convolutional kernels.¹³ An alternative PMCTA technique includes CT-guided percutaneous puncture and direct injection of contrast into the left cardiac ventricle after localisation by unenhanced CT scan, which enables whole-body imaging by introducing a larger volume of contrast at a higher injection rate.¹⁴

The advantages of PMCTA include better soft-tissue contrast that enables delineation of internal solid organ injuries and vascular-related injuries. Internal injuries such as splenic laceration leading to massive haemorrhage are immediately apparent on PMCTA imaging (Figure 1A). Evidence of contrast media extravasation and hemoperitoneum gives clues to lethal vascular injuries, ergo the COD (Figure 1B). PMCTA is also advantageous in identifying coronary vessels stenosis, intravascular plaques and calcifications that may indicate a cardiac event as the COD.¹⁰ Nevertheless, it is important to note that there are some limitations and pitfalls that can occur in PMCT and PMCTA imaging. Post mortem blood clots ('*cruor mortis*') may be misinterpreted on PMCTA as intravascular thrombus causing myocardial infarction.¹⁵ This can be overcome by observing whether the clots are non-adherent to the vessel wall or presence of contrast media surrounding the clots, which indicate '*cruor mortis*'.¹⁵ The sedimentation effect that occurs in the blood vessels of cadavers are typical post-mortem changes, as with the occurrence of hypostasis in the lungs known as '*inner livor mortis*';

Table I: Post mortem studies investigating the role of PMCT and PMCTA in the cardiovascular cause of death

Author (Year)	Type of Imaging	Cases	Type of subjects	Virtopsy Findings	Comparative Autopsy
Han (6)	PMCTA	8	SCD	Cut-off of HU <75 for LAP correlated with lipid-rich plaques on autopsy HPE: sensitivity: 55.6%, NPV 75.9%	Good correlation with PMCTA findings
Rutty (23)	PMCTA	210	natural or non-suspicious, unnatural causes of death	Better identification of trauma and haemorrhage	Good correlation with PMCTA findings
Vogel (24)	PMCT & PMCTA	139	death post-cardiac surgery	PMCT noted pseudo-arthrooses due to median sternotomy; PMCTA localised trans-vascular implanted valves, cardiac tamponade, & showed many sources of bleeding evidenced by extravasation of contrast that indicated coagulopathy as COD	Unable to demonstrate aorta, coronary vessels and bypass grafts well compared to imaging
Shao (14)	PMCT & PMCTA	12	cadavers with no history of vascular disease	Left ventricular cardiac puncture enables the better depiction of vascular structures and aids in the detection of intracranial aneurysms and stenosis and potential sources of haemorrhage	the limitations of conventional autopsy i.e. time-consuming procedure & requiring specialised equipment can be overcome with good PMCTA technique

Table II: Post-mortem studies investigating the role of PMCT and PMCTA in the central nervous system

Author (Year)	Type of Imaging	Subject	Type of subjects	Virtopsy Findings	Comparative Autopsy
Chatzaraki (27)	PMCT	21	pedestrians with COD bein fatal road traffic accident	better at detection of facial and skull fractures	better for detection of soft tissue hemorrhages
Graziani (28)	PMCT	203	trauma and non-trauma-related fatalities with indeterminate COD	PMCT has a high correlation for identification of skull fractures, VH, & SAH	an autopsy was superior at detection of epidural and small subdural hemorrhages
Jacobsen (29)	PMCT	56	trauma cases with evidence of neurocranium injury	thin sliced CT (3mm) was better at identifying middle cranial fossa fractures	an autopsy was better at detecting unilateral frontal bone fractures
Sabale (30)	PMCT	300	Fatal head injury cases	CT scan in axial view alone had limitations in diagnosing linear and depressed skull fractures, particularly in the occipital region	an autopsy was better at identifying linear posterior fossa skull fractures

all of which may mimic real pathologies.¹⁶ Another limitation of PMCTA is due to incomplete thawing of the corpse or advanced state of putrefaction, which may lead to artifacts and non-visualisation of some of the branches of the aorta.¹⁴

Post-mortem magnetic resonance imaging (PMMR)

PMMR, although not as commonly utilised as PMCT, provides an alternative imaging method for post-mortem diagnosis of COD. It is superior as it provides details of the soft tissues of the spine, head and neck region, abdomen and cardiovascular system, but is limited by the high-cost factor for acquiring a scanner used in dedicated post mortem imaging, long duration of scanning time, combined with the difficulty and expertise needed for its interpretation.¹⁷

Furthermore, there are no set sequences or protocols for PMMR due to the limited number of studies conducted. Additionally, the heterogeneity in local practices for performing this examination causes challenges in determining a standardised imaging protocol. Despite these, T1-weighted and T2-weighted imaging are the

commoner sequences utilised in most centres. Nevertheless, the poor contrast resolution on T1-weighted images and the changes that occur in macerated tissue, which can alter the appearance on T2-weighted images may pose challenges in the interpretation of scans. Other factors, including reduced body temperature of corpses, lead to reduction in T1 and T2 signals that affect the image contrast, require some tweaking of the sequence settings to suit post-mortem conditions.¹⁸

PMMR is particularly useful in post-mortem brain imaging as it provides an advantage in identifying some anatomical details that appear as liquefaction on PMCT.¹⁹ PMMR has also been increasingly used in paediatric post-mortem imaging. In fact, PMMR has an excellent correlation with conventional autopsy in foetuses and has a good correlation with the COD in infants compared to older children.²⁰

Additionally, there is a superior quality of PMMR to diagnose the COD due to adverse cardiac events. Particularly, PMMR is better at detecting myocardial ischemia, myocardial injury and cardiac contusions.²¹ PMCT, however, is frequently useful in detection of calcifications in the coronary vessels and aorta

Table III: Post-mortem studies investigating the role of PMCT and PMCTA in death by gunshot injuries

Author (Year)	Type of Imaging	Subjects	Type of subjects	Virtopsy Findings	Comparative Autopsy
Kirchoff (32)	PMCT	51	gunshot victims	PMCT better visualises projectile fragments/ shrapnel. May misinterpret the entry & exit wounds due to tissue alterations caused by extrinsic compression by adjacent tissues & supine positional for the scan, which may differ from the actual position at the time of death.	An autopsy is more accurate in detecting multiple gunshots that occur in a single body cavity.
Le Blanc-inLouvry (33)	PMCT	236	mainly traumatic COD, 26 victims with gunshot wounds	Accurate in detecting lethal wounds caused by gunshot wounds and cranial trauma. Additional CT reconstructions were useful in detecting the base of skull fractures.	Discordance of the two tests detecting vascular and intra-abdominal injuries due to the limitations of unenhanced PMCT.
Makhlouf (34)	PMCT	47	gunshot victims	Better detection of pneumothorax & gas embolism. In cases of multiple projectiles especially going through similar routes and same body cavities leads to taking inventory of injuries only, with limited to nil ballistic interpretation.	Able to identify and recover more bullets; identify the type of ammunition used and the trajectory of projectiles better. Superior in detecting injury to the diaphragm, liver, and spleen.
Scaparra (35)	PMCT	41	lethal gunshot injury to the	Helps to rule out falsely negative cases of blood aspiration into the airways in cases of lethal gunshot injuries to the head.	Good correlation of red spots in the lung parenchyma detected by autopsy with GGO detected on PMCT. Misinterpretations can occur due to aspirated gastric content giving GGO that may mimic blood aspiration.
Thali (36)	PMCT and PMMR	8	lethal gunshot injury to the head/ torso	PMCT provides graphical details using various techniques i.e. MPR and SSD that allow better identification of entrance (inward beveling) and exit wounds (outward beveling) on the bones. PMMR is useful in giving improved soft tissue resolution, however caution needs to be exercised in confirming whether the projectiles in the corpses are ferromagnetic or not prior to MR scanning.	Lack of color confirmations leads to an inferior interpretation of superficial injuries at virtopsy, thus making autopsy correlation indispensable.

Table IV: Post-mortem studies investigating the role of PMCT, PMCTA, and PMMR in paediatric and perinatal death

Author (Year)	Type of Imaging	Subject	Type of subjects	Virtopsy Findings	Comparative Autopsy
Arthur (2015)	PMMR	400	Perinatal and paediatric cases	PMMR: good at detecting renal abnormalities. A high degree of falsely positive finding for intestinal pathology.	PMMR detected bowel dilatation might reflect normal Post-mortem changes as no corresponding lesions were seen at autopsy.
Ashwin (2017) (38)	PMMR	201	Perinatal death with multi-organ involvement	Overall diagnostic accuracy of PMMR was 89.6% (95% CI: 84.3-93.2%)	Best concordance of PMMR with autopsy in neurological pathologies.
Goergen (2019) (39)	iuMR, PMMR	13	Foetuses with complex brain pathology	PMMR missed neuronal migration and abnormalities in the cerebellum.	iuMR may be preferred to improve fetal phenotyping in lethal congenital malformations to give better concordance with autopsy.
Izzo (2019) (40)	iuMR, PMMR	53	Foetuses with suspected brain pathology	PMMR performed >24 hours after foetal expulsion may lead to discordance with iuMR and autopsy report due to cerebral distortion and collapse of CSF-containing structures.	It is recommended to perform PMMR within 24 hours of expulsion to minimise the discordance caused by cerebral distortion phenomena.
Papadopoulou (2016) (41)	PMMR	43	Perinatal death: assessment of foetal brain changes	ADC values correlated well with maceration score.	ADC may aid in the estimation of the degree of maceration in cases where gestational stage or post-mortem interval are indeterminate.

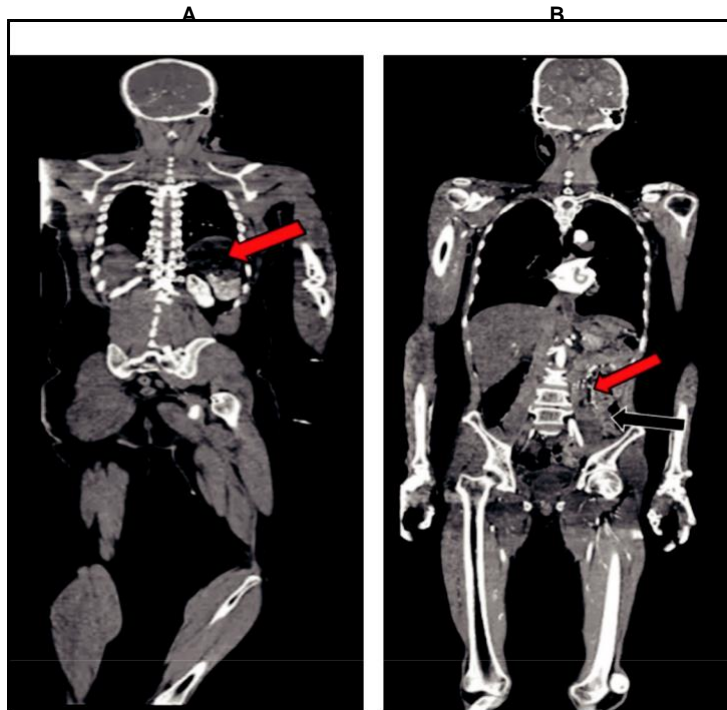


Fig. 1: a) Coronal view PMCTA in portovenous phase showing splenic laceration. The advantages of PMCTA include better soft-tissue contrast that enables delineation of internal solid organ injuries and vascular-related injuries. Internal injuries such as splenic laceration leading to massive haemorrhage are immediately apparent on PMCTA imaging (red arrow).b) Figure Coronal view PMCTA showing contrast media extravasation and hemoperitoneum. Evidence of contrast media extravasation (red arrows) and hemoperitoneum (black arrow) gives clues to lethal vascular injuries, ergo the COD.

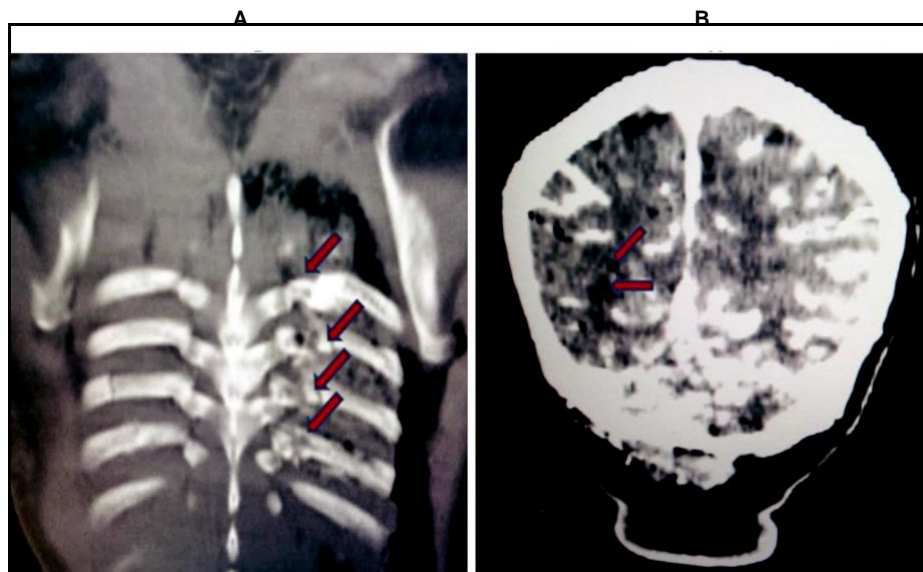


Fig. 2: a) PMCTA showing multiple ribs fractures and pneumothorax in an adult man with lethal traumatic injury to the chest as indicated by the red arrows b) PMCTA brain showing intravascular gas formation and loss of definition of cerebral sulci (demonstrated by the red arrows).

caused by atherosclerosis, myocardial hypertrophy and calcifications of the heart valves, which may point to a non-traumatic cardiac COD even in cases that had history of trauma prior to death.²²

Post-mortem imaging of the cardiovascular system

The major limitation of PMCT is the poor soft-tissue resolution, which makes the detection of intravascular thrombus and cardiac vascular stenosis difficult to detect. Hence, this created an impetus for the utility of PMCTA (Table I). In a system where the vascular

flow has most likely clotted, as is the case in corpses brought in for investigation of COD, it is necessary to introduce contrast media using a powerful injector and taking the images at the correct phase of time. With successful expansion of the learning curve for PMCTA interpretation, some researchers have reported a success rate of 92% for the identification of COD implying the feasibility of its use in a specialist setting may avoid the need for conventional autopsies in certain instances.²³ Generally, PMCTA is better at identifying COD due to traumatic injuries and hemorrhages.^{6,14,23,24} As PMCT is superior in identification of air and fractures, it is suitably advantageous to be utilised to quickly identify multiple rib fractures and pneumothorax (Figure 3A).

Post-mortem imaging of the central nervous system Post-mortem putrefaction of the brain parenchyma leads to numerous artifacts that pose a challenge for both conventional and virtual autopsy. Early putrefaction of the brain can be evidenced by the intravascular gas formation and loss of appreciable cerebral sulci as seen on PMCT.²⁵ Figure 3B shows PMCT of the brain with linearly arranged air pockets consistent with intravascular gas formation giving evidence of early putrefaction changes. Alternatively, PMMR provides an advantage for better soft-tissue resolution and identification of pathology. T1-weighted gradient-echo sequence is particularly useful in detecting blooming artifacts in cases of diffuse axonal injury of the brain.²⁶ Nevertheless, the role of PMCT is indispensable in its ability to detect cranial and facial bone fractures as well as intraventricular hemorrhages (IVH) as shown in several studies²⁷⁻³⁰ in Table II.

Assessment of death by gunshot injury

Conventionally x-rays have been a cornerstone modality for the management of death caused by gunshot wounds. The high speed of projectiles causing fatal tissue injuries can be better imaged with PMCT. PMCT has currently taken over most of the imaging functions of plain radiographs as it enables 3D assessment of the sequences of the gunshots and the ballistic trajectory.³¹ The 3D reconstructed images also enable the detection of foreign bodies along the bullet pathway, which represent secondary projectiles, bullet fragments and estimation of the victim's position at the time of injury. The common interpretation of gunshot injuries includes observing the 'keyhole defect' which denotes the internal bevelling caused by the entry point of the missile; followed by external bevelling of bone at the exit lesion. Gas found along the trajectory of the bullets, which occur as a result of either the passage of the bullets through a hollow organ or causing viscus perforation as a result of the cavitation effect of the missiles, is also better delineated on PMCT. Nevertheless, there are some inherent limitations of PMCT or rather advantages of conventional autopsy, namely the retrieval of the bullets, estimating whether there was any lapse of interval from the time of the shot and time of death, and to confirm the entry and exit lesions.³² Table III shows several relevant studies³²⁻³⁶ involving comparison of post-mortem imaging with conventional autopsy in cases of lethal gunshot injury.

Assessment of pediatric and perinatal death by utilising PMMR

Post-mortem MRI (PMMR) has been gaining popularity for perinatal and paediatric cases as it gives excellent soft-tissue details in the small structures of the paediatric age group subjects. The internal organs of foetal corpses can be clearly visualised and display in 3D for virtual dissection and identification of brain pathology, cardiac-related adverse events and genitourinary pathology.¹⁸ In fact, PMMR has been noted to detect approximately 33% more pathological anomalies as compared to PMCT.³⁷ Apart from the conventional standard sequences for MR imaging i.e. T1-weighted and T2-weighted sequences, susceptibility-weighted imaging (SWI) and Diffusion-weighted imaging (DWI) can be utilised for foetal and paediatric post mortem imaging. The former is beneficial for detecting haemorrhage and iron storage in organs particularly in trauma cases, identification of venous blood and vascular malformations for example cavernomas and the latter is good for the assessment of the degree of maceration (Table IV). Table IV depicts PMMR studies done on foetal or paediatric cases.³⁷⁻⁴¹

Additionally, recent researches have also focused on the application of PMCT for disaster victim identification (DVI) by measuring the height and weight of the corpses as it can reduce the time taken to identify the victims, reduce the number of on-site personnel and minimize the number of modalities utilised.⁴² Commonly utilised body parts for height estimation include long bones such as the femur^{43,44} and body size estimation using abdominal adipose fat or visceral fat layer.⁴⁵ Most previous studies have used dental examination correlated with antemortem dental records for disaster victim identification.⁴⁶ Additional advantages of post mortem imaging are that it enables repeated analyses of the data to be conducted unlike conventional autopsy.²⁴ Furthermore, teleradiology services allow for data transfer for remote consultation and sharing of information particularly in medicolegal cases. Multi-planar and 3D reconstructions, aid in portraying the data in a format easily understood by the layperson. PMCTA allows for an added dimension of identifying vascular-related COD.

Post-mortem imaging in Malaysia

With Islam (a comment on other faiths?) being the official religion of Malaysia, there are many religious and cultural aversions to post mortem conventional autopsy. There may be objections from family members towards performing any invasive procedures on their deceased relative and a need for quick release of the corpse to perform the final rites. Furthermore, post mortem imaging allows an initial assessment of whether conventional autopsy will be necessary such as death by strangulation indicated by CT detected hyoid bone fracture, depiction, localisation, and retrieval of medical devices that may indicate potential medical misconduct or negligence, and identification of possible intoxication as evidenced by tablets in the stomach or drug containers in the bowels.¹⁶

PMCT is particularly acceptable in the Asian populations as it can be a useful and accurate method for non-invasive assessment and scoring of the Abbreviated Injury Scale (AIS). It permits the categorisation of injuries in a standardised

manner and allows quantification of injuries that contributed to the COD, as provides an objective way for comparison between post-mortem imaging and conventional autopsy.⁴⁷ Ultimately, the aim is to stratify the cases that may be spared a conventional autopsy, provided the COD has been satisfactorily answered by post-mortem imaging. In Malaysia, the first post-mortem imaging study was published in 2016. This retrospective study included 61 multi-racial cadavers involved in lethal road traffic accidents, with a predominance of the Malay race as subjects (38%).⁴⁸ There were false-negative results for the detection of minor liver and splenic injuries caused by the poor soft-tissue resolution of the unenhanced PMCT scans. Furthermore, we attest to the fact that there were artifacts to the upper abdomen, which was caused by the forearms of the corpses being placed anteriorly in this region for cultural reasons. They recommended that future studies should change the standard positioning of the cadavers for imaging and assured that the post-mortem imaging did not lead to any undue delays in the release of the bodies for ritual burial.⁴⁸

A prospective PMCT study, involving a researcher from Malaysia and an Italian team, was conducted from 2011 to 2015 involving cadavers from Italy. This study reported that Malaysia has state-of-the-art technology and equipment for post mortem image assessment and virtual dissection.⁴⁹ The study analysed 25 PMCT cases correlated with conventional autopsy acquired from the Forensic Pathology section of the Department of Diagnostics and Public Health, University and Hospital Trust of Verona, Italy; converted to the Digital Imaging and Communications in Medicine (DICOM) format and were transferred to iGene (Kuala Lumpur, Malaysia). iGene, a company that specializes in digital virtual autopsies, post-processed the images using their custom-built, comprehensive, proprietary INFOPSY® iDASS™ system software, whereby 3D images and volume-rendered images were displayed. iDASS™ enabled the users to do volume rendering and real-time viewing of the digital body from the 3000–5000 DICOM image slices obtained from PMCT, which enabled the pathologists to conduct a full, non-invasive virtual post-mortem examination using a large display, touch-screen computer. Overall, 64% of the virtual autopsy results for COD matched the findings of conventional autopsy.⁴⁹

Overall, it can be noted that much progress has been made in the field of forensic radiology in Malaysia, specifically at the Institut Perubatan Forensik Negara (IPFN), Kuala Lumpur General Hospital. A Malaysian forensic imaging study involved the evaluation of calcium scoring on 155 unenhanced PMCT scans conducted on cases of sudden death, identified a significantly higher calcium score among both young and older adults who were identified with coronary artery disease on conventional autopsy.⁵⁰ Another study published by Omar et al., 2018 investigated the role of PMCTA in the evaluation of luminal stenosis of the coronary arteries with histopathological correlation. The study identified that the percentage of luminal stenosis of the coronary vessels as measured by PMCTA-related software, underestimated the luminal patency as compared to histological assessment. They advocated reporting luminal patency on PMCTA with caution, as the stenosis could be

underestimated, particularly if the atherosclerotic lesion was small and caused less than 50% narrowing of the vessel diameter.⁵¹

There is also increasing expertise among clinicians in Malaysian in the field of forensic medicine, for instance, a renowned Malaysian expert was involved in a working group that advocated the correct clinical indications for post-mortem radiography. The group comprising of worldwide experts including Malaysian-born Dr. Mansharan Kaur Chainchel Singh, recommended that the aim of post-mortem imaging would be for Disaster Victim Identification (DVI), identification of the COD, identifying potential hazardous materials within the body, and gathering evidence in medicolegal/criminal justice procedures.⁵²

CONCLUSION

Post-mortem imaging using CT and MRI scans permit a non-invasive technique for victim identification, determining the aetiology and depicting the pathogenic mechanism of lethal injury; particularly for traumatic or unnatural causes of death. Post-mortem CT angiography is particularly useful for the identification of vascular injury and death due to adverse coronary events. The improvisation of these methods has evolved tremendously in the past decade and gives promise to potentially replacing conventional autopsy in relevant instances. Nevertheless, there is a need for standardisation of imaging techniques and reporting templates to enable the technology to be better utilised and incorporated in routine forensic medicine modus operandi.

REFERENCES

1. Roberts IS, Benamore RE, Benbow EW, Lee SH, Harris JN, Jackson A, et al. Post-mortem imaging as an alternative to autopsy in the diagnosis of adult deaths: a validation study. *Lancet* 2012; 379(9811): 136-42.
2. Femia G, Semsarian C, Langlois N, McGuire M, Raleigh J, Taylor A, et al. Post-Mortem Imaging Adjudicated Sudden Death: Causes and Controversies. *Heart Lung Circ* 2019; 28(1): 15-21.
3. Grabherr S, Egger C, Vilarino R, Campana L, Jotterand M, Dedouit F. Modern post-mortem imaging: an update on recent developments. *Forensic Sci Res* 2017; 2(2): 52-64.
4. Suppiah S, Chow LRM, Sazali NSB, Hassan HA. Non-alcoholic fatty liver disease in metabolic syndrome patients in Serdang Hospital: Quantification by contrast-enhanced computed tomography. *Malaysian Journal of Medicine and Health Sciences*. 2016; 12(1): 9-18.
5. Wojciechowski A, Fudalej M, Skowronek P. Assessment of head gunshot wounds by means of post-mortem computed tomography in exhumed anonymous cadaver. *BJR Case Rep* 2016; 2(4): 20150304.
6. Han D, Torii S, Yahagi K, Lin FY, Lee JH, Rizvi A, et al. Quantitative measurement of lipid rich plaque by coronary computed tomography angiography: A correlation of histology in sudden cardiac death. *Atherosclerosis* 2018; 275: 426-33.
7. Brough AL, Morgan B, Rutty GN. Postmortem computed tomography (PMCT) and disaster victim identification. *Radiol Med* 2015; 120(9): 866-73.
8. Weustink AC, Hunink MG, van Dijke CF, Renken NS, Krestin GP, Oosterhuis JW. Minimally invasive autopsy: an alternative to conventional autopsy? *Radiology* 2009; 250(3): 897-904.
9. Filograna L, Pugliese L, Muto M, Tatulli D, Guglielmi G, Thali MJ, et al. A Practical Guide to Virtual Autopsy: Why, When and How. *Semin Ultrasound CT MR* 2019; 40(1): 56-66.
10. Takei H, Sano R, Takahashi Y, Takahashi K, Kominato Y, Tokue H, et al. Usefulness of coronary postmortem computed tomography angiography to detect lesions in the coronary artery and myocardium in cases of sudden death. *Legal Med (Tokyo)* 2018; 30: 46-51.
11. Palmiere C, Lohrinus JA, Mangin P, Grabherr S. Detection of coronary thrombosis after multi-phase postmortem CT-angiography. *Legal Med (Tokyo)* 2013; 15(1): 12-8.

12. Grabherr S, Doenz F, Steger B, Dirnhofer R, Dominguez A, Sollberger B, et al. Multi-phase post-mortem CT angiography: development of a standardized protocol. *Int J Legal Med* 2011; 125(6): 791-802.
13. Franckenberg S, Flach PM, Gascho D, Thali MJ, Ross SG. Postmortem computed tomography-angiography (PMCTA) in decomposed bodies – A feasibility study. *Journal of Forensic Radiology and Imaging*. 2015; 3(4): 226-34.
14. Shao Y, Wan L, Zhang J, Li Z, Liu N, Huang P, et al. Post-mortem computed tomography angiography using left ventricle cardiac puncture: A whole-body, angiographic approach. *PLoS One* 2017; 12(8): e0183408.
15. Westphal SE, Apitzsch JC, Penzkofer T, Kuhl CK, Mahnken AH, Knüchel R. Contrast-enhanced postmortem computed tomography in clinical pathology: enhanced value of 20 clinical autopsies. *Human Pathology* 2014; 45(9): 1813-23.
16. Flach PM, Gascho D, Schweitzer W, Ruder TD, Berger N, Ross SG, et al. Imaging in forensic radiology: an illustrated guide for postmortem computed tomography technique and protocols. *Forensic Sci Med Pathol* 2014; 10(4): 583-606.
17. Decker SJ, Braileanu M, Dey C, Lenchik L, Pickup M, Powell J, et al. Forensic Radiology: A Primer. *Acad Radiol* 2019; 26(6): 820-30.
18. Addison S, Arthurs OJ, Thayyil S. Post-mortem MRI as an alternative to non-forensic autopsy in fetuses and children: from research into clinical practice. *Br J Radiol* 2014; 87(1036): 20130621.
19. Ruder TD, Thali MJ, Hatch GM. Essentials of forensic post-mortem MR imaging in adults. *Br J Radiol* 2014; 87(1036): 20130567.
20. Thayyil S, Sebire NJ, Chitty LS, Wade A, Olsen O, Gunny RS, et al. Post mortem magnetic resonance imaging in the fetus, infant and child: a comparative study with conventional autopsy (MaRIAS Protocol). *BMC Pediatr* 2011; 11: 120.
21. Jackowski C, Schwendener N, Grabherr S, Persson A. Post-Mortem Cardiac 3-T Magnetic Resonance Imaging: Visualization of Sudden Cardiac Death? *J Am Coll Cardiol* 2013; 62(7): 617-29.
22. Panda A, Kumar A, Gamanagatti S, Mishra B. Virtopsy Computed Tomography in Trauma: Normal Postmortem Changes and Pathologic Spectrum of Findings. *Curr Probl Diagn Radiol* 2015; 44(5): 391-406.
23. Ruttly GN, Morgan B, Robinson C, Raj V, Pakkal M, Amoroso J, et al. Diagnostic accuracy of post-mortem CT with targeted coronary angiography versus autopsy for coroner-requested post-mortem investigations: a prospective, masked, comparison study. *Lancet* 2017; 390(10090): 145-54.
24. Vogel B, Heinemann A, Tzikas A, Poodendaen C, Gulbins H, Reichensperner H, et al. Post-mortem computed tomography (PMCT) and PMCT-angiography after cardiac surgery. Possibilities and limits. *Arch Med Sadowej Kryminol*. 2013;63(3):155-171.
25. Offiah CE, Dean J. Post-mortem CT and MRI: appropriate post-mortem imaging appearances and changes related to cardiopulmonary resuscitation. *Br J Radiol* 2016; 89(1058): 20150851.
26. Makino Y, Arai N, Hoshioka Y, Yoshida M, Kojima M, Horikoshi T, et al. Traumatic axonal injury revealed by postmortem magnetic resonance imaging: A case report. *Leg Med (Tokyo)* 2019; 36: 9-16.
27. Chatzaraki V, Thali MJ, Ampanozi G, Schweitzer W. Fatal road traffic vehicle collisions with pedestrian victims: forensic postmortem computed tomography and autopsy correlation. *Am J Forensic Med Pathol* 2018; 39(2): 130-40.
28. Graziani G, Tal S, Adelman A, Kugel C, Bdolah-Abram T, Krispin A. Usefulness of unenhanced post mortem computed tomography - Findings in postmortem non-contrast computed tomography of the head, neck and spine compared to traditional medicolegal autopsy. *J Forensic Leg Med* 2018; 55: 105-11.
29. Jacobsen C, Lynnerup N. Craniocerebral trauma--congruence between post-mortem computed tomography diagnoses and autopsy results: a 2-year retrospective study. *Forensic Sci Int* 2010; 194(1-3): 9-14.
30. Sabale MR, Kumar NB, Kukde HG, Jaiswani AK. Comparative analysis of computed tomography scan and post mortem findings in cases of head injury at a tertiary health centre. *Indian Journal of Forensic Medicine and Toxicology*. 2019; 13(1): 144-9.
31. Delteil C, Gach P, Ben Nejma N, Capasso F, Perich P, Massiani P, et al. Tangential cranial ballistic impact: An illustration of the limitations of post-mortem CT scan? *Legal Med (Tokyo)* 2018; 32: 61-5.
32. Kirchhoff SM, Scaparra EF, Grimm J, Scherr M, Graw M, Reiser MF, et al. Postmortem computed tomography (PMCT) and autopsy in deadly gunshot wounds--a comparative study. *Int J Legal Med* 2016; 130(3): 819-26.
33. Le Blanc-Louvy I, Thureau S, Duval C, Papin-Lefebvre F, Thiebot J, Dacher JN, et al. Post-mortem computed tomography compared to forensic autopsy findings: a French experience. *Eur Radiol* 2013; 23(7): 1829-35.
34. Makhoulouf F, Scolas V, Ferretti G, Stahl C, Paysant F. Gunshot fatalities: correlation between post-mortem multi-slice computed tomography and autopsy findings: a 30-months retrospective study. *Leg Med (Tokyo)* 2013; 15(3): 145-8.
35. Scaparra E, Peschel O, Kirchhoff C, Reiser M, Kirchhoff SM. Detection of blood aspiration in deadly head gunshots comparing postmortem computed tomography (PMCT) and autopsy. *Eur J Med Res* 2016; 21(1): 43.
36. Thali MJ, Yen K, Vock P, Ozdoba C, Kneubuehl BP, Sonnenschein M, et al. Image-guided virtual autopsy findings of gunshot victims performed with multi-slice computed tomography (MSCT) and magnetic resonance imaging (MRI) and subsequent correlation between radiology and autopsy findings. *Forensic Sci Int* 2003; 138(1-3): 8-16.
37. Arthurs OJ, Guy A, Thayyil S, Wade A, Jones R, Norman W, et al. Comparison of diagnostic performance for perinatal and paediatric post-mortem imaging: CT versus MRI. *Eur Radiol* 2016; 26(7): 2327-36.
38. Ashwin C, Hutchinson JC, Kang X, Langan D, Jones R, Norman W, et al. Learning effect on perinatal post-mortem magnetic resonance imaging reporting: single reporter diagnostic accuracy of 200 cases. *Prenat Diagn* 2017; 37(6): 566-74.
39. Goergen SK, Alibrahim E, Govender N, Stanislavsky A, Abel C, Prystupa S, et al. Diagnostic assessment of foetal brain malformations with intra-uterine MRI versus perinatal post-mortem MRI. *Neuroradiology*. 2019.
40. Izzo G, Talenti G, Falanga G, Moscatelli M, Conte G, Scola E, et al. Intrauterine fetal MR versus postmortem MR imaging after therapeutic termination of pregnancy: evaluation of the concordance in the detection of brain abnormalities at early gestational stage. *Eur Radiol* 2019; 29(6): 2740-50.
41. Papadopoulou I, Langan D, Sebire NJ, Jacques TS, Arthurs OJ. Diffusion-weighted post-mortem magnetic resonance imaging of the human fetal brain in situ. *Eur J Radiol* 2016; 85(6): 1167-73.
42. Brough AL, Morgan B, Ruttly GN. The basics of disaster victim identification. *Journal of Forensic Radiology and Imaging*. 2015; 3(1): 29-37.
43. Zech WD, Naf M, Siegmund F, Jackowski C, Losch S. Body height estimation from post-mortem CT femoral F1 measurements in a contemporary Swiss population. *Leg Med (Tokyo)*. 2016; 19: 61-6.
44. Chiba F, Makino Y, Torimitsu S, Motomura A, Inokuchi G, Ishii N, et al. Stature estimation based on femoral measurements in the modern Japanese population: a cadaveric study using multidetector computed tomography. *Int J Legal Med*. 2018; 132(5): 1485-91.
45. Srikumar T, Siegel EM, Gu Y, Balagurunathan Y, Garcia AL, Chen YA, et al. Semiautomated Measure of Abdominal Adiposity Using Computed Tomography Scan Analysis. *J Surg Res* 2019; 237: 12-21.
46. Nguyen E, Doyle E. Dental Post-mortem Computed Tomography for Disaster Victim Identification: A literature review. *Journal of Forensic Radiology and Imaging* 2018; 13: 5-11.
47. Jalalzadeh H, Giannakopoulos GF, Berger FH, Fronczek J, van de Goot FRW, Reijnders UJ, et al. Post-mortem imaging compared with autopsy in trauma victims--A systematic review. *Forensic Sci Int* 2015; 257: 29-48.
48. Bakar NA SN, Mohammad Nor MH, Zainon KA. The sensitivity, specificity and predictive values of post mortem computed tomography in detecting liver and splenic injury due to road traffic accident. *Med J Malaysia* 2016; 71(1): 1-7.
49. Cirielli V, Cima L, Bortolotti F, Narayanasamy M, Scarpelli MP, Danzi O, et al. Virtual Autopsy as a Screening Test Before Traditional Autopsy: The Verona Experience on 25 Cases. *J Pathol Inform* 2018; 9: 28.
50. Omar E, Faizuddin R, Mansharan K, Razuin R, Mahmood MS, Nurliza A, et al. Prevalence of coronary artery disease in young sudden death cases and correlation with post-mortem computed tomography calcium score. *Journal of Clinical and Health Sciences*. 2018; 3(1): 27-32.
51. Omar E, Singh MKC, Nawawi HM. Post Mortem Computed Tomography Angiographic Underestimates Coronary Artery Luminal Stenosis Compared to Histopathological Examination of the Same: Report of A Preliminary Finding. *International Journal of Cardiology*. 2018; 273: 18.
52. Viner MD, Almiyah A, Apostol M, Brough A, Develter W, O'Donnell C, et al. Use of radiography and fluoroscopy in Disaster Victim Identification. Positional statement of the members of the Disaster Victim Identification working group of the International Society of Forensic Radiology and Imaging. *Journal of Forensic Radiology and Imaging*. 2015; 3(2): 141-5.