

# A case of severe *Plasmodium knowlesi* malaria in a post-splenectomy patient

Seng Wee Cheo, MRCP<sup>1</sup>, Tee Tat Khoo, MRCP<sup>2</sup>, Yee Ann Tan, MRCP<sup>2</sup>, Whei Chuern Yeoh, MRCP<sup>2</sup>, Qin Jian Low, MRCP<sup>3</sup>

<sup>1</sup>Department of Internal Medicine, Hospital Lahad Datu, Sabah, <sup>2</sup>Department of Internal Medicine, Hospital Queen Elizabeth, Sabah,

<sup>3</sup>Department of Internal Medicine, Hospital Sultanah Nora Ismail, Johor

## SUMMARY

**Malaria is a parasitic disease that is caused by the *Plasmodium* parasite. Worldwide, it remains a significant public health problem especially in the Africa region where it contributes to more than 90% of cases and malaria death. However, zoonotic (simian) *Plasmodium knowlesi* parasite is a widely prevalent cause of malaria in the South East Asian countries. It is known to cause severe human disease due to its 24-hour erythrocytic cycles. Thus far, cases of severe falciparum malaria have been reported in asplenic patients. Here, we report a case of severe *P.knowlesi* malaria in a 51-year-old man who is a post-splenectomy patient.**

## KEY WORDS:

Severe Malaria, *Plasmodium knowlesi*, Post-Splenectomy

## INTRODUCTION

Malaria is a mosquito borne parasitic disease which can be potentially fatal. Worldwide, there are more than 120 species of plasmodium, only five are known to cause disease in human,<sup>1</sup> which are *Plasmodium falciparum*, *Plasmodium vivax*, *Plasmodium ovale*, *Plasmodium malariae* and *Plasmodium knowlesi*. *P.knowlesi* is now known to be the 5<sup>th</sup> plasmodium that causes human malaria since its landmark discovery in Malaysian Borneo back in 2004. On the other hand, splenectomy predisposes a patient to acquiring infection including parasitic infections. Here, we would like to report a case of severe *P.knowlesi* malaria in a post-splenectomy patient.

## CASE PRESENTATION

A 51-year-old man with a history of splenectomy for traumatic splenic injury presented to Hospital Lahad Datu (HLD), Sabah with acute febrile illness. He presented with 3 days history of fever, associated with chills and rigors. Fever occurred every day in the evening. There was also two episodes of vomiting, arthralgia, myalgia and reduced oral intake for past 3 days. Otherwise, he denied cough, diarrhoea or abdominal pain. He also did not notice any bleeding tendencies. He had recently been jungle trekking in Lahad Datu forest a week prior to his illness.

On arrival to emergency department of HLD, he appeared lethargic, jaundice and tachypnoeic. He had good pulse volume.

His blood pressure was 101/57mmHg, pulse rate was 108 beats per minute, respiratory rate was 24 breaths per minutes, saturation on room air was 93% and his temperature was 38°C. Respiratory examination was unremarkable. Abdominal examination showed presence of left subcostal scar with no hepatomegaly.

His full blood counts showed haemoglobin of 14.7g/dl, total white blood cell of  $11.2 \times 10^9/L$  and platelet count of  $177 \times 10^9/L$  (Table I). Renal profile showed urea of 7.9mmol/L, creatinine of 104µmol/L. His total bilirubin was 39µmol/L, bicarbonate was 21mmol/L. His blood smear for malaria parasite was positive for *P.knowlesi* with parasite count of 30257/µL (Figure 1). His chest radiograph was unremarkable.

He was admitted and treated for severe malaria in view of hyperparasitemia, jaundice and respiratory distress. He was initiated on intravenous artesunate 2.4mg/kg and oral doxycycline 100mg twice daily. He was also given empirical antibiotic to treat for superimposed infection. He responded well to treatment after 5 days of artesunate and doxycycline. His blood culture showed no growth. Blood for malaria polymerase chain reaction detected *P.knowlesi* DNA, confirming the diagnosis of *P.knowlesi* malaria. He eventually recovered and discharged well after completion of riamet.

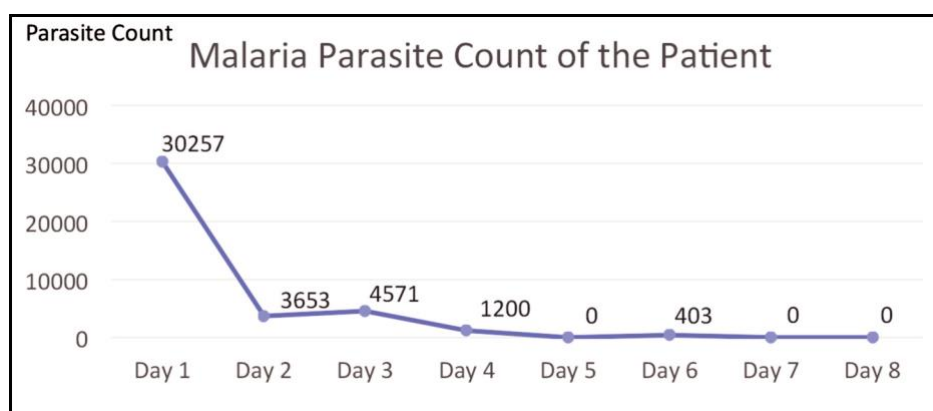
## DISCUSSION

Malaria is a parasitic disease caused by *Plasmodium* species. According to World Malaria Report 2017, there were 219 million cases of malaria reported globally in 2017. The estimated number of malaria death was around 43,500 in 2017.<sup>2</sup> It is obvious that malaria still contributes to cause significant amount of disease burden globally. Falciparum malaria is predominantly a disease of sub-Saharan Africa, whereas *P.knowlesi* malaria mainly occurred in South East Asia.<sup>1</sup> At present, there are increasing number of *P.knowlesi* malaria in Malaysia.<sup>2</sup>

*P.knowlesi* was first discovered in 1931 in an imported long-tailed macaque (*Macaca fascicularis*). Early researches showed that *P.knowlesi* causes asymptomatic and low level of parasitemia in the long-tailed macaque. Human *P.knowlesi* infections were thought to be rare with only one human *P.knowlesi* infection was reported back in 1965 in an American surveyor.<sup>5</sup> Cases of fatal *P.knowlesi* infection have also been reported before.<sup>5</sup> However, reports of post-splenectomy severe *P.knowlesi* infection remained scarce.

**Table I: Blood investigation of the patient**

Parameters	Unit	Normal Range	Results					
			Day1	Day2	Day3	Day4	Day5	Day6
Haemoglobin	g/dL	13–18	14.7	14.3	12.6	12.7	13	12.5
Total White Blood Cell	10 <sup>9</sup> /L	4–10	11.2	11.7	13.3	10.4	11.6	10.5
Platelet	10 <sup>9</sup> /L	150–400	177	161	200	238	346	432
Sodium	mmol/L	135–145	132	135	131		137	134
Potassium	mmol/L	3.5–5	4.1	4.3	4.5		4.8	4.9
Urea	mmol/L	2.8–7.8	7.9	8.4	9.3		10	10
Creatinine	µmol/L	90–110	104	100	78		67	93
ALT	U/L	<40	34	29	20		19	
AST	U/L	<38	17	16	-		25	
ALP	U/L	40-129	164	160	127		132	
Albumin	g/L	34-48	37	33	29		34	
Total bilirubin	µmol/L	<17	39	40	31		15	
Bicarbonate	mmol/L	22-28	21	21.1				
Blood Culture			No Growth					
Dengue NS-1			Negative					
Blood for malaria PCR				Plasmodium knowlesi DNA detected				



**Fig. 1:** Graph showing Malaria Parasite Count of The Patient.

Our patient was a middle-aged man who had splenectomy for traumatic splenic injury. He had severe *P.knowlesi* malaria based on hyperparasitemia, respiratory distress and jaundice. Fortunately, the patient responded well to artemisinin-based combination therapy. Predictably, he had delayed parasite clearance. The likely reason behind this is due to absence of splenic function, where spleen function to clear the dead or dying parasite.<sup>3</sup> Besides this, we also noticed our patient did not have thrombocytopenia throughout the illness. This is a notable feature as thrombocytopenia is present in almost all reported cases of *P.knowlesi* malaria. We believe that the absence of thrombocytopenia is likely to be related to his previous splenectomy.

Spleen function as major site of regulation of red blood cells and immune system. In a malaria infected person, the spleen function to clear parasitised red blood cell, to generate new red blood cell and to generate appropriate T and B cell responses.<sup>4</sup> Besides, the spleen also functions to remove parasite from infected RBC and return the RBC to circulation. Hence, it is understandable that among splenectomised patients, severe and fatal cases are more frequent

and higher parasite counts are observed. Delayed parasite clearance is also observed.<sup>3</sup>

In term of diagnosis, light microscopy of blood film remains the gold standard for diagnosis of malaria.<sup>1</sup> However, it's important to note that it's difficult to differentiate *P.malariae* and *P.knowlesi* from light microscopy due to its morphological resemblance. Hence, detection *P.knowlesi* DNA from polymerase chain reaction (PCR) is more diagnostic of *P.knowlesi* malaria. The first PCR technique employed to detect *P.knowlesi* was nested PCR with primers Pmk8 and Pmkr9, based on the small-subunit (SSU) rRNA genes. Recently, new *P.knowlesi*-specific primers (primers PkF1140, PkR1550, Kn1f and Kn3r) have also been identified.<sup>5</sup> Other useful diagnostic modalities include rapid diagnostic test, loop-mediated isothermal amplification (LAMP) and quantitative PCR (qPCR).

Treatment of *P.knowlesi* malaria does not differ much from other species of malaria. Treatment with intravenous artesunate therapy is proven to be effective in treating severe *P.knowlesi* malaria. Early diagnosis and correct treatment are associated with good

outcome<sup>1</sup>. The typical treatment regimen of severe malaria includes at least 3 doses of intravenous artesunate followed by oral riamet for 6 doses. Associated complication such as Acute Respiratory Distress Syndrome (ARDS), Acute Kidney Injury (AKI) should be treated and supported accordingly. In splenectomised patients, it is important to have high degree of suspicion of severe malaria as this group of patients have higher risk of severe malaria if they are infected, higher parasite count, more likely to have delayed parasite clearance. However, in this group of patients, the treatment does not require additional anti-malarial treatment.<sup>3</sup>

## CONCLUSION

To date, the number of reported cases of severe *P.knowlesi* in post-splenectomy are few. It is important for physicians to consider *P.knowlesi* malaria as a differential diagnosis in managing a post-splenectomy patient who present with fever, and of course taking into consideration the clinical history and exposure. It is important to recognise this group of patients as they tend to have more severe infection and higher malarial parasite count.

## ACKNOWLEDGEMENT

The authors would like to thank the Director General of Health for permission to publish this paper.

## FINANCIAL DISCLOSURE

The authors of this manuscript confirm that they have no affiliations with or involvement in any organisation or entity with any financial interest in the subject matter or materials discussed in this manuscript.

## CONFLICTS OF INTEREST

The authors have no conflicts of interest to declare.

## INFORMED CONSENT

Written informed consent was obtained from the patient for publication of this manuscript.

## REFERENCES

1. Ashley EA, Pyae Phyo A, Woodrow CJ. Malaria. Lancet 2018; 391(10130): 1608-1621.
2. World malaria report 2017. Geneva: World Health Organization; 2017.
3. Chotivanich K, Udomsangpetch R, McGready R, Proux S, Newton P, Pukrittayakamee S, et al. Central role of the spleen in malaria parasite clearance. J Infect Dis 2002; 185(10): 1538-41.
4. Engwerda CR, Beattie L, Amante FH. The importance of the spleen in malaria. Trends Parasitol 2005; 21(2): 75-80.
5. Singh B, Daneshvar C. Human infections and detection of Plasmodium knowlesi. Clin Microbiol Rev 2013; 26(2): 165-84.