

# It is not asthma! An arcane case of ‘Scimitar’ syndrome: A case report

Ganapathi Palaniappan, MRCP<sup>1</sup>, Nurul Yaqeen Mohd Esa, MRCP<sup>2</sup>, Zamzurina Abu Bakar, M.INT MED<sup>3</sup>

<sup>1</sup>Department of Medicine, Hospital Kuala Lumpur, Kuala Lumpur, Malaysia, <sup>2</sup>Centre for Respiratory Medicine & Sleep Health, UiTM Medical Centre, Sungai Buloh, Selangor, Malaysia, <sup>3</sup>Institute of Respiratory Medicine, Kuala Lumpur, Kementerian Kesihatan Malaysia, Kuala Lumpur, Malaysia

### SUMMARY

**‘Scimitar’ syndrome in adulthood is usually asymptomatic. Significant structural abnormalities symptoms usually manifest early during infancy or young childhood with features of congestive heart failure from significant shunting of the anomalous pulmonary venous drainage. Diagnosis of ‘Scimitar’ Syndrome in adults is rare and usually an incidental finding on chest radiograph. Here, we report a case of an adult who presented with symptoms in her 40’s. This syndrome has never been reported nor discussed in Malaysia. This is the first case report of ‘Scimitar’ Syndrome in Malaysian literature. The diagnostic dilemma, medical management, and multi-disciplinary management by cardiology, physiotherapy and pulmonary rehabilitation teams are discussed.**

### INTRODUCTION

‘Scimitar’ Syndrome consists of partial anomalous pulmonary venous drainage of the right lung to the inferior vena cava, right lung hypoplasia, cardiac dextroposition, and anomalous systemic arterial supply to the right lung. It has varied presentation; ranging from asymptomatic to those with heart failure and severe pulmonary hypertension. The term ‘Scimitar sign’ is derived from the chest radiographic appearance of the anomalous vein which appears as a tubular opacity parallel to right cardiac border, resembling a curved Turkish sword, ‘Scimitar’.<sup>1</sup>

The incidence is approximately 1 to 3 per 100,000 live births.<sup>2</sup> True incidence may be higher because many are asymptomatic. Most adults are diagnosed when worked up for dyspnoea, fatigue, recurrent respiratory infection or from incidental findings in routine chest radiograph.<sup>2,4</sup> Clinical symptomatology is governed by age at presentation. The adult form typically has a benign course. Infantile form presents soon after birth, complicated with severe pulmonary hypertension, haemoptysis and cardiac failure making management difficult and mortality high.<sup>3,5</sup> Young children present with dyspnoea, respiratory distress, cyanosis, failure to thrive or cardiac failure.<sup>3,5</sup> Diagnosis can be difficult, requiring extensive diagnostic evaluation with chest radiograph, computed tomography (CT) of thorax and pulmonary artery, echocardiogram, cardiac catheterisation and aortogram. This syndrome may be associated with other intracardiac anomalies such as Atrial Septal Defect, Patent Ductus Arteriosus, Ventricular Septal Defect or Tetralogy of

Fallot. There are also cases of horseshoe lung reported associated with ‘Scimitar’ syndrome. Approximately 80% infants with horseshoe lung also have ‘Scimitar’ syndrome. Other extracardiac manifestations include vertebral anomalies, scoliosis, right diaphragmatic hernia, and myelomeningocele.<sup>5</sup> Pulmonary hypertension is recognised as the cause of severe symptoms and poor outcome. This may lead to irreversible damage to the pulmonary vascular bed and eventually right heart failure. Currently there are no guidelines available for surgical or medical treatment of ‘Scimitar’ syndrome. Surgical intervention is very important at early stage for patients with pulmonary hypertension prior to developing irreversible pulmonary vascular disease. Common surgical options include occlusion of systemic arterial collaterals, right pneumonectomy or complete repair. Medical management includes regular follow up to assess functional capacity, disease progressions and complications such as cardiac failure and pulmonary hypertension along with treatment of these complications and infection prevention with vaccinations.

### CASE REPORT

A 43-year-old Malay woman presented with exertional dyspnoea for the past four years which gradually worsened (MRC grade 3 dyspnoea). She had no constitutional symptoms. Past medical history revealed recurrent respiratory infections for the past four years and recently developed occasional haemoptysis. She was presumed and treated for bronchial asthma by a general practitioner, who prescribed inhaled corticosteroid (ICS) and long acting beta-agonist (LABA) and Salbutamol, but there was no improvement. She has no significant family history and no history of atopy. She is a non-smoker, housewife, married and blessed with two healthy children. Physical examination showed finger clubbing, absence of air entry at right lower zone and right parasternal heaving. Chest radiograph showed cardiac dextroposition with an elevated right hemidiaphragm (suggestive of hypoplastic right lung) and ‘Scimitar’ sign (figure 1). CT thorax showed features of ‘Scimitar’ syndrome with anomalous drainage of right lung directly into Inferior Vena Cava (figure 2), hypoplastic right lung, and right mediastinal shift associated with minimal bronchiectasis at anterobasal segment of left lower lobe, and right T2 and L1 hemivertebra. Her tuberculosis (TB) work up was negative. Her recent echocardiogram showed estimated ejection fraction of 50%. However, further assessment was

*This article was accepted: 21 January 2020*

*Corresponding Author: Dr. Ganapathi Palaniappan*

*Email: dr.gana.palani@gmail.com*

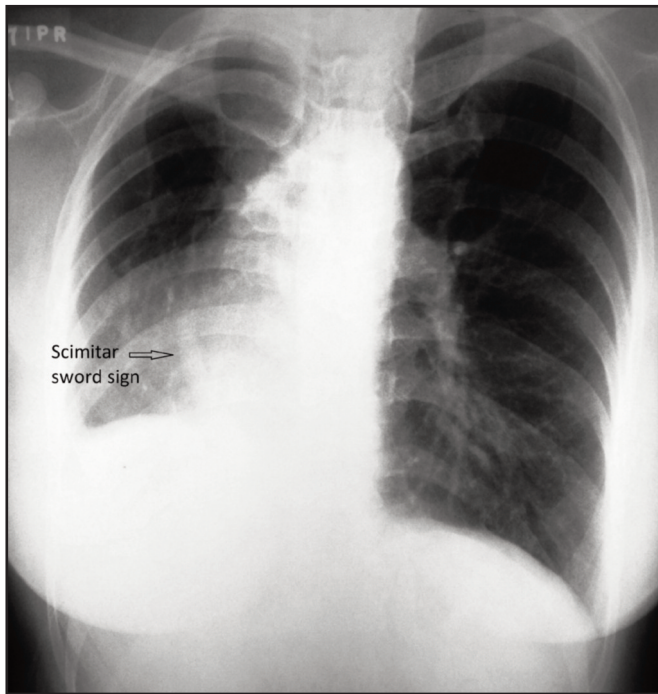


Fig. 1: CXR scimitar sword sign.

unable to be performed due to poor echo window resulting from the obscuration by the sternum. Her lung function test showed restrictive features with no significant reversibility post bronchodilator; FEV1 of 1.08L (44%); FVC of 1.17L (41%); and FEV1/ FVC of 92% suggestive of restrictive ventilatory defect. A 6-minute walk test in late 2016 was 284metres (43% of predicted) and currently, it had deteriorated further to 222metres (35% predicted) with no desaturation observed. She has been referred to cardiology team for right heart catheterization study, however not done due to financial issues.

## DISCUSSION

Scimitar syndrome is a rare finding among Malaysian population. The delay in diagnosis can be resolved by an early chest radiograph. An elevated right hemi-diaphragm, cardiac dextroposition, or presence of 'Scimitar' sign should alert clinician to suspect 'Scimitar' syndrome. Once a CT confirms the diagnosis, patients should be referred to a respiratory physician and co-managed with cardiologist. This case report is contrary to current understanding that presentation in adulthood is typically benign. Patients should have followed ups to assess for new or worsening respiratory or cardiac symptoms, complications such as pulmonary hypertension and cardiac failure. Presence of significant haemoptysis and right parasternal heaving puts this patient in high suspicion of pulmonary hypertension.

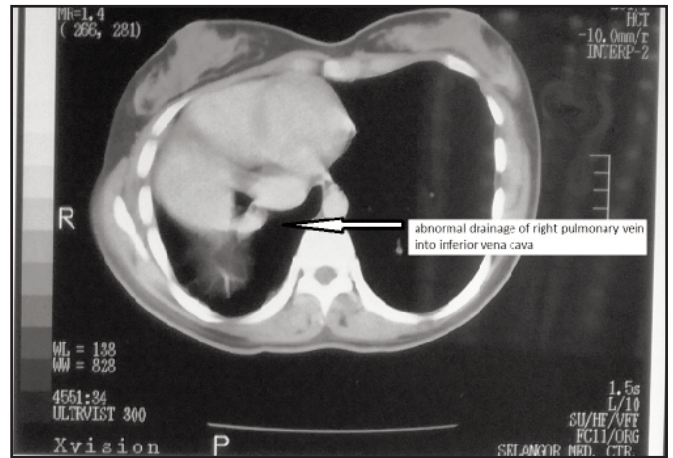


Fig. 2: Abnormal RPV drainage into IVC.

Every 'Scimitar' syndrome patient should undergo a 6-minute walk test at each appointment, annual echocardiogram and lung function test. If pulmonary hypertension is suspected, further assessment with right heart catheterization study is needed. Surgical intervention should be offered even in adults, if indicated. Medical management includes management of cardiac failure with inotropes and diuretics; and pulmonary hypertension with nitric oxide. Patients with 'Scimitar' syndrome should also be offered influenza and pneumococcal vaccination in view of the risk of recurrent infections. Management should involve multi-disciplinary approach involving respiratory, cardiology, physiotherapy, and pulmonary rehabilitation teams.

## CONCLUSION

The diagnosis of 'Scimitar' syndrome is commonly delayed or even missed in adulthood. Clinicians should be alert with the atypical chest radiograph appearance. Contrary to common understanding that adult 'Scimitar' syndrome typically has a benign course, clinicians should anticipate complications by regularly following up. Multidisciplinary approach should be considered with progression of the disease. Further research and data are needed in order to establish further prognosis and treatment outcome of these patients.

## REFERENCES

1. Neill CA, Ferencz C, Sabiston DC, Sheldon H. The familial occurrence of hypoplastic right lung with systemic arterial supply and venous drainage "Scimitar" syndrome." *Bull Johns Hopkins Hosp* 1960; 107: 1-21.
2. Dupuis C, Charaf LA, Breviere GM, Abou P, Remy-Jardin M, Helmius G. The "adult" form of the 'Scimitar' syndrome. *Am J Cardiol* 1992; 70(4): 502-7.
3. Kiely B, Filler J, Stone S, Doyle EF. Syndrome of anomalous venous drainage of the right lung to the inferior vena cava: a review of 67 reported cases and three new cases in children. *Am J Cardiol* 1967; 20: 102-16.
4. Dupuis C, Remy J, Remy-Jardin M, Coulomb M, Breviere GM, Ben Laden S. The "horseshoe" lung: six new cases. *Pediatr Pulmonol* 1994; 17(2): 124-30.
5. Kamler M, Kerkhoff G, Budde T, Jakob H. Scimitar syndrome in an adult: diagnosis and surgical treatment. *Interact Cardiovasc Thorac Surg* 2003 Sep;2(3):350-1.