

# Coronary artery bypass graft surgery in a young female with systemic lupus erythematosus and its operative challenges: A case report

Gurpreet Singh, MBBS, MRCS, Simon Jerome Vendargon, MS (Surgery), Syed Rasul Syed Hamid, FRCS

Department of Cardiothoracic Surgery, Hospital Sultanah Aminah, Johor Bahru, Johor, Malaysia

## SUMMARY

We understand that autoimmune disorders such as Systemic Lupus Erythematosus increases the likelihood of developing coronary heart disease. However, its implications on patients undergoing cardiac surgery is not well understood. Here we present a female patient with SLE who developed coronary artery disease at a young age and underwent coronary artery bypass graft surgery. As SLE is associated with vasculitis, we wanted to understand regarding the choice of conduit as well as its long term patency. Also whether percutaneous angioplasty has a role to play in patients with SLE.

## INTRODUCTION

Systemic Lupus Erythematosus (SLE) is an autoimmune disorder that tends to affect multiple organs. Patients with SLE have a high risk of cardiovascular events due to atherosclerosis.<sup>1</sup> Most of patients with SLE, particularly at a young age do not have the classical risk factors that contribute towards the development of cardiovascular disorders.<sup>1</sup> Evidence in recent studies have shown that the development of atherosclerosis in SLE patients are strongly associated with inflammation and active immunological response which is a total contrast to the usual belief that atherosclerosis is formed from the accumulation of lipids in the walls of arteries.<sup>1</sup> Premature atherosclerosis formation leading to coronary artery disease is of major concern as it is associated with high morbidity and mortality. Although the usual conditions in SLE such as vasculitis and nephritis are commonly focused on, its association with coronary artery disease should not be ignored. The overall prevalence of coronary heart disease in SLE ranged from 6-10%.<sup>2</sup> A study done by Manzi et al., showed that women with SLE in the age group of 35-44 were 50 times more likely of developing coronary artery diseases compared to women with similar age group in the Framingham Study.<sup>2</sup> As of now, not many reports are available in regards to Coronary artery bypass graft surgery in SLE patients. In this case report, we write our experience on performing a coronary artery bypass graft (CABG) on a SLE patient.

## CASE REPORT

A 31-year-old Malay woman, was electively admitted to the Cardiothoracic Surgery ward, Hospital Sultanah Aminah, Johor Bahru for coronary artery bypass graft surgery. She was

diagnosed with Systemic Lupus Erythematosus in 2007 complicated with lupus nephritis when she presented with a week history of malar rash and currently under rheumatology follow up. Her past medical history includes hypertension and dyslipidaemia for the past 10 years. In 2016, she developed an acute onset of chest pain which was crushing in nature radiating to the left arm. Electrocardiogram done in the Emergency Department showed inferior myocardial infarction which was successfully thrombolysed with streptokinase. Coronary angiogram done in 2017 shows distal Left main stem occlusion of 80% with a discrete proximal Left anterior descending lesion of 95%. Other areas of the coronary vessels were fairly normal (Figure 1 and 2). She successfully underwent coronary artery bypass graft surgery on March 2019. The Left Internal Mammary artery was anastomosed to the left anterior descending artery and saphenous vein graft anastomosed to first obtuse marginal. Pre operatively, her renal functions were normal. Her post-operative recovery was uneventful and her systemic steroids were continued. Renal function repeated during her post-operative period showed no derangement. Sternotomy and saphenous vein harvest site wound appears clean. She was discharged well on the seventh post-operative day.

## DISCUSSION

Planning for a coronary artery bypass graft surgery in this patient poses a lot of challenges. Due to the fact that SLE is a progressive disease, we were concerned about the patency of the grafts and the possibility of a redo surgery later on. The continuous inflammatory process as discussed above could possibly cause atherosclerosis in the right coronary artery and possibly requiring redo CABG later on. The type of conduit to use was also important to consider. The most important question is whether CABG surgery performed in a patient with compromised life expectancy due to multisystem involvement and high possibility of postoperative wound infection due to steroid use. Rinaldi et al., studied two patients with underlying SLE that underwent CABG, both treated with a left internal mammary graft. Biopsy from both the grafts showed non-involvement by SLE although SLE is associated with arteritis.<sup>3</sup> Despite this, there is still no guarantee that the grafts would not develop intimal hyperplasia in the future.<sup>3</sup> There is one case reported whereby a SLE patient who underwent a bypass surgery was then followed by Percutaneous Transluminal Coronary

*This article was accepted: 19 July 2019*

*Corresponding Author: Dr. Gurpreet Singh*

*Email: gurpz\_91@yahoo.com*

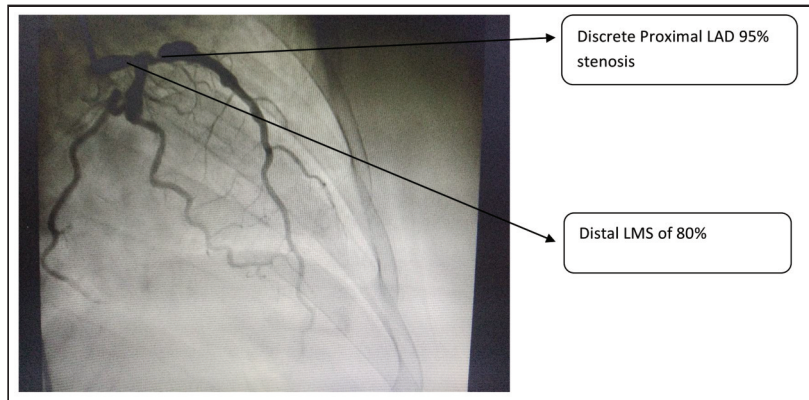


Fig. 1: Distal Left main stem lesion with discrete proximal Left Anterior Descending stenosis.

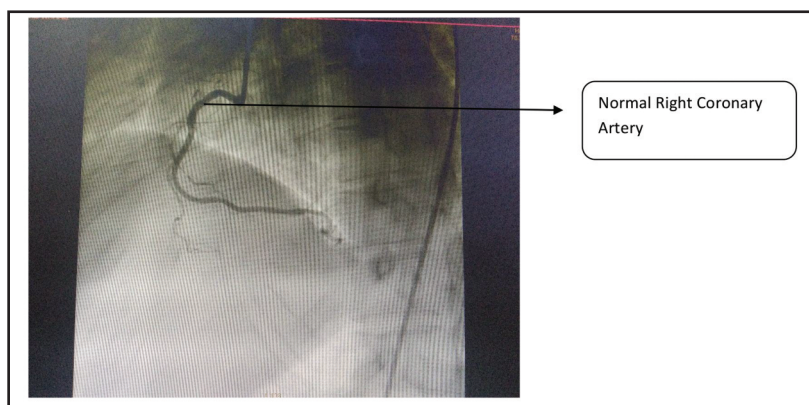


Fig. 2: Normal Right coronary artery.

Angioplasty (PTCA).<sup>3</sup> The successful PTCA avoided reoperation for this patient but nevertheless, the overall outcome of coronary arteries treated with PTCA is still not known. Ura et al., found that the early graft patency rates were 83.7% but however due to coexisting medical conditions such as diabetes mellitus, hyperlipidaemia and lupus nephropathy in SLE patients, saphenous vein graft appear to deteriorate early.<sup>4</sup> The reported postoperative complications in these group of patients were 44% which included early graft thrombosis, bleeding and ventricular tachycardia.<sup>4</sup> Wilson et al., reported two cases of patients with SLE and acute myocardial infarction who were treated with PTCA.<sup>5</sup> Both of them sustained re-occlusion of the dilated vessel and one died. Therefore, whether PTCA can be used as primary therapy or secondary to failure of coronary artery bypass grafting remains to be seen as experience needs to be accumulated.

**CONCLUSION**

Due to enhanced medical management offered to patients with SLE to increase life expectancy, the large doses of corticosteroids raises the possibility of coronary involvement. The inflammatory manifestation of the disease itself further increases the possibility of developing coronary artery disease. Although not much information is available regarding the choice of conduit and its implications, the

usage of internal mammary artery and saphenous vein graft can still benefit patients with SLE as graft patency rates were reported as 83.7%.<sup>4</sup> However we feel that more long term follow up is required to comment on graft patency. Angioplasty was not done for our patient as the lesion was at the left main stem. Whether or not PTCA would benefit patients who are suitable for angioplasty in the long run still needs more research. On the whole we believe that CABG in a SLE patient can be performed with acceptable morbidity and mortality in spite of coexisting complex diseases.<sup>4</sup>

**REFERENCES**

1. Zeller CB, Appenzeller S. Cardiovascular disease in systemic lupus erythematosus: the role of traditional and lupus related risk factors. *Curr Cardiol Rev* 2018; 4(2): 116-22.
2. Manzi S, Meilahn EN, Rairie JE, Conte CG, Medsget TA Jr, Jansen-McWilliams L, et al. Age-specific incidence rates of myocardial infarction and angina in women with systemic lupus erythematosus: comparison with the Framingham Study. *Am J Epidemiol* 1997; 145(5): 408-15.
3. Rinaldi RG, Carballido J, Betancourt B, Sartori M, Almodovar EA. Coronary artery bypass grafting in patients with systemic lupus erythematosus. Report of 2 cases. *Tex Heart Inst J* 1995; 22(2): 185-8.
4. Ura M, Sakata R, Nakayama Y, Ohtsuka Y, Saito T. Coronary artery bypass grafting in patients with systemic lupus erythematosus. *Eur J Cardiothorac Surg* 1999; 15(5): 697-701.
5. Wilson VE, Eck SL, Bates ER. Evaluation and treatment of acute myocardial infarction complicating systemic lupus erythematosus. *Chest* 1992; 101: 420-4.