

# A case of cough induced rib fracture with subcutaneous emphysema and pneumothorax

Wan Nor Aida Wan Mohd Shukri, MD, Ng Von How, MD, Ahmad Khaldun Ismail, MEmMed

Department of Emergency Medicine, Faculty of Medicine, Hospital Canselor Tuanku Muhriz, Universiti Kebangsaan Malaysia Medical Centre, Jalan Yaacob Latif, Bandar Tun Razak, Cheras, Kuala Lumpur, Malaysia

## SUMMARY

**Coughing is an important reflex mechanism which enhances the clearance of secretions and particulates from the airways, however repetitive muscle strain due to prolonged coughing may cause the uncommon complication of stress fracture of the ribs. The following is an unusual case of cough induced multiple rib fractures associated with subcutaneous emphysema and pneumothorax which was missed in the emergency setting. Delayed diagnosis and treatment would have been avoided if this uncommon condition was considered as a possibility.**

## CASE REPORT

A 53-year-old man with underlying hypertension, dyslipidaemia and chronic obstructive airway disease (COPD) presented to the Emergency Department (ED) complaining of sudden onset of swelling over the right side of his face, neck and chest after a coughing episode, associated with mild right sided pleuritic chest pain and slight hoarseness of voice. There was a history of chronic intermittent cough with whitish sputum for the past six months. He denied fever or difficulty in breathing. There was no history of fall or trauma prior to onset of his symptoms. There was no family history of malignancy or connective tissue disease and he worked as a supervisor in a warehouse. He had no prior history of hospitalisation and was pre-morbidly well.

Upon examination, the patient was mildly tachypnoeic with an initial respiratory rate of 20 breaths per minute and pulse saturation of 94% on air. Crepitus was palpable over the skin of the right side of his face, neck and chest. Auscultation of his lungs revealed generalised rhonchi with prolonged expiratory phase. Nebulised salbutamol and ipratropium bromide (Combivent) was administered and he was put on supplemental oxygen of 3L/min via nasal cannula.

Portable anteroposterior plain chest radiograph revealed extensive subcutaneous emphysema over the right chest extending up to the neck with right lower lung consolidation (Figure 1). Rib fractures and pneumothorax were not identified on the portable anteroposterior plain chest radiograph.

A diagnosis of spontaneous subcutaneous emphysema secondary to acute exacerbation of COPD with concurrent

pneumonia was made. On admission he was started on four hourly Combivent nebulisation, intravenous Augmentin and intravenous hydrocortisone. An urgent high-resolution computed tomography (HRCT) of the Thorax on same day of admission revealed right 6th, 7th and 9th rib fractures, right-sided pneumothorax, pneumomediastinum and extensive subcutaneous emphysema (Figure 2a). Right basal lung collapse consolidation was also noted with a large bulla measuring 2.2x2.6cm over superior segment of the right lower lobe (Figure 2b).

A chest tube was inserted and repeated plain chest radiograph on day six admission showed an expanded right lung and resolving subcutaneous emphysema. The subcutaneous emphysema had subsided, and the patient was comfortable under room air. The patient was then allowed home on day seven of admission after completion of antibiotics. He was planned to be reviewed again by Respiratory and Cardiothoracic teams two weeks after discharge.

## DISCUSSION

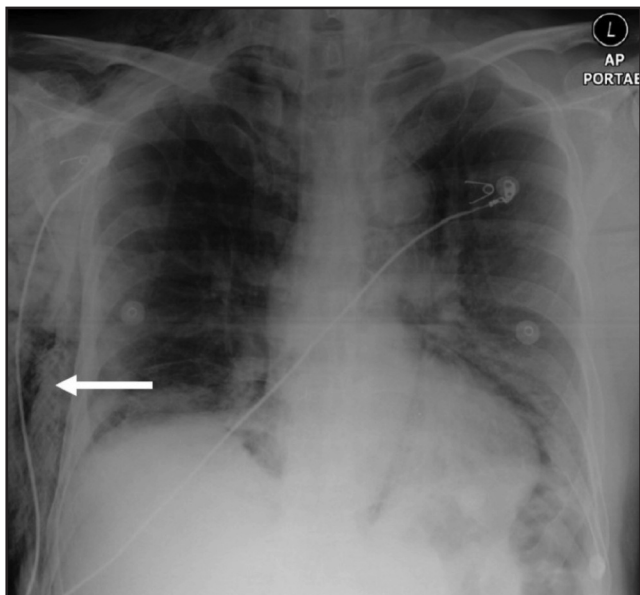
Non-traumatic rib fractures may occur due to repetitive mechanical stress to the ribs attributed to muscle strain. Repeated contraction of the serratus anterior and external oblique muscles attached to the ribs during coughing increases the risk of rib fracture as it reduces the ability of the muscles to absorb and dissipate opposing forces.<sup>1</sup> The main presentation of cough induced rib fracture would be acute chest pain after coughing.

In this case, diagnosis of cough induced rib fracture was delayed because rib fractures were not immediately identified on the initial plain portable chest radiograph. Retrospective evaluation of the initial plain portable chest radiograph did reveal multiple rib fractures but unfortunately at time of presentation the ribs were not assessed and hence the rib fractures were missed. This was most likely because there was no history of trauma and that cough induced rib fracture was not considered as a possible diagnosis. Although plain chest radiographs are useful in detection of rib fractures but according to De Maesseneer et al., plain chest radiographs are negative for as many as 60% of patients with rib fractures regardless of aetiology. The presence of subcutaneous emphysema may have obscured the lung fields and therefore added to the difficulty of appreciating rib fractures and

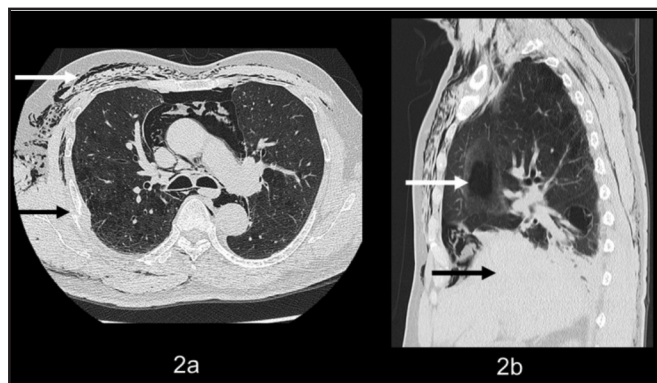*This article was accepted: 7 August 2019*

*Corresponding Author: Dr. Wan Nor Aida Wan Mohd Shukri*

*Email: wannoraida@gmail.com*



**Fig. 1:** Portable anteroposterior chest radiograph (x-ray) showing extensive subcutaneous emphysema over right chest extending up to neck (white arrow).



**Fig. 2:** a) High-resolution computed tomography (HRCT) Thorax showing subcutaneous emphysema (white arrow) and rib fracture (black arrow); b) HRCT Thorax showing bullae over right lung (white arrow) and right lower lung consolidation (black arrow).

pneumothorax. This should raise a high index of suspicion for pneumothorax regardless of inconclusive initial radiological findings. Other imaging modalities which may aid in diagnosis are skeletal scintigraphy and computed tomography (CT) of the thorax, which also help to exclude pathological causes of rib fracture.<sup>2</sup> In the emergency setting, an urgent CT Thorax may be considered depending on the patient’s clinical condition and stability, with the concern to exclude other serious, life-threatening conditions.

Other predisposing factors of this patient were his underlying COPD and history of chronic cough. Stress fracture of ribs induced by cough are commonly reported in association with pulmonary diseases such as pulmonary tuberculosis, pneumonia, and chronic obstructive pulmonary disease.<sup>3</sup> Patients with chronic cough of more than three weeks duration were also found to be at higher risk of cough induced rib fractures.<sup>4</sup> The patient’s underlying COPD also increased the risk of underlying bullae formation, which likely ruptured upon rib fracture subsequently causing pneumothorax and subcutaneous emphysema. Therefore, the diagnosis of spontaneous subcutaneous emphysema secondary to acute exacerbation of COPD is inaccurate, as COPD itself does not directly cause pneumothorax or subcutaneous emphysema.

Most uncomplicated cough induced rib fractures are managed conservatively, with adequate analgesia being the mainstay of treatment. However, cases with complications of hemothorax,<sup>5</sup> pneumothorax and lung contusion necessitate advanced therapy and should be managed accordingly with supplemental oxygen and chest tube insertion.

**CONCLUSION**

Cough induced rib fractures is an uncommon complication of coughing and should be considered among any patient with acute onset of chest pain following coughing. Although rare, complications of pneumothorax and subcutaneous emphysema may also occur, such as in this case. Delayed diagnosis and management could have been avoided if cough induced rib fracture was considered a possible diagnosis and urgent CT Thorax was done in the Emergency Department setting. Prompt detection and diagnosis of cough induced rib fractures is essential so that the appropriate treatment can be administered.

**CONFLICT OF INTEREST**

None declared

**REFERENCES**

1. Connolly LP, Connolly SA. Rib stress fractures. *Clin Nucl Med* 2004; 29(10): 614-6.
2. De Maesaeneer M, De Mey J, Debaere C, Meysman M, Osteaux M. Rib fractures induced by coughing: an unusual cause of acute chest pain. *Am J Emerg Med* 2000; 18(2): 194-7.
3. Roberge RJ, Morgenstern MJ, Osborn H. Cough fracture of the ribs. *Am J Emerg Med* 1984; 2(6): 513-7.
4. Hanak V, Hartman TE, Ryu JH. Cough-induced rib fractures. *Mayo Clin Proc* 2005; 80(7): 879-82.
5. Camarillo-Reyes LA, Marquez-Córdova RI, Surani S, Varon J. Hemothorax induced by severe cough: An unusual presentation. *SAGE Open Med Case Rep* 2019; 7: 2050313X19846043.