

Tunneled catheter (PleurX) for long-term chest and abdominal drainages from 2012-2017 in a tertiary institution

Martin Weng Chin H'ng, FRCR, Kheng Song Leow, FRCR

Department of Diagnostic Imaging, Tan Tock Seng Hospital, Singapore

SUMMARY

The PleurX catheter was developed to facilitate long-term intermittent drainage of malignant pleural effusion or ascites. For palliation, it is important that the process of insertion is safe and that this catheter remains complication-free so as to improve end-of-life quality. We show that this catheter can be safely inserted and discuss methods to reduce infection, which was the most common complication. Our article hopes to enlighten clinicians, patients and their caregivers of this device as a treatment option in palliative patients. Proper case selection and caregiver training are essential in ensuring a successful outcome.

KEY WORDS:

Pleural effusion, ascites, tunneled catheter, malignant, palliative

INTRODUCTION

Malignant pleural effusion or ascites reflects end-stage disease, and may be refractory.^{1,2} The prognosis for these patients is often poor, with a shortened life expectancy of between three to 12 months.² Their management would be focused on palliation rather than cure.³ The PleurX catheter was introduced in 1997 for this reason, so that long-term intermittent drainage could be performed on an outpatient basis.⁴ This article aims to describe our initial experience with this device over a 6-year period. We discuss here the technical success, complications and durability of this catheter as well as broach on bed-saving measures and patient-caregiver education.

MATERIALS AND METHODS

We reviewed all patients who had a PleurX catheter (Denver Biomedical Inc, Denver, CO) inserted between 1st January, 2012 and 31st December, 2017, a 6-year period. All insertions were performed by Interventional Radiologists of consultant grade in the Radiology Department under ultrasound-guidance, with fluoroscopy or x-ray confirmation of final placement (Figure 1). Initially, the primary criterion for insertion was for recurrent pleural effusions or ascites aiming for early discharge. This later evolved to place equal emphasis on the ability of the patients or caregivers to manage this catheter. Exclusion criteria were infection of the overlying skin and coagulopathy. In the context of palliation, success is best defined by having a functioning catheter until it is either removed due to resolution of pleural effusion or till the time of patient's death.

RESULTS

Demographics

There was a total of 21 patients during this period (Table I). Their ages ranged from 39-97 years (mean 66.3, SD 13.8). There were 15 (71.4%) males and six (28.6%) females.

Technical success

Our technical success rate was 100%. This was defined as successful placement of the catheter and subsequent drainage output. No immediate complication such as lung injury, bowel perforation, vascular trauma or procedure-related death was encountered.

Complications

The most common complication was catheter-related infection (19%). Four of our first 14 cases had infection. Three had their catheters removed after 18, 38 and 142 days (whilst one was lost to follow-up). Beginning July 2015, after mandating that the procedure be done on the Angiography table (and not at the bedside) with full body draping and instituting antibiotic therapy, none of the subsequent seven cases experienced an infective complication. Our other complications included low pleural output (n=1) and delayed benign massive pneumoperitoneum (n=2).

Catheter lifespan

Of our first 14 patients, seven had their catheter in-situ till they passed away, three developed catheter infection necessitating removal whilst four were lost to follow-up. The final seven patients had their catheter functioning till death (n=5) or removed due to no further recurrence of their pleural effusion due to auto-pleurodesis (n=2). Our auto-pleurodesis rate was 14.3% and these patients' catheters were removed at 82 and 121 days. Excluding the four patients who were lost to follow-up, the median lifespan of the catheter was 78.8 days.

DISCUSSION

In the setting of palliation, it is important that insertion of the PleurX catheter is safe and that this catheter remains functional in order to keep the patient out of hospital and maintain his/her independence. Our technical success rate of 100% was similar to that of several studies.¹ Furthermore, 66% of our patients had a functional catheter till the time of auto-pleurodesis or death. Our auto-pleurodesis rate of 14.3% occurred at 82 and 121 days, whilst that in the literature is between 21-58% and usually within a month from insertion.^{2,4}

This article was accepted: 1 June 2019

Corresponding Author: Dr. Martin Weng Chin H'NG

Email: martinhngwc@gmail.com

Table I: Patients' disease status and outcome of catheter

Location of catheter	Primary malignancy	ECOG ^a status	Outcome of catheter
Chest	Lung	2	Lasted till death
	Colorectal	1	Lasted till death
	Lung	1	Lost to follow-up
	Lung	1	Lasted till death
	Breast	2	Infection. No microbiology work-up. Removed.
	Lung	1	Lasted till death
	Lung	2	Infection. Pleural fluid grew coagulase negative Staphylococcus. Removed.
	Lung	3	Lasted till death
	Lung	1	Lasted till death
	Lung	1	Lasted till death
	Lung	1	Lasted till death
	Lung	1	Lasted till death
	Lung	1	Auto-pleurodesis. Removed.
	Lung	1	Auto-pleurodesis. Removed.
	Abdomen	Appendix	1
Gastro-oesophageal		1	Lost to follow-up
Ovarian		4	Lost to follow-up
Prostate		2	Infection. Wound swab grew <i>Pseudomonas aeruginosa</i> and <i>Klebsiella pneumoniae</i> . Lost to follow-up.
Liver		3	Infection. Ascitic culture grew <i>Pseudomonas aeruginosa</i> . Removed.
Leukaemia		1	Lasted till death
Non-malignant Systemic sclerosis		NA ^b	Lasted till death

^a Eastern Cooperative Oncology Group

^b NA: not applicable

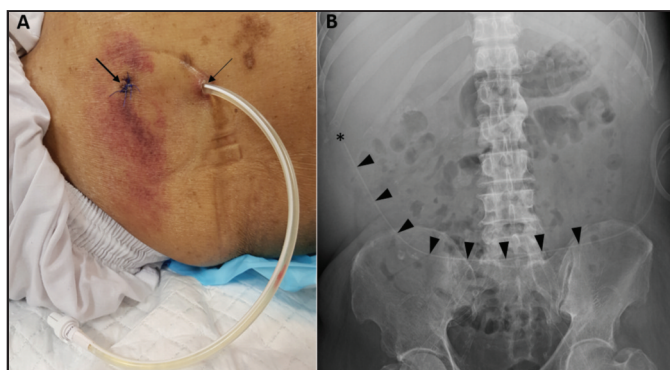


Fig. 1: Patient with a PleurX catheter at the left abdominal wall.

A, Trans-abdominal access was obtained at the lower abdomen (thin arrow). The catheter was then subcutaneously tunneled towards the first access site, such that its fibrin cuff was located midway in the tunnel, and finally inserted into the peritoneal cavity via a peel-away sheath.

B, Abdominal radiograph showing course of the catheter with tip in the right para-colic gutter (asterix). There are several fenestrations along the distal half of its length (arrowheads).

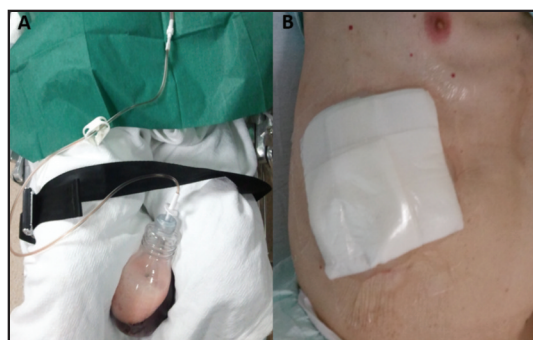


Fig. 2: Another patient with a PleurX catheter at the lower right chest.

A, PleurX bottle with drainage tube, whose nozzle is inserted into the catheter hub, under aseptic technique, to facilitate drainage. The vacuum bottle expedites drainage whilst a one-way valve at the connection prevents reflux of drained contents.

B, The catheter is coiled and placed under a water-proof dressing when not in use. This is aesthetically more pleasing and less cumbersome compared to conventional drainage, and permits the patient to carry out his/her normal daily activities.

Catheter failure is defined as intervention required to restore functioning or removal of the catheter. This is known to occur in approximately 20% of cases.^{1,2}

Catheter-related infection is the most common complication encountered, between 5-25% over the lifetime of a chest catheter.⁵ It was also our most common complication accounting for 19% of cases. Early reports reveal a paucity of articles advocating prophylactic antibiotics on a routine basis or a standard protocol for managing infection.^{2,5,6} Four of our first 14 cases had infection. Three had their catheters removed after 18, 38 and 142 days (whilst one was lost to follow-up). After instituting more stringent aseptic technique and antibiotics in July 2015, none of the subsequent seven cases experienced an infective complication.⁵ Our regimen included pre-procedure intravenous cefazolin 1g, oral cephalex 500mg twice daily for at least five days post-procedure as well as topical gentamycin cream when re-dressing the catheter after each drainage.

We had a case of low pleural output which was relieved with intra-pleural Urokinase administration, breaking down of the septae using a guidewire and eventual insertion of an additional non-tunneled drain. Hence, it is preferable not to insert these catheters into haemorrhagic or loculated effusions. Delayed benign massive pneumoperitoneum may occur if continuous suctioning is applied when ascites has become negligible causing outside air to be drawn in.⁷ Neither of our two patients had signs of peritonitis, and resolution of the pneumoperitoneum was observed when suction was reduced.

Multi-disciplinary approach and caregiver training (CGT)

Proper case selection was important. Procedurists had initially behaved as "catheter inserters" but had subsequently begun playing an active role. This included speaking to the referring team and establishing rapport with the patient and family. They were counseled on the procedure and price, provided information and website links as well as given time for reflection. The preparedness of the patients and caregivers were necessary in ensuring success of the entire procedure. Good communication with the referring team and patient was maintained post-insertion, so as to intervene early in the event of any complication.

Education regarding the care of the PleurX system to the patient and caregiver was crucial.⁸ As our patient numbers were small, we started with a group consisting of dedicated advanced practitioner nurses and nurse clinicians who performed the initial drainages and conducted CGT. These individuals were preferred over general ward staff who would be unfamiliar with the device and drainage procedure.⁵ Likewise, it was also important to limit the number of caregivers to one or two, allowing them to better hone these skills.⁵

We aimed to complete our CGT by the next day. Inpatients received theirs in the ward whilst outpatients obtained theirs in the Medical Ambulatory Centre (a 23-hour ward) before discharge or in the clinic the day after discharge. With a shortened lifespan, independence and quality time outside of the hospital is invaluable.⁸

Patient comfort and potential bed-saving measure

Presently, clinicians and patients are still more accustomed to conventional drainage as an inpatient. These patients would be inconvenienced with a hospital admission attached to a drainage bottle in contrast to the PleurX device (Figure 2). We encountered 16 patients (76.2%) who had between 1-4 non-tunneled chest or peritoneal drain insertions before being referred to us for their PleurX catheter. Issues inserting the PleurX catheter at this stage would be (1) contamination of the overlying skin and dressings being a potential source of infection and (2) technical difficulty due to lack of space previously occupied by the fluid. The delays may have been due to lack of awareness of this new technology, its higher cost and rush by the clinician to treat presenting symptoms immediately. To further free up hospital beds, we performed six insertions as outpatients.^{2,4}

CONCLUSION

The PleurX device can be inserted safely with low complication rates, it is efficacious for repeated drainages with lowered costs and improves quality at the end-of-life.⁶ It would entail more awareness on the part of clinicians as referrers as well as buy-in from patients and their caregivers to manage this catheter before PleurX can be a mainstay for the treatment of palliative patients.

REFERENCES

1. Stukan M. Drainage of malignant ascites: Patient selection and perspectives. *Cancer Manag Res* 2017; 9: 115-30.
2. Sioris T, Sihvo E, Salo J, Rasanen J, Knuutila A. Long-term indwelling pleural catheter (PleurX) for malignant pleural effusion unsuitable for talc pleurodesis. *Eur J Surg Oncol* 2009; 35(5): 546-51.
3. Tremblay A, Michaud G. Single-center experience with 250 tunneled pleural catheter insertions for malignant pleural effusion. *Chest* 2006; 129(2): 362-8.
4. Chambers DM, Abaid B, Gauhar U. Indwelling pleural catheters for non-malignant effusions: Evidence-based answers to clinical concerns. *Am J Med Sci* 2017; 354(3): 230-5.
5. Gilbert CR, Lee HJ, Akulian JA, Hayes M, Ortiz R, Hashemi D et al. A quality improvement intervention to reduce indwelling tunneled pleural catheter infection rates. *Ann Am Thorac Soc* 2015; 12(6): 847-53.
6. Bohn KA, Ray CE Jr. Repeat large-volume paracentesis versus tunneled peritoneal catheter placement for malignant ascites: A cost-minimization study. *AJR Am J Roentgenol* 2015; 205(5): 1126-34.
7. Gummalla KM, Pua U. Delayed benign massive pneumoperitoneum associated with tunneled peritoneal drainage catheter placement. *J Vasc Interv Radiol* 2015; 26(6): 925-7.
8. Brubacher S, Gobel BH. Use of the PleurX pleural catheter for the management of malignant pleural effusions. *Clin J Oncol Nurs* 2003; 7:35-8.