

An unexpected encounter with jejunal web after foreign bodies entrapment in a toddler

Yee Ian Yik, Ph.D¹, Ann Kee How, MRCP²

¹Division of Paediatric & Neonatal Surgery, Department of Surgery, Faculty of Medicine, University of Malaya, Kuala Lumpur, Malaysia, ²Department of Cardiology, Hospital Serdang, Kajang, Selangor, Malaysia

SUMMARY

We present a very rare case of jejunal web discovered after a toddler presented with foreign bodies entrapment, following incidental ingestion. This is perhaps the first case reported in the English publication. Expectant management with spontaneous passage of foreign bodies failed. Serial abdominal radiographs failed to determine the site of the foreign bodies accurately. Endoscopic removal was unsuccessful. Surgical removal was warranted with unexpected intra-operative finding of a jejunal web with foreign body entrapment. Although rare, a congenital intestinal web must be considered in a child presents with failure of expectant management following foreign body ingestion as surgical intervention is necessary.

CASE HISTORY

A 3-year-old Indian boy presented to a private hospital after button batteries (BBs) ingestion with initial symptoms of diarrhoea, abdominal pain and distension. Foreign bodies (FBs) were identified on abdominal radiographs (AXRs). He was admitted for 10 days and the use of regular laxatives were unable to expel these FBs. He was referred to our hospital in view of the need for surgical removal of FBs. History confirmed by his mother who witnessed the ingestion of the FBs but she was unsure of the quantity. His past medical history was insignificant. There was no history of pica. His mother recalled no history of intestinal obstruction (i.e. bilious vomiting or abdominal distension prior to the current problem). At presentation, clinical examination revealed a healthy looking child with no significant abdominal and systemic examination findings. Laboratory investigations were all normal. Abdominal radiograph (AXR) showed no evidence of bowel obstruction or pneumoperitoneum in the presence of three batteries. Serial AXRs showed varied positions of the batteries, always in cluster (Figures 1a-1d), reported to be within the gastrointestinal tract (GIT) and the latest imaging at our centre was reported by radiologist to be in the sigmoid colon. (Figure 1e).

Colonoscopy was performed with the intention to remove the batteries from the GIT. The endoscope was advanced up to the caecum but failed to locate any of the batteries. Image-intensifier was used and suggested the batteries were probably in the small intestine (extra-colonic, Figure 1f). As a consequence, diagnostic laparoscopy was performed the next

day. At laparoscopy, an unusually dilated proximal jejunum with collapsed distal jejunum and ileum were noted. The laparoscopy was converted to a mini-laparotomy, with complete exploration of the small intestine. A thickened fibrous membrane was palpated at the junction of the dilated jejunum (25cm from duodeno-jejunal flexure) and the collapsed distal jejunum (Figure 2a) with no mesenteric defect, indicating the possibility of a "web". An enterotomy at the dilated proximal jejunum confirmed the presence of a jejunal web (JW), with a central perforation of about 5mm and with the thickness of about 2mm (Figure 2b). The three batteries (diameter of 11mm each) were removed together with an additional spiculated plastic toy (length of 18mm, Figure 2c), and some undigested vegetables. The JW was excised circumferentially with the enterotomy repaired transversely. His postoperative course was uneventful, with feeding commencing three days after surgery. He was discharged home well seven days after surgery. In view of multiple episodes of FB ingestion (as indicated by the operative finding of more than one type of FBs), the child and family were referred to a child psychiatrist for assessment and family counselling.

He remains well four years after surgical intervention with no symptoms and signs of intestinal obstruction. All the operative wounds healed and he had no further episode of foreign body ingestion (Figure 2d).

DISCUSSION

Jejunal web is uncommon and usually presents early (neonate or infant) with intestinal obstruction, although late presentation (toddler) has also been reported.¹ Presentation of a jejunal web after FB ingestion with entrapment has never been reported. This is the first case report in the English literature.

Intestinal web is categorised as Type I intestinal atresia. The exact aetiology of intestinal atresia remains unknown. The popular theories put forth are the vascular theory, the recanalisation theory and the latest hyperproliferation theory. The anatomical location of the web may determine the onset and symptoms at presentation. The proximal lesion tends to present early with more prominent symptoms. More importantly the presence or absence of a central pit or perforation on the web and its size will determine the onset of presentation, with the absence and smaller sized pit present

This article was accepted: 4 April 2019

Corresponding Author: Professor Dr. Yee Ian Yik

Email: yiyik2011@gmail.com

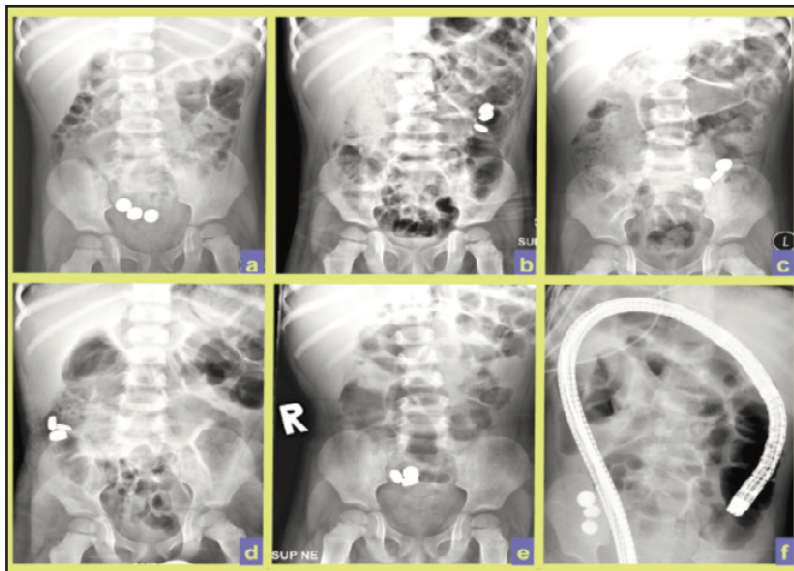


Fig. 1: a, b, c, d and e - varied positions of the three button batteries, always in cluster, f - shows the three batteries to be extra-colonic, probably in the small intestine, at colonoscopy.

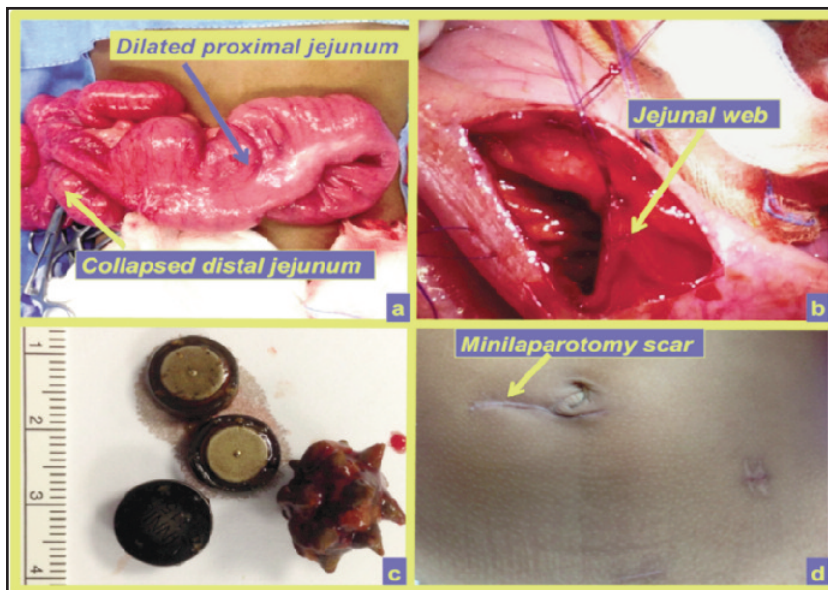


Fig. 2: a – dilated proximal jejunum with collapsed distal jejunum, b – jejunal web identified at enterotomy (a thick membranous layer), c – foreign bodies retrieved (3 button batteries & a spiculated plastic toy), d – abdominal scars after surgery at 1-month follow-up.

early with intestinal obstruction. The presence of a central pit or perforation large enough will allow the passage of chymes or food particles, with no symptoms or it may present later with subacute intestinal obstruction or failure to thrive.¹ Our patient presented after ingestion of FBs with entrapment in the jejunum, with the size of the perforation of about 5mm, trapping the FBs. The dilated segment of jejunum proximal to the web as observed in our case may be due to chronic partial obstruction by undigested food particles or the spiculate foreign body.

Foreign body ingestion in toddlers is common as they have tendency to put any objects within reach into their mouth. Expectant management with spontaneous expulsion of these ingested FBs is usually successful.² In 1985, Litovitz reported

on a series of 119 BBs ingestion; with batteries smaller than 20mm in diameter usually pass through the GIT readily.³ The GIT in these children was normal anatomically, unlike in our case—the presence of a JW with a central perforation of 5mm diameter, trapping the three batteries (diameter of 11mm). Tokar et al., proposed to remove the ingested battery as soon as possible, if it is located at a distance within reach of a flexible upper gastrointestinal endoscope.⁴ Very rarely, surgical removal of FB may be required in the presence of migration, perforation or impaction. In our case, we attempted colonoscopy to remove the batteries as they were reported to be within the sigmoid colon. After failure of endoscopic removal, a diagnostic laparoscopy was performed, leading to the discovery of a jejunal web with batteries entrapment.

The treatment for jejunal web remains surgical excision even though many approaches have been described. De Backer et al., reported on simultaneous laparotomy with endoscopy performed to localise the web before enterotomy to excise the web.⁵

This case illustrates the failure of expectant management strategy employed for FB ingestion, with an unexpected jejunal web as the cause of FBs entrapment. Ultimately, surgery was required to remove these FBs with excision of the jejunal web. Based on our experience in managing this case, we would propose to perform a gastrointestinal contrast follow-through in order to identify the cause of FBs entrapment, if they retained within the GIT beyond one week. In addition, laparoscopy can be considered as this may identify the anatomical anomaly, with a targeted approach like a mini-laparotomy rather than a formal laparotomy to deliver the segment of the intestine involved extra-peritoneally, with enterotomy and excision of jejunal web performed successfully. Psychiatric referral was considered to prevent future episodes of foreign body ingestion.

ACKNOWLEDGMENTS

The authors would like to acknowledge and thank all the staff at University Malaya Medical Centre, who had assisted and provided care for this patient.

COMPETING INTERESTS

None declared.

PATIENT CONSENT

Obtained.

REFERENCES

1. Kothari PR, Kothari NP. Jejunal web with late presentation. *Indian Pediatr* 2003; 40: 1109-10.
2. Jayachandra S, Eslick GD. A systematic review of paediatric foreign body ingestion: presentation, complications, and management. *Int J Pediatr Otorhinolaryngol* 2013; 77: 311-7.
3. Litovitz TL. Battery ingestions: product accessibility and clinical course. *Pediatrics* 1985; 75: 469-76.
4. Tokar B, Cevik AA, Ilhan H. Ingested gastrointestinal foreign bodies: predisposing factors for complications in children having surgical or endoscopic removal. *Pediatr Surg Int* 2007; 23: 135-9.
5. De Backer T, Voet V, Vandenplas Y, Deconinck P. Simultaneous laparotomy and intraoperative endoscopy for the treatment of high jejunal membranous stenosis in a 1-year-old boy. *Surg Laparosc Endosc* 1993; 3: 333-6.