

CASE REPORT

Beta-ketothiolase deficiency in a Malaysian infant

Rajan Duda, MD¹, Constance Liew Sat Lin, M.MED¹, Brandon Patrick, MBBS²

¹Department of Medical Sciences, Universiti Malaysia Sabah, ²Department of Paediatrics, Sabah Women and Children Hospital, Likas, Sabah

SUMMARY

Methylacetoacetyl-coenzyme A thiolase (MAT) deficiency is an autosomal recessive disease caused by a defect of mitochondrial acetoacetyl-CoA thiolase (T2). There is an error of isoleucine catabolism and ketone body utilization due to mutations in the acetyl-Coenzyme A acetyltransferase 1 (ACAT1) gene. We report a case of a 14 months old Sabahan boy with beta deficiency who presented with severe sepsis and ketoacidosis who subsequently recovered..

CASE PRESENTATION

A 14-month-old boy, birth weight of 2.9kg and current weight of 7.72kg (weight and height on third centile) presented with two days of fever and flu like symptoms. Developmental milestone seemed appropriate for the age. Parents are non-consanguineous. The other three siblings were normal.

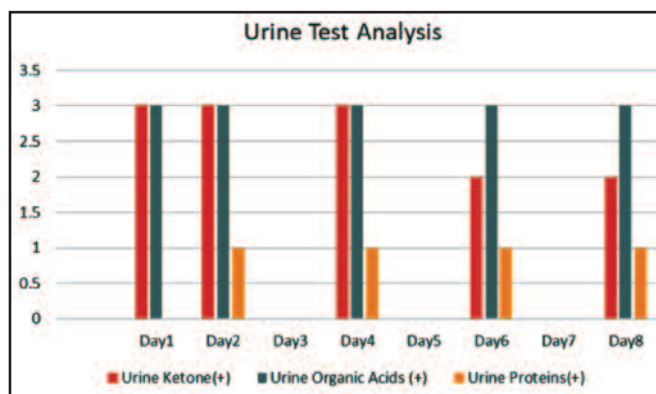
Initially he appeared active, tachypneic. He was admitted with initial diagnosis of acute bronchiolitis and given nebulized salbutamol. On the third day, he became more tachypneic and lethargic with severe metabolic acidosis. He was intubated for impending acute respiratory failure. He developed shock like symptoms and was started on adrenaline infusion of 0.2mcg/kg/min and fluid resuscitation with 20ml/kg of Normal Saline 0.9% three times, at the Kota Marudu Hospital. As he reached Likas Hospital PICU, inotropic support was slowly weaned off over the next two days. After initiating sepsis work up, empirical antimicrobial therapy C-Penicillin and cefotaxime was started to cover for meningitis as the child was restless and had doubtful opisthotonos.

Blood glucose was maintained 4-12mmol/L. Initial clinical impression was severe sepsis secondary to bronchiolitis/meningitis complicated with severe metabolic acidosis. Differential diagnosis was to rule out inborn error of metabolism with severe metabolic acidosis.

Laboratory tests showed WBC was increased and a negative blood test for Leptospirosis. Lumbar puncture was done and CSF analysis was not suggestive of meningitis. His echocardiography showed grossly normal heart structure and function. Chest X-ray revealed bilateral peripheral haziness.

Urine analysis showed positive urine ketone (3+). Other blood tests were elevated serum Ketones (12mmol/L), elevated ammonia (172mmol/l) and normal lactate (0.37mmol/L).

Table I: Urine Organic acid Analysis in the patient Day 1 to Day 8



Blood culture grew *Morexella* species, repeat blood culture was negative. The growth was possibly a contaminant. CSF and urine cultures were negative while tracheal and stool culture revealed normal flora. The antibiotics were escalated to Cefepime and clindamycin and the clinical picture was suggestive of sepsis. Urinary organic acid analysis was suggestive of Betaketothiolase deficiency (Table I).

After resolution of the ketoacidosis crisis and septic shock, our patient had multiple failed attempt of extubations. In view of possible neuromuscular sequelae, MRI brain was performed that revealed bilateral non-specific white matter hyperintensity in peritrigonal regions in the zone of terminal myelination possibly due to ischemic/ hypoxic events.

He was on the ventilator for 3 days and Bilevel Positive Airway Pressure for 7 days. He was gradually able to wean to venti-mask over 1 month and finally off oxygen therapy after 2 weeks.

DISCUSSION

The signs and symptoms of beta- ketothiolase deficiency appear between the ages of 6 -24 months, and in some rare cases up to 3-7 years. Affected children experience episodes of vomiting, dehydration, difficulty in breathing, unexplained lethargy and seizures. These episodes which are called keto-acidotic attacks can lead to coma. The triggering factors can be infections, periods without foods, or increased intake of high protein food.

This article was accepted: 3 February 2019

Corresponding Author: Associate Professor Dr Rajan Duda

Email: rajan_duda@hotmail.com

Key to suspicion to this clinical condition is an exaggerated metabolic acidosis, with trivial trigger, abrupt onset and rapid progression which is disproportionate to the normal progress in other conditions.

The diagnosis is based on plasma amino acid profile which shows mild increase of glutamine, glycine and low cystine and low arginine. Acylcarnitine profile shows elevated Tiglyl carnitine (C5:1) and elevated 2 methyl – 3 hydroxy butyrate carnitine (C5OH). Serum ketone was 12mmol/L in our patient, during the keto-acidotic attacks, a serum ketone concentration > 7 mmol/L was the major finding. It was also accompanied by urinary organic acids: increased 3 hydroxybutyric acid, Increased 2 methyl – 3 hydroxybutyric acid, increased tiglylglycine. serum ketone was 12mmol/L in our patient, during keto-acidotic attacks, a serum ketone concentration > 7 mmol/L is the major finding. Blood tests and genetic analysis of genome DNA particularly ACAT1 gene remain the gold standard to confirm the diagnosis.

MANAGEMENT GOAL

The management goal of MAT deficiency is the prevention of further ketoacidotic crisis, prompt treatment of acute attacks, and screening of family members before the development of acute or chronic clinical manifestations of T2 deficiency.⁴

There is no evidence to support the effectiveness of these preventive measures for further ketoacidotic attack. If patients develop fever and or vomiting, increased carbohydrate intake and intravenous glucose infusion are advised. Maintaining blood glucose at the upper limit of the normal value will help to suppress ketogenesis.

Secondly adequate intravenous fluids and electrolytes is needed to maintain good urine output and normal serum electrolytes levels. Thirdly if blood pH is <7.1 and PCO₂ is <40mmHg, a bolus of bicarbonate (1 mmol/kg over 10-15 minutes) should be given and guided by regular blood gases and electrolytes monitoring to avoid hypernatremia and /or rapid correction of metabolic acidosis.²

Monitoring urinary ketone bodies and early medical referral for advice in such condition of moderate or severe ketonuria. Mild protein restriction, avoidance of a fat-rich diet, and L-carnitine supplementation, particularly in cases with low carnitine level, is also advised.^{2,4}

CONCLUSION

This case demonstrates that prompt resuscitative measures can be lifesaving and the clinical picture, blood and urinary organic acid/ketone profile is diagnostic of Beta-Ketothiolase deficiency. To the best of our knowledge this is a first case report of this disorder in a Sabahan infant. The important message is that, when confronted with severe metabolic acidosis and hyperketonemia in a non- diabetic patient that is disproportionate to the intercurrent respiratory illness, the physician must keep in mind the possibility of organic acidemia/ketonemia due to inborn error of metabolism. Early diagnosis and management of Beta- Ketothiolase deficiency will enable the prevention of serious acute and chronic complications and improve remarkably the prognosis.

ACKNOWLEDGMENTS

The authors thank UMS Kota Kinabalu, Sabah Women and Children Hospital for supporting us.

DECLARATION OF CONFLICTING INTERESTS

The author(s) declared no potential conflicts of interest with respect to the research, authorship, and/or publication of this article.

REFERENCES

1. DaumRS, Lamm PH, Mamer OA, Scriver CR. A “new” disorder of isoleucine catabolism. =Lancet 1971; 2(7737): 1289-90.
2. Fukao T, Nguyen HT, Nguyen NT, Vu DC, Can NT, Pham A et al. A common mutation, R208X, identified in Vietnamese patients with mitochondrial acetoacetyl-CoA thiolase (T2) deficiency. Mol. Genet. Metab. 2010; 100(1): 37-41.
3. Abdelkreem E, Otsuka H, Sasai H, Aoyama Y, Hori T, El Aal MA et al. Beta-Ketothiolase deficiency: resolving challenges in diagnosis. Journal of Inborn Errors of Metabolism and Screening 2016;4: 1-9.
4. Fukao T, Scriver CR, Kondo N; t2 Collaborative Working Group. The Clinical Phenotype and Outcome of Mitochondrial Acetoacetyl-CoA Thiolase Deficiency (β-Ketothiolase or T2 Deficiency) in 26 Enzymatically Proved and Mutation-Defined Patients. Mol Genet Metab 2001; 72(2): 109-14.