

Recurrent occipital dermatofibrosarcoma protuberans tackled with wide local excision: A case report and current management

Jasmine Kho Pei Ying, MBBS¹, Boon Han Kevin Ng, MBBS², John Ranjit, MBBS, Masters in Plastic and Reconstructive Surgery³

¹Department of Otorhinolaryngology, Sarawak General Hospital, Sarawak, Malaysia, ²Trainee lecturer, Department of Otorhinolaryngology, Faculty of Medicine and Health Sciences, University Malaysia Sarawak, Sarawak, Malaysia, ³Consultant Plastic Surgeon, Department of Plastic and Reconstructive Surgery, Sarawak General Hospital, Sarawak, Malaysia

SUMMARY

Dermatofibrosarcoma protuberans (DFSP) is a slow-growing, locally invasive tumour of the dermis. It commonly presents in the trunks and proximal extremities but is seen to a lesser extent in the head and neck regions. We present a case report of a recurrent DFSP in a 48-year-old Iban woman at the occipital region. The patient underwent wide local excision and removal of outer table of cranium, dressing followed by split thickness skin graft. Histopathological examination confirmed dermatofibrosarcoma protuberans with clear lateral surgical margins and a deep margin of 0.5mm. She is currently undergoing radiotherapy and is planned for 50Grey 25cycles.

INTRODUCTION

Dermatofibrosarcoma protuberans (DFSP) is a rare cutaneous tumour known for its high rate of recurrence and low risk for metastasis. Darrier and Ferrand first described it in 1924, however Hoffman coined the term DFSP in 1925.¹ The most observed site of presentation is the trunk, followed by the extremities and the head and neck.^{1,2}

CASE REPORT

A 48-year-old Iban woman presented to a district hospital with a left occipital swelling in 2013. Histopathological Examination (HPE) post excision showed dermatofibrosarcoma protuberans, with all surgical margins involved. She refused further treatment due to logistic and financial issues, and subsequently defaulted further follow up.

In 2015, she developed a recurrent left occipital swelling which progressively increased in size over the past year. It was painless, smooth surfaced, fixed, no erythema and not fluctuant. A Computer Tomography (CT) scan of the head showed a well-defined exophytic heterogenous enhancing solid mass measuring 1.2cm x 4.0cm x 4.4cm (Fig.1). There was no skull vault or intracranial extension. A wide local excision with a 5cm circumferential surgical margin was

taken, complimented with removal of the outer table of the cranium by burring and osteotomy (Fig. 2,2e). The wound was allowed to granulate while awaiting HPE confirmation, then closed by split thickness skin graft after 35 days. Histopathological examination confirmed DFSP with all margins more than 2cm from the tumour, 0.5mm away from deep margin (Fig. 2b). The bony cranium was still undergoing decalcification which may take up to a year to process. Immunohistochemical staining was positive for CD 34 expression, negative for SMA, Desmin, S100 and CKAE1/AE3 (Fig.2c). The wound healed well, and the patient was referred to Oncology team. She is currently undergoing radiotherapy and is planned for 50Grey 25cycles.

DISCUSSION

DFSP is a rare cutaneous neoplasm, locally infiltrative and has a high frequency of recurrence.^{1,2} DFSP accounts for less than 0.1% of all malignant neoplasms and approximately 1% of all soft tissue sarcomas.

It may initially present as a raised, firm pink to red-bluish painless lesion which may ulcerate in time. Its slow growing indolent nature allows it to go unnoticed for many years. Its characteristic microscopical appearance consists of an arrangement of spindle-shaped tumour cells in a "cartwheel" pattern with no nuclear atypia nor increased mitotic activity.¹ However, infiltration of the dermis and surrounding fat is characteristic.¹ It has strong positivity for CD34 on immunohistochemical staining, as well as Vimentin. To differentiate DFSP from benign fibrous histiocytoma (dermatofibroma) or other malignant tumours such as Malignant Peripheral Nerve Sheath Tumours (MPNST) and rare variants of spindle-cell malignant melanoma, Stromelycin 3 (ST3) and factor XIIIa may be employed.^{1,2} West et. al proposed Apolipoprotein D as another novel marker to differentiate DFSP from dermatofibroma. If there arises difficulty in diagnosis, fluorescence in situ hybridisation (FISH) or multiplex reverse transcriptase-polymerase chain reaction (RT-PCR) which detects chromosomal translocations and fusion gene transcripts may be considered.^{1,3}

This article was accepted: 6 December 2018

Corresponding Author: Boon Han Kevin Ng

Email: nivekalt@yahoo.com

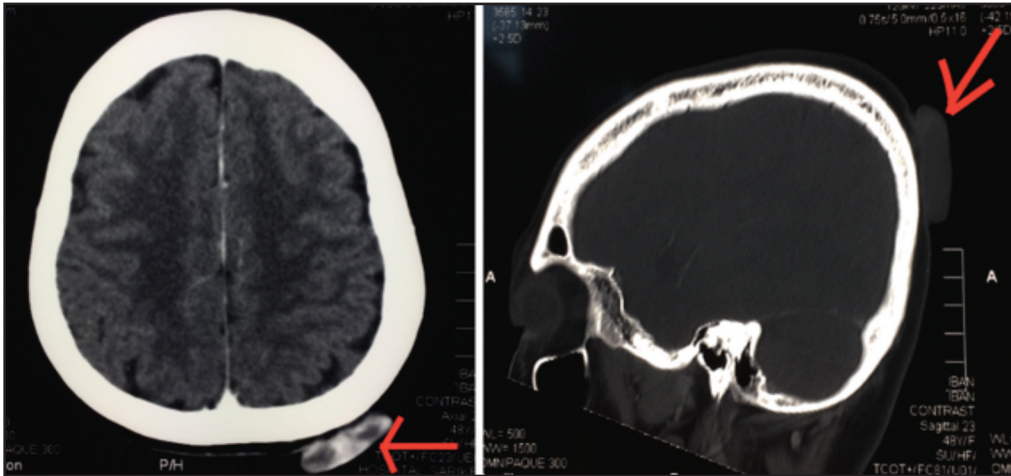


Fig. 1: CT scan showing a solid mass 4x4x1cm(arrow) with no cranial vault extension

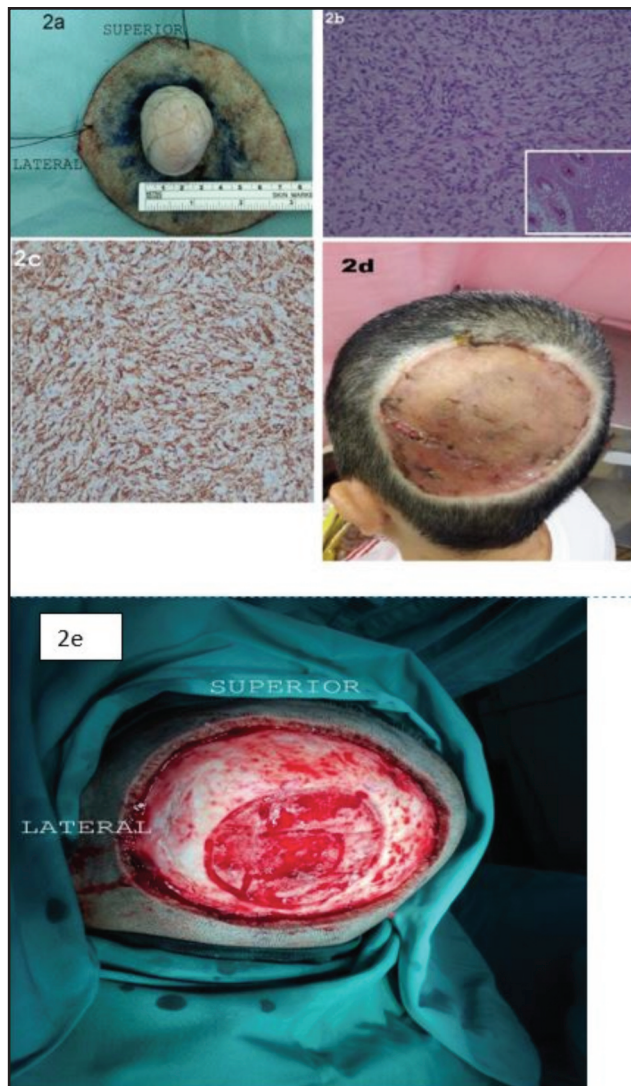


Fig. 2: a. Macroscopic view of tumour post excision.
 b. DFSP showing uniform, spindle shaped neoplastic cells arranged in a storiform growth pattern (Insert: Infiltration of fat seen)
 c. Immunohistochemistry staining positive for CD34 marker
 d. Post-operative surgical site.
 e. Post-surgical excision intra operative view.

Magnetic resonance imaging (MRI) is recommended, to assist in determination of extent of tumour spread and may be used as surveillance for recurrence of disease.² Park et al., found limited value for computed tomography (CT) except for evaluation of bony involvement, as utilized in our patient's case.

The recommended standard treatment is wide local excision, with a minimum 3cm margin for control of local disease.^{1,2} Roses et al., reported when surgical margins were equal to or more than 2cm, the rate of recurrence was 24%, which increased to 41% if the surgical margin was less than 2cm. Lindner et al. found that a 2.5cm to 3.5 cm circumferential excision of healthy tissues improved local control of the disease. Angouridakis reported close margins less than 2cm statistically increased rate of recurrence.¹ This is supported by a study done by Cai et al. whom found patients undergoing wide excision with a 1.5-2.5cm surgical margin had a 13.6% recurrence rate, compared with those margins more or equal to 3cm had significantly lower recurrence rate of 5.7%. In our patient, we took a 5cm circumferential margin, and proceeded with removal of outer table of cranium by burring and osteotomy, to ensure that the deep margin where the tumour lay is clear, thus reducing the risk of recurrence.

Definitive reconstruction should only be attempted after clearing all surgical margins.² An alternative approach is Mohs micrographic surgery (MMS) which only requires 1cm to 1.3cm lateral safety excision margins.^{1,2} MMS allows immediate microscopic examination of the margins, and has a less than 2% recurrence rate.^{1,2} However, MMS is not favoured as it requires a specialized team and is more time consuming for larger tumors.^{1,2}

Imatinib, a PDGF receptor-selective oral tyrosine kinase-inhibitor, is indicated in patients with unresectable primary or recurrent tumour, locally advanced or metastatic disease.^{1,2} It may also be considered as a neo-adjuvant therapy for preoperative reduction of tumour size.^{1,2}

Radiation therapy is another option for primary inoperable tumours, fibrosarcomatous transformation, multiple recurrences or may be employed as adjuvant treatment, when surgical margins are near or persistently positive.^{1,2} Radiation therapy reduces the risk of local relapse after resection of tumour in close or positive margins.²

Chemotherapy, is argued to be ineffective.^{1,2} However, Kamar et al., published an unprecedented alternative treatment, involving the use of Sorafenib, in the management of recurrent DFSP. He reported a case of persistent recurrent DFSP of the upper torso, invading the neck and shoulder region. Failing multiple resections, two courses of radiation therapy and Imatinib, Sorafenib was elected as a salvage option. Sorafenib was chosen in view of its positive response in treating angiosarcomas and other subtypes of sarcomas.³ It is a small molecular inhibitor of Raf kinase, PDGF (platelet-derived growth factor) inhibitor and vascular endothelial growth factor (VEGF) receptor inhibitor. It is more known for its use in treating advanced Hepatocellular carcinoma (HCC), Renal cell carcinoma (RCC) and differentiated thyroid carcinoma. The patient received Sorafenib 800mg daily, and showed dramatic improvement within a few days of the treatment.

CONCLUSION

DFSP is a relatively uncommon, slow growing subcutaneous tumour, which is locally invasive but rarely metastatic.^{1,2} The current recommended standard treatment is wide local excision with a minimum 3cm margin.^{1,2} Imatinib and radiation therapy may be considered when the tumour is inoperable or surgical margins are not clear.^{1,2} DFSP has high recurrence rates, and can be difficult to manage when it presents with extensive local invasion. The usage of Sorafenib and other targeted therapy, needs to be further studied.

REFERENCES

1. Angouridakis N, Kafas P, Jerjes W, Triaridis S, Upile T, Karkavelas G, Nikolaou A. Dermatofibrosarcoma protuberans with fibrosarcomatous transformation of the head and neck. *Head Neck Oncol* 2011; 3: 5.
2. Saiag P, Grob JJ, Lebbe C, Malvehy J, del Marmol V, Pehamberger H et al. Diagnosis and treatment of dermatofibrosarcoma protuberans. European consensus-based inter- disciplinary guideline. *Eur J Cancer* 2015; 51(17): 2604-8.
3. Kamar FG, Kairouz VF, Sabri AN. Dermatofibrosarcoma protuberans (DFSP) successfully treated with sorafenib: case report. *Clin Sarcoma Res* 2013; 3: 5.