

# Scrotal emergencies: An imaging perspective

Chern Yue Glen Ong, FRCR<sup>1</sup>, Hsien Min Low, FRCR<sup>1</sup>, Chinchure Dinesh, FRCR<sup>2</sup>

<sup>1</sup>Department of Radiology, Tan Tock Seng Hospital, Jalan Tan Tock Seng, Singapore, <sup>2</sup>Department of Radiology, Khoo Teck Puat Hospital, 90 Yishun Central, Singapore

## SUMMARY

Acute scrotal pain is a common complaint in emergency or primary care practice. A myriad of pathologies need to be considered, and while the clinical history often leads the clinician to the correct diagnosis, radiologists are often called upon to provide further diagnostic information through ultrasonography. Here, we present the sonographic features of various scrotal emergencies, as well as a few pitfalls. Through this, we explore the breadth of urgent pathologies that may be encountered, both traumatic and non-traumatic. For the clinician who performs point-of-care ultrasound, whether in clinic or in the emergency department, we hope that this pictorial article will lay a good foundation for confident and accurate image interpretation.

## KEY WORDS:

Scrotum; scrotal; emergency; urology; ultrasound

## INTRODUCTION

Acute scrotal pain is a concerning symptom that warrants prompt and thorough clinical assessment. Much of the radiological evaluation is directed at assessing testicular viability, which if threatened, would warrant urgent surgical exploration. Both greyscale and Doppler ultrasound are routinely employed as part of the evaluation, and performed either as a bedside study (point-of-care), or formally at the Radiology Department. The excellent spatial resolution, ability to assess vascularity in real-time, lack of ionising radiation, portability and ease of access make ultrasound the ideal imaging modality for urgent evaluation of the scrotum and testes.<sup>1-3</sup> Familiarity with the sonographic features of the scrotal contents in various disease states is essential for rapid and accurate interpretation.

This paper presents a collection of images depicting the scrotal emergencies commonly faced, as well as common pitfalls in image interpretation.

## SONOGRAPHIC ANATOMY

### 2.1 Scrotum

The scrotal lining consists of the skin, dartos muscle, external spermatic fascia, cremasteric muscle, and internal spermatic fascia. The layers are not separately discernible on ultrasound. The scrotal septum is formed by the dartos fascia, dividing the scrotum into two sacs. Normal scrotal thickness varies between 2-8mm.<sup>4</sup>

### 2.2 Testis

The testes are ovoid structures which are homogeneous in echotexture. Normal testicular size ranges from 3-5cm. The fibrous outer covering of the testis, the tunica albuginea, is seen as a thin continuous echogenic line, best seen in patients who have large hydrocoeles. The tunica albuginea is a tough fibrous layer that can withstand forces up to 50kg before rupturing.<sup>5</sup> The tunica albuginea invaginates into the interior of the testis to form the mediastinum testis, often visualised as an echogenic band coursing in a cranio-caudal direction. The testicular artery divides into branches which pierce the tunica albuginea to form capsular arteries known as the tunica vasculosa that arborise over the testicular surface. From these arise centripetal branches which converge over the mediastinum. The centripetal branches then give off recurrent rami which run centrifugally to supply the testicular parenchyma. A prominent transmediastinal artery is visualised in some patients.

### 2.3 Epididymis

The epididymis is divided into the head, body and tail. It is isoechoic to slightly hyperechoic when compared to the testicular parenchyma. The epididymal head is located at the superolateral aspect of the testis and has a characteristic triangular configuration. The head has a thickness ranging between 5-12mm.<sup>4</sup>

### 2.4 Spermatic Cord

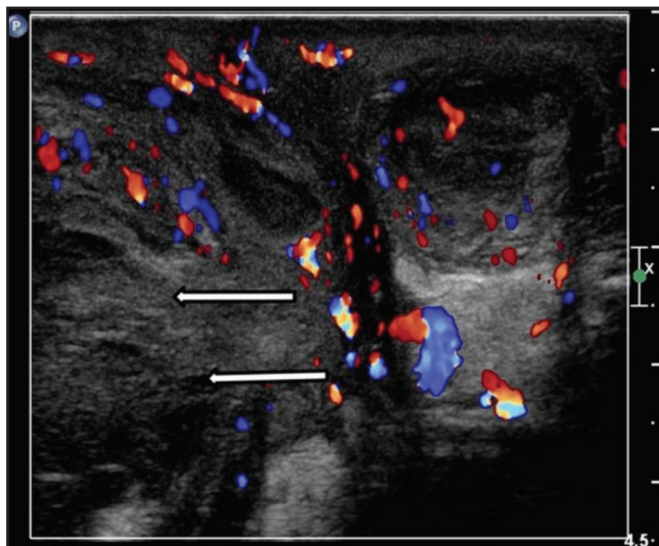
The spermatic cord consists of the vas deferens, vascular structures as well as nerves. It is ensheathed by the external spermatic fascia, cremasteric muscle and internal spermatic fascia. It traverses the inguinal canal into the scrotum.

## NON-TRAUMATIC CONDITIONS

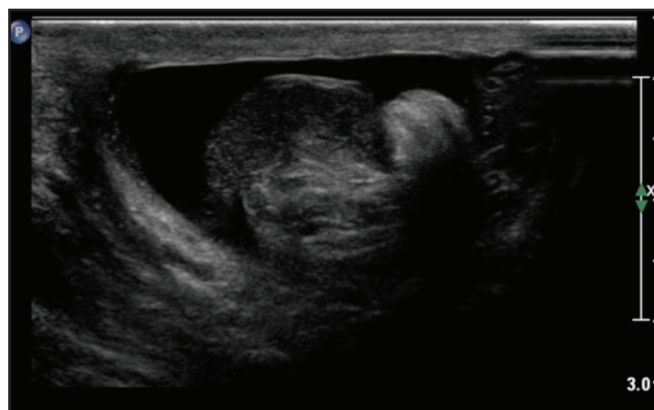### 3.1 Epididymitis and epididymo-orchitis

Epididymitis and epididymo-orchitis are the most common infective causes for scrotal pain and are usually due to bacterial infections caused by an ascending genitourinary tract infection. *Neisseria gonorrhoeae* and *Chlamydia trachomatis* are the common organisms that are responsible for the infection. As a result of the ascending infection, the epididymal tail is first involved followed by the body and head of the epididymis. The testis is involved due to direct extension of the infection from the epididymal head. If left untreated, epididymo-orchitis may progress to abscess formation and even infarction (Fig. 1). Testicular infarctions occur due to the oedematous, swollen testicular parenchyma being confined by the rigid, unyielding tunica albuginea. This causes venous occlusion and resultant vascular compromise, eventually culminating in testicular

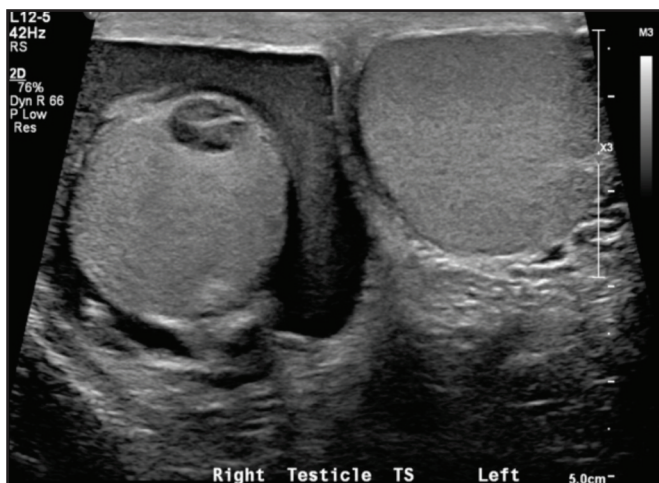This article was accepted: 9 March 2018  
Corresponding Author: Chern Yue Glen Ong  
Email: glenongcy@hotmail.com



**Fig. 1:** Severe infection leading to infarct. Clinical diagnosis of severe right epididymo-orchitis was made in the above patient. On ultrasound, there is diffuse scrotal wall thickening and hyperaemia. Small hypoechoic, avascular lesions in the scrotal wall and testicular parenchyma are consistent with abscesses. The testicular parenchyma shows heterogeneous echotexture with no discernible vascularity (arrows). Overall features suggest testicular infarction, secondary to severe infection. This was confirmed during surgery and the patient underwent an orchidectomy.



**Fig. 2:** Testicular torsion. A case of surgically confirmed torsion is presented. The spermatic cord appears thickened and whirl-like. There was occasional arterial flow but no detectable venous flow (not shown). The testis was found to be viable after surgical detorsion and re-warming. The patient underwent bilateral orchidopexy. Cinematic clips are often helpful in demonstrating the whirl-like appearance of the twisted vascular pedicle.



**Fig. 3:** Haematocoele. Transverse view of the testes shows a complex fluid collection on the right, representing a haematocoele. Parenchymal injury must always be carefully sought, as seen in this case of an associated intra-testicular haematoma.

infarction. On ultrasound, the findings of epididymitis and epididymo-orchitis include enlargement of the epididymis and testis, hypoechoic echotexture and increased vascularity. The scrotal skin is often thickened as part of the inflammatory reaction. Orchitis without epididymitis is rare, as the infection typically spreads in a retrograde fashion. Hence, in such instances, orchitis secondary to Mumps should be considered.

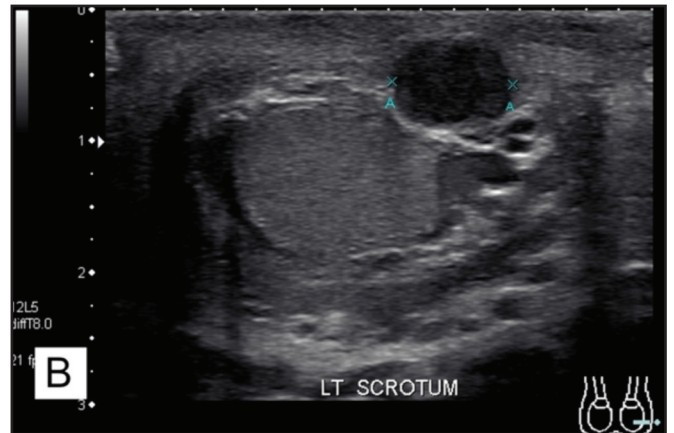
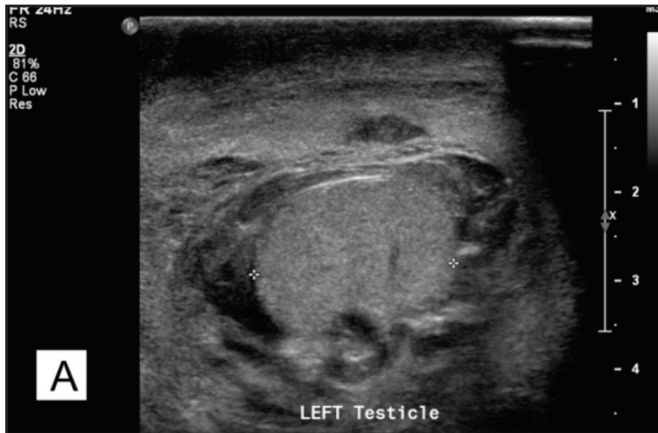If epididymo-orchitis is complicated by testicular infarction, the testis will show absent vascularity on Doppler ultrasound and may potentially be confused with testicular torsion.

### 3.2 Fournier's Gangrene

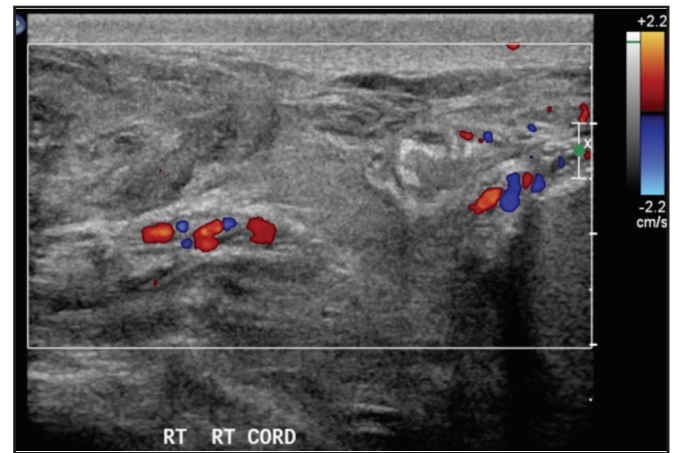
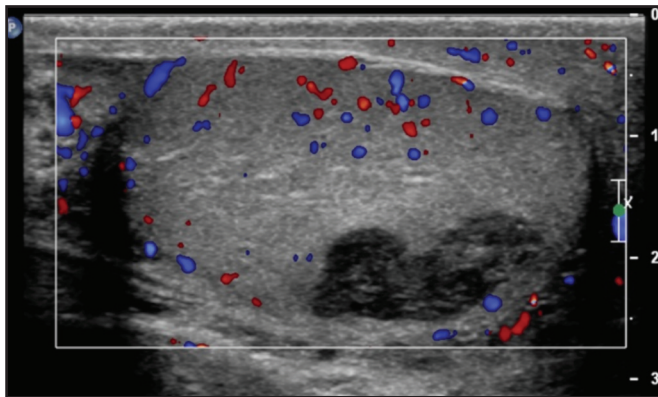
Fournier's gangrene is a fulminant necrotising infection of the perineum. Diagnosis should be clinically evident, and ultrasound is performed if there is concern for testicular viability. CT or MRI is the preferred modality to assess the extent of disease for surgical planning. Nonetheless, findings on ultrasound include thickened scrotal/perineal skin showing numerous echogenic foci with reverberation artefacts ('dirty' shadowing) representing gas locules.

### 3.3 Testicular Torsion

The estimated yearly incidence of testicular torsion is 3.8 per 100,000 in males younger than 18 years of age.<sup>6</sup> A common predisposing factor is the bell-clapper deformity, where the tunica vaginalis encircles the entire testis and attaches onto the distal spermatic cord, allowing the testis to freely rotate. In a series of 27 pubertal cases of testicular torsion, the bell-clapper deformity affected the contralateral testis in 78% of cases, supporting the routine practice of performing contralateral orchidopexy.<sup>7</sup> Testicular ischaemia precedes infarction, and when suspected, should prompt urgent intervention to restore perfusion and preserve testicular viability. In the context of testicular torsion, salvage rates approach 100% when detorsion is performed within 6 hours.<sup>8,9</sup> Identifying a twisted spermatic cord is highly specific for torsion (Fig. 2), although lacking in sensitivity.<sup>10</sup> Testicular echogenicity may be normal in early torsion, becoming progressively heterogeneous with prolonged ischaemia. This sequence of change in the testicular echotexture has been

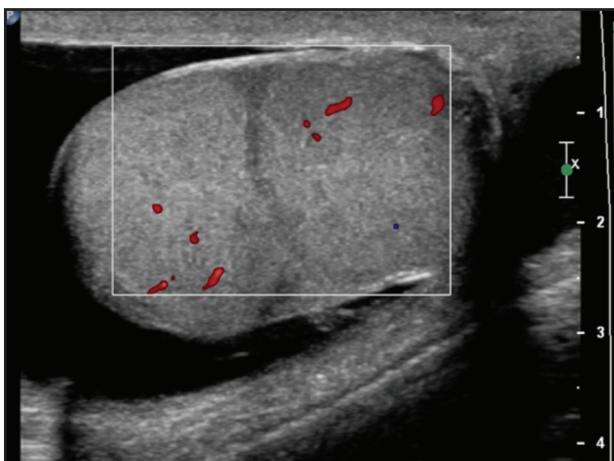


**Fig. 4: Scrotal wall haematoma**  
 Transverse view of the left scrotum shows that the overlying scrotal skin is thickened. An ovoid hypoechoic lesion with low level echoes is seen within the scrotal wall, representing a haematoma (A). Follow-up ultrasound 1 month later (B) shows the lesion to be larger and more hypoechoic, in keeping with expected temporal evolution. The skin thickening has improved and the haematoma now gently indents the underlying testis.



**Fig. 5: Intra-testicular haematoma**  
 This patient suffered blunt scrotal trauma. A well-defined hypoechoic lesion is seen within the testicular parenchyma. Doppler interrogation shows no internal vascularity.

**Fig. 6: Cord haematoma**  
 A large haematoma is seen along the right spermatic cord after blunt trauma to the scrotum. There is preserved vascular flow along the cord and testicular parenchyma (not shown). The patient was managed conservatively with serial follow-up imaging performed.

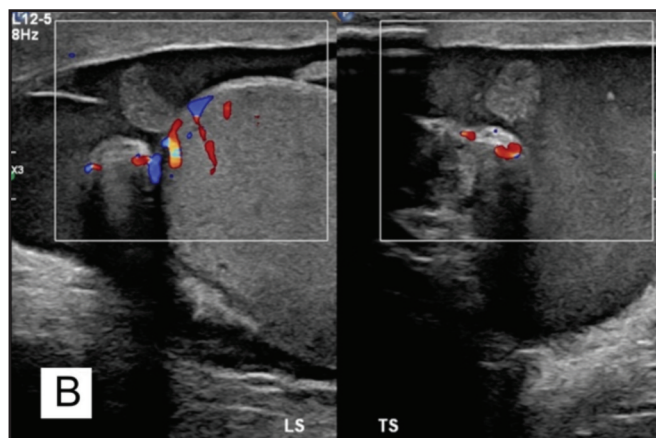
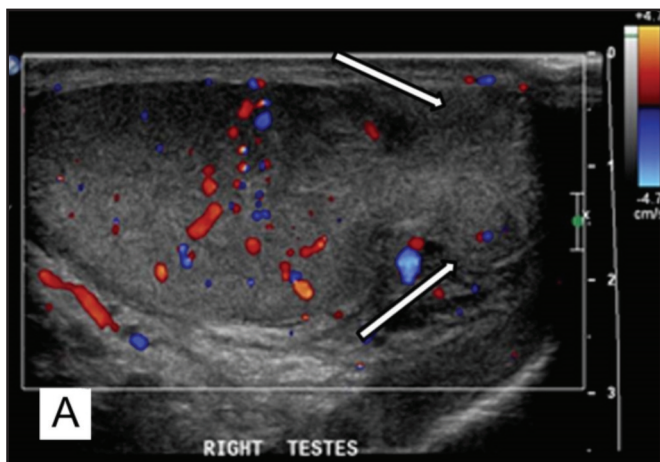


**Fig. 7: Testicular fracture**  
 An avascular hypoechoic line is seen across the testis with preserved vascularity in the adjacent parenchyma. The testicular contour is maintained and the tunica albuginea intact. The patient was managed conservatively.

shown to be useful in prognosticating salvage rates.<sup>11</sup> Doppler/spectral findings include present but diminished flow especially near the mediastinum, increased resistive indices as well as complete absence of vascular flow.<sup>12</sup> Other causes for ischaemia/infarction include severe infection and trauma. Torsion of the appendix testis occurs in young boys and can often mimic testicular torsion; this condition is managed conservatively.

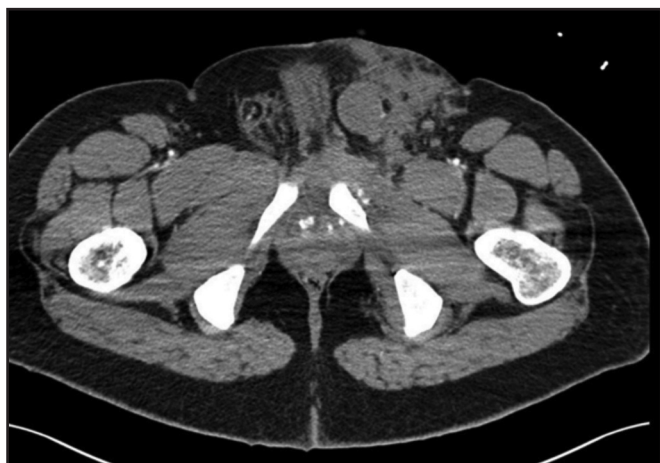
**TRAUMATIC CONDITIONS**

Blunt trauma to the scrotum can result in injury to any of the scrotal contents. Urgent surgical exploration is indicated if there is suspicion for testicular rupture or vascular compromise. For large haematocoeles without testicular rupture, a retrospective review showed that 40% of patients initially managed conservatively required delayed exploration,



**Fig. 8:** Testicular rupture

This longitudinal view shows contour deformity of the testis as well as extruded, avascular parenchyma at the lower pole (A, arrows). In another patient, an avascular lesion at the upper pole shows no continuity with the extruded parenchyma, representing an avulsed fragment (B). An associated haematocoele is noted. Both patients underwent urgent surgical exploration and repair.



**Fig. 9:** Testicular dislocation

This patient suffered an “open book” pelvic fracture as a result of motor vehicle accident. The emergency physician noted a large left scrotal haematoma but no palpable testis, raising the concern for testicular rupture. Subsequent trauma CT reveals a soft tissue density in the region of the left superficial inguinal ring with surrounding contusional change. On ultrasound (not shown), the left testis was found in the inguinal region, confirming the diagnosis.

while 15% required orchidectomy.<sup>13</sup> Conversely, prompt surgical evacuation allows for superior symptom relief, early rehabilitation and shorter hospital stay.<sup>13-15</sup> Traumatic testicular ischaemia may result from direct parenchymal disruption and vascular injury, or from elevated intraparenchymal pressure due to a large haematocoele or haematoma. Rare cases of traumatic testicular torsion have also been described.<sup>16</sup>

The radiologist should also be alert to potential injuries to the rest of the external genitalia and lower urinary tract, and advise further imaging as appropriate.

#### 4.1 Haematocoele and Haematoma

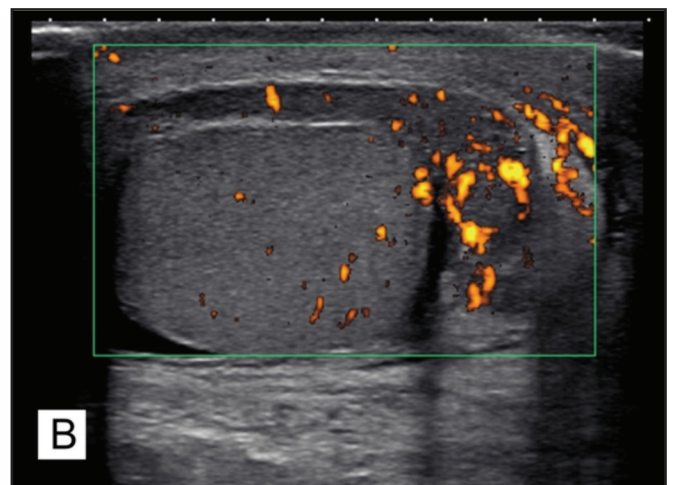
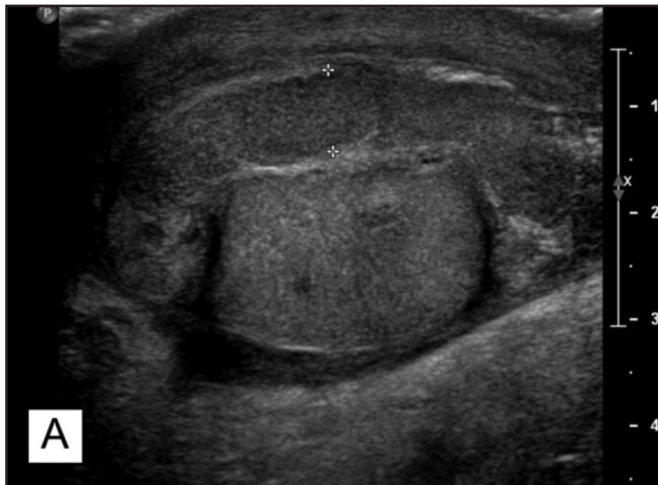A haematocoele refers to the collection of blood between the layers of the tunica vaginalis. It is often the most striking abnormality on ultrasound evaluation of scrotal trauma and should prompt the radiologist to carefully exclude associated injuries to the testicular parenchyma. As earlier discussed, a large or tense haematocoele should be considered for surgical evacuation. Haematocoeles are seen as complex fluid collections often with mobile internal echoes (Fig. 3). Haematomas may occur in the scrotal wall, testicular parenchyma and even the spermatic cord (Fig. 4-6). On ultrasound, haematomas are typically well-circumscribed heterogeneous lesions that become more hypoechoic as they regress over time. Internal vascularity is not a feature, and if present, should raise the suspicion of a tumour.

#### 4.2 Testicular Fracture and Testicular Rupture

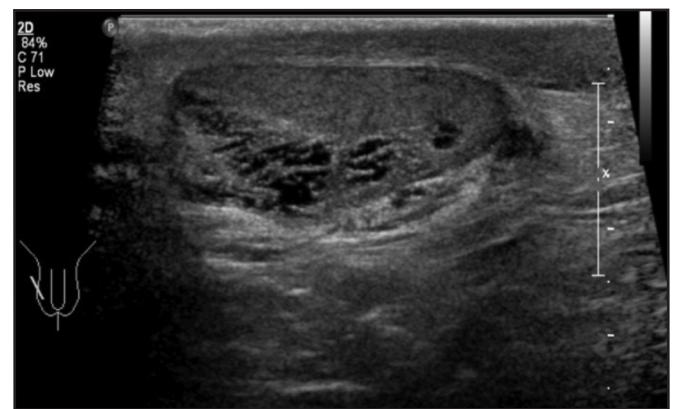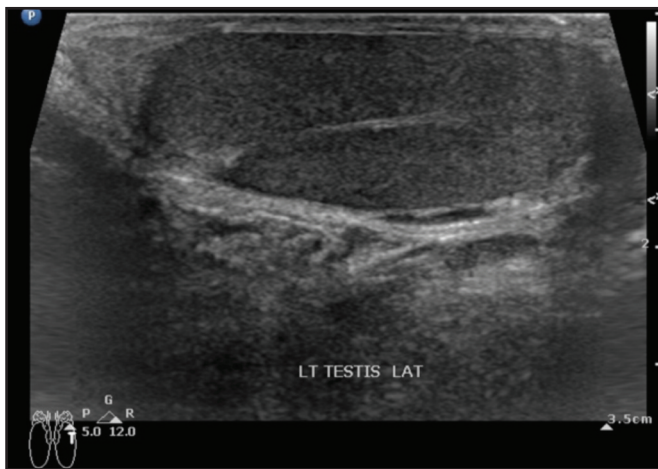
A fracture of the testis refers to a break in the testicular parenchyma even as the surrounding tunica albuginea remains intact. On ultrasound, a fracture is seen as an avascular hypoechoic line across the parenchyma; there is continuity of the hyperechoic tunica albuginea (Fig. 7). Testicular rupture is a more severe injury in which there is disruption of the tunica albuginea; the testicular contour is abnormal and extruded parenchymal fragments may be visualised (Fig. 8).

#### 4.3 Testicular Dislocation

Testicular dislocation is a rare condition resulting from high-impact straddle injury, most commonly due to a motorcycle collision.<sup>17</sup> When clinically suspected, an ultrasound examination should be performed to locate the testis as well as to evaluate for other associated injuries such as testicular rupture or torsion of the dislocated testis.<sup>17</sup> The dislocated testis is most commonly found in the superficial inguinal pouch (Fig. 9), and early repositioning – either via manual closed reduction or open surgery – is advocated.<sup>18, 19</sup>

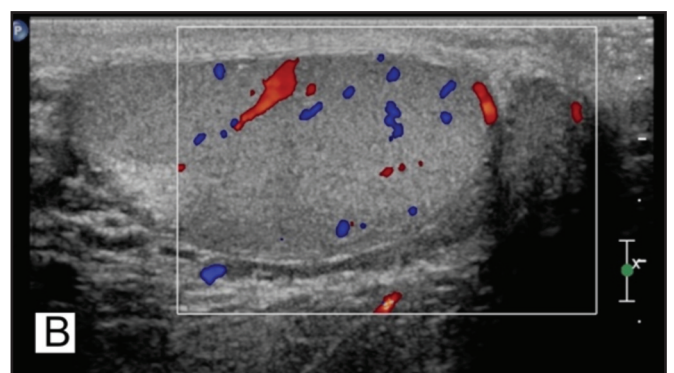
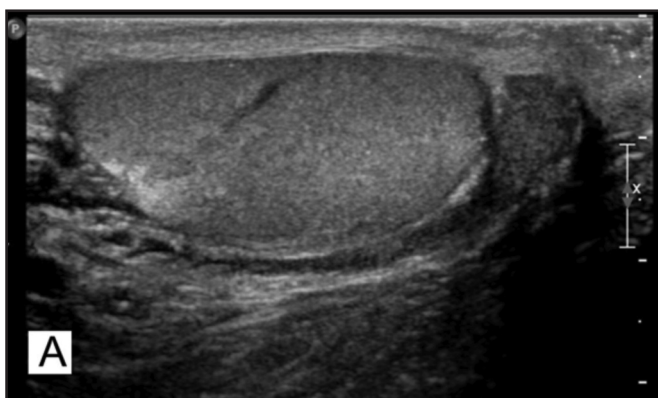

**Fig. 10: Traumatic epididymitis**  
Two examples of traumatic epididymitis are presented (A, B). The epididymis is thickened and hypervascular. The segments of the epididymis show continuity with no evidence of fracture. Note also the thickening of the overlying scrotal skin. The clinical history is essential to making the diagnosis, given that imaging findings are similar to those of infective epididymitis.

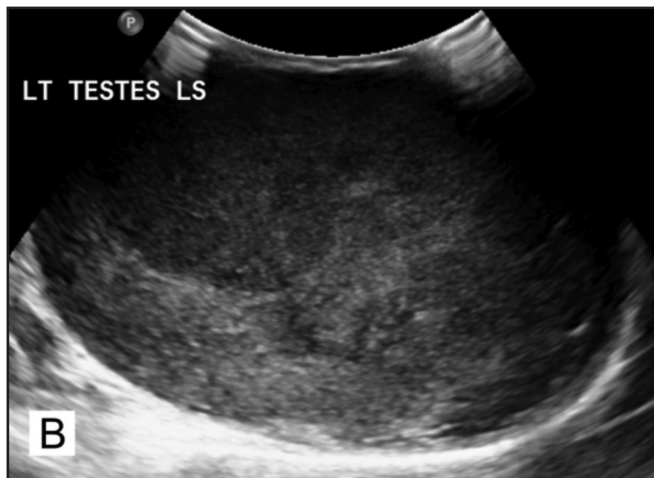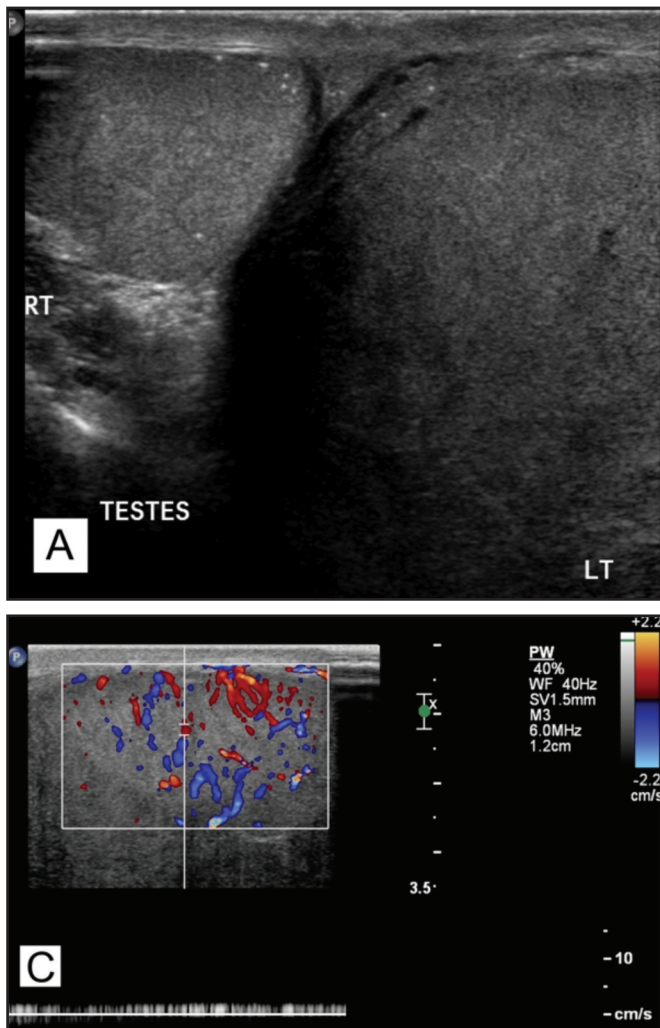


**Fig. 11: Mediastinum testis**  
A longitudinal view of the testis is shown. The mediastinum of the testis is shown as an echogenic band traversing the testicular parenchyma. Note how it is continuous with the tunica albuginea as it invaginates into the testicle.

**Fig. 12: Ectasia of the rete testis**  
Multiple hypoechoic tubular structures located at the mediastinum represent ectasia of the rete testis. Although considered a normal variant, it may occur after vasectomy/pelvic surgery or trauma. It should not be mistaken for haematoma or tumour.



**Fig. 13: Transmediastinal artery**  
Longitudinal image of the testis shows a linear hypoechoic structure coursing towards the mediastinum (A). This was resolved on Doppler imaging to represent a transmediastinal vessel, rather than a fracture (B).



**Fig. 14: Hypervascular Testicular Tumour**  
 This 20 year old patient presented to the emergency department for recent left testicular swelling and pain. He also offered a history of fever and coryzal symptoms for the past 2 days. Gray-scale images show a markedly enlarged and heterogeneous left testis (A,B). On Doppler imaging, hypervascularity is demonstrated (C). Despite the discordant clinical history, the imaging findings are highly suspicious for malignancy. The patient underwent a radical orchidectomy and histology confirmed a seminoma.

**4.4 Traumatic Epididymitis**

Traumatic epididymitis is a rare phenomenon encountered in blunt trauma of the scrotum. The epididymis is thickened, heterogeneous and shows increased vascularity (Fig. 10). Although the findings mimic those seen in infective epididymitis, the clinical history should provide clarification. Traumatic epididymitis is managed conservatively, unless another injury is found that warrants surgery.<sup>20</sup>

**COMMON PITFALLS**

Pitfalls may arise from modality specific technical factors, anatomical variants or incomplete clinical information. Failure to recognise imaging pitfalls can lead to diagnostic error, delayed or unnecessary treatment, as well as medico-legal consequences.

Firstly, normal anatomical features or variants should not be mistaken for pathology. These include mediastinum testis (Fig. 11), ectasia of the rete testis (Fig. 12) and transmediastinal artery (Fig. 13).

It is worth mentioning that up to 10-15% of testicular tumours are diagnosed on imaging for scrotal trauma.<sup>21</sup> Any focal testicular lesion showing internal vascularity should

raise the concern for tumour and not be mistaken for a haematoma.<sup>5</sup> Likewise, a testicular tumour may occasionally masquerade as infection, especially when no discrete mass is visualised and hypervascularity is present (Fig 14). In such scenarios, correlation with a careful history and physical examination is vital. If concomitant features of inflammation (scrotal thickening and erythema, urinary symptoms, epididymitis, etc) are absent, a tumour should be suspected. Should there be equivocal findings on imaging, a follow-up ultrasound examination would be prudent to ensure that the inflammatory findings resolve.

The entity of intermittent testicular torsion, or torsion-detorsion, is characterized by acute onset, possibly recurrent scrotal pain that resolves spontaneously. Both gray-scale and Doppler findings are variable, and may well mimic those of epididymitis/epidymo-orchitis when there is hyperaemia due to restored blood flow. The whirlpool sign and presence of pseudomass are features suggestive of intermittent torsion, even in the absence of pain.<sup>22</sup>

Finally, one should also be aware that scrotal pain may be referred from intra-abdominal pathologies such as those related to the urinary tract, and even the abdominal aorta.<sup>23,24</sup>

**CONCLUSION**

The causes for scrotal pain are myriad. True scrotal emergencies that potentially require urgent intervention can be broadly classified into two aetiologies – trauma and ischaemia. Ultrasonography is the imaging modality of choice in the emergency setting, although surgical exploration should not be delayed for imaging if there are clear indications for exploration.<sup>3,25</sup>

**CONFLICTS OF INTEREST AND FUNDING**

This research did not receive any specific grant from funding agencies in the public, commercial, or not-for-profit sectors. The authors declare that they have no disclosures and no conflicts of interest.

**REFERENCES**

1. Blaivas M, Sierzynski P, Lambert M. Emergency evaluation of patients presenting with acute scrotum using bedside ultrasonography. *Acad Emerg Med* 2001; 8(1): 90-3.
2. Gatti JM, Patrick Murphy J. Current management of the acute scrotum. *Semin Pediatr Surg* 2007; 16(1): 58-63.
3. Remer EM, Casalino DD, Arellano RS, Bishoff JT, Coursey CA, Dighe M, et al. ACR Appropriateness Criteria © acute onset of scrotal pain--without trauma, without antecedent mass. *Ultrasound Q* 2012; 28(1): 47-51.
4. Hricak H, Filly R. Sonography of the Scrotum. *Investigative Radiology*. 1983; 18: 112-21.
5. Bhatt S, Dogra VS. Role of US in testicular and scrotal trauma. *Radiographics*. 2008; 28: 1617-29.
6. Zhao LC, Lautz TB, Meeks JJ, Maizels M. Pediatric testicular torsion epidemiology using a national database: incidence, risk of orchiectomy and possible measures toward improving the quality of care. *J Urol* 2011; 186(5): 2009-13.
7. Martin AD, Rushton HG. The prevalence of Bell Clapper Anomaly in the solitary testis in cases of prior perinatal torsion. *J Urol* 191: 1573-7.
8. Lemke U, Beyersdorff D, Asbach P. The Male Genitals. In: Hamm B, Asbach P, Beyersdorff D, Hein P, Lemke U, editors. *Direct Diagnosis in Radiology Urogenital Imaging*: Thieme; 2008. p. 164-5.
9. Master V. Scrotal Emergencies. In: Hohenfellner M, Santucci RA, editors. *Emergencies in Urology*: Thieme; 2007. p. 132-41.
10. Baud C, Veyrac C, Couture A, Ferran JL. Spiral twist of the spermatic cord: a reliable sign of testicular torsion. *Pediatr Radiol* 1998; 28(12): 950-4.
11. Chmelnik M, Schenk JP, Hinz U, Holland-Cunz S, Gunther P. Testicular torsion: sonomorphological appearance as a predictor for testicular viability and outcome in neonates and children. *Pediatr Surg Int* 2010; 26(3): 281-6.
12. Prando D. Torsion of the spermatic cord: the main gray-scale and doppler sonographic signs. *Abdom Imaging* 2009; 34: 648-61.
13. Cass AS, Luxenberg M. Value of early operation in blunt testicular contusion with hematocele. *J Urol* 1988; 139: 746-7.
14. Bandi G, Santucci RA. Controversies in the management of male external genitourinary trauma. *J Trauma* 2004; 56(6): 1362-70.
15. Lee SH, Bak CW, Choi MH, Lee HS, Lee MS, Yoon SJ. Trauma to male genital organs: a 10-year review of 156 patients, including 118 treated by surgery. *BJU Int* 2008; 101(2): 211-5.
16. Seng YJ, Moissinac K. Trauma induced testicular torsion: a reminder for the unwary. *Journal of Accid Emerg Med* 2000; 17(5): 381-2.
17. Shefi S, Mor Y, Dotan ZA, Ramon J. Traumatic testicular dislocation: a case report and review of published reports. *Urology*. 54: 744.
18. Perera E, Bhatt S, Dogra VS. Traumatic ectopic dislocation of testis. *J Clin Imaging Sci* 2011; 1: 17.
19. Zavras N, Siatelis A, Misiakos E, Bagias G, Papachristos V, Machairas A. Testicular Dislocation After Scrotal Trauma: A Case Report and Brief Literature Review. *Urol Case Rep* 2014; 2(3): 101-4.
20. Gordon LM, Stein SM, Ralls PW. Traumatic epididymitis: evaluation with color Doppler sonography. *AJR Am J Roentgenol* 1996; 166(6): 1323-5.
21. Herbener TE. Ultrasound in the assessment of the acute scrotum. *Journal of clinical ultrasound*. *J Clin Urol* 1996; 24: 405-21.
22. Munden MM, Williams JL, Zhang W, Crowe JE, Munden RF, Cisek LJ. Intermittent Testicular Torsion in the Pediatric Patient: Sonographic Indicators of a Difficult Diagnosis. *AJR Am J Roentgenol* 2013; 201: 912-8.
23. Khalil A, Luk T. Ruptured abdominal aortic aneurysm presenting as testicular pain. *BMJ Case Reports*. 2009; 2009.
24. Sufi PA. A rare case of leaking abdominal aneurysm presenting as isolated right testicular pain. *CJEM* 2007; 9(2): 124-6.
25. Pepe P, Panella P, Pennisi M, Aragona F. Does color Doppler sonography improve the clinical assessment of patients with acute scrotum? *Eur J Radiol* 2006; 60(1): 120-4.