

# Fatal Leptospirosis and *Escherichia coli* co-infection in a post-partum woman

Thai Lun Tan, MBBS, Li Yuan Lee, MRCP, Wan Chieh Lim, MRCP

Department of Internal Medicine, Hospital Seri Manjung, Manjung, Perak Malaysia

## SUMMARY

The occurrence of Leptospirosis and *Escherichia coli* co-infection in the post-partum period is a novel case. This report illustrated a previously well woman from a suburban area presented with acute neurological deterioration following a two days history of fever during her puerperal period. Early interventions with fluids, broad spectrum antibiotics and intensive supportive care were given. Despite that, she deteriorated rapidly and developed pulmonary hemorrhage, disseminated intravascular coagulopathy, and multi-organ failure. She succumbed within 12 hours of admission. The knowledge about such fatal co-infections should be disseminated to medical practitioners encountering Leptospirosis infection and general public.

## INTRODUCTION

Leptospirosis is one of the leading zoonotic cause of morbidity as well as mortality across the world. Dual infections in Leptospirosis have been observed worldwide. To our knowledge, *Escherichia coli* was one of the commonest pathogens isolated in women with puerperal sepsis. To date with, there is no reported case of *Escherichia coli* and Leptospirosis co-infection among the puerperal populations, which spells dismal prognosis as illustrated in this case.

## CASE REPORT

A 32-year-old woman, who was day 23 post-partum, presented to a general practitioner with the chief complaint of severe headache preceded by two days history of fever. During the consultation, she developed generalized tonic-clonic seizure at 1120 Hrs, following which she was immediately transferred to our hospital.

She arrived at our facility at 1215 Hrs with GCS E1V1M1. Her pupils were 1 mm bilaterally and both reactive to light. Her temperature 41.6°C, blood pressure was 58/26mmHg and pulse rate was 100/min. Oxygen saturation 100% on high flow oxygen. She was intubated immediately for airway protection. Clinical examinations revealed neck stiffness but no hyperreflexia or hypertonia. Babinski signs were equivocal bilaterally and there was no clonus. Bleeding was noted from oral cavity and venipuncture sites. Gynecological examination and pelvic ultrasound scan were both normal. Other systemic examinations were unremarkable. Blood sugar level was normal. Bedside cardiac scan showed collapsed inferior vena cava.

A provisional diagnosis of meningoencephalitis with dual septic and hypovolemic shocks was made.

She remained hypotensive and oliguric despite receiving 3litres of normal saline. Noradrenaline was started at 0.4mcg/kg/min. Her blood pressure subsequently stabilized prior to the transfer to Intensive Care Unit. She received 2grams of intravenous ceftriaxone at 1330H after the blood culture was taken.

She arrived at ICU at 1425 H. Her pupils size were 2mm bilaterally with sluggish response to light stimulation and blood pressure was 110/60mmHg with a pulse rate of 110/minute. She remained hypovolemic as inferior vena cava diameter measured was 1.09cm with 50% collapsibility. Fluid resuscitations continued with another two pints gelafluidin infusions. She continued to bleed from oral cavity and venipuncture sites. Packed cells transfusions were also commenced subsequently. Her repeated blood parameters were consistent with consumptive coagulopathy with increased Activated Partial Thromboplastin Time, increased Prothrombin Time, unreadable International Normalized Ratio and thrombocytopenia.

Effort was made to control her coagulopathy. She received a total 4 units of packed cells, 18 units of cryoprecipitate, 11 units of platelet concentrates and 10 units of fresh frozen plasmas. Intravenous Vitamin K and intravenous tranexamic acid were also administered. Despite this, she continued to bleed profusely. At 1700Hrs, she developed pulmonary hemorrhage. Chest X ray was repeated at 2029Hrs showed diffuse opacities extending up to mid zones consistent with pulmonary hemorrhage. Despite intensive treatment, patient remained in decompensated shock with concurrent noradrenaline, dopamine and dobutamine infusion. She succumbed at 2329Hrs.

Post-mortem examination revealed gross cerebral edema with tonsillar herniation and Duret hemorrhage at the midbrain. The presence of red blood cells with transudate within alveolar space in the lungs tissue HPE ascertained the pulmonary hemorrhage. Additionally, mixture of micro-fibrin thrombi with inflammatory cells within the blood vessel at the epicardial fat in the heart tissue HPE confirmed the existence of disseminated intravascular coagulopathy. Dual infections with *Escherichia coli* and *Leptospira* serovar Sarawak were confirmed with blood culture and serum Leptospirosis Microscopic Agglutination Test respectively.

This article was accepted: 21 May 2018

Corresponding Author: Thai Lun Tan

Email: tanthailun@gmail.com

Summary of Investigations

Hour(s) From Presentation To Our Facility	At Presentation	2 Hours	4 Hours	5 Hours	11 Hours
<b>Full Blood Count</b>					
White Cell Count	7.1 x 10 <sup>3</sup> u/L	Sample clotted	10 x 10 <sup>3</sup> u/L		5.6 x 10 <sup>3</sup> u/L
Haemoglobin	12.9 g/dL		12.4 g/dL		9.2 g/dL
Platelet	217 x 10 <sup>3</sup> u/L		46 x 10 <sup>3</sup> u/L		73 x 10 <sup>3</sup> u/L
<b>Renal Profile</b>					
Urea	4.1 mmol/L	4.6 mmol/L	Sample lysed	4.9 mmol/L	
Creatinine	152 umol/L	175 umol/L		226 umol/L	
Sodium	138 mmol/L	141 mmol/L		150 mmol/L	
Potassium	4.5 mmol/L	4.6 mmol/L		2.4 mmol/L	
<b>Coagulation Profile</b>					
PT	15 s	Sample clotted	>120 s	>120 s	50.1 s
INR	1.18		NA	NA	5.44
APTT	33 s		>180 s	>180 s	155 s
<b>Liver Function Test</b>					
AST	108 U/L	209 U/L	Sample lysed	516 U/L	
ALT	81 U/L	78 U/L		234 U/L	
Total Bil	13.2 umol/L	5.6 umol/L		9.8 umol/L	
LDH				2480 U/L	
CK	724 U/L				
<b>Arterial Blood Gases</b>					
pH	7.37	7.28	7.353	7.072	6.97
pCO2	22 mmHg	26.4 mmHg	31.6 mmHg	74.7 mmHg	95.9 mmHg
pO2	277mmHg	534 mmHg	193 mmHg	91.3 mmHg	68.7 mmHg
HCO3	13 mmol/L	14.5 mmol/L	18.9 mmol/L	15.9 mmol/L	14.9 mmol/L
Base excess	-11mmol/L	-13.4 mmol/L	-7.4 mmol/L	-8.0 mmol/L	-9.5 mmol/L
<b>Microbial Culture Results</b>					
Blood Culture	Escherichia coli				
Urine Culture	No growth				
High Vaginal Swab Culture	No growth				
Dengue NS-1 Antigen	Negative				
Leptospirosis Ig M Antibody	Positive				
Leptospirosis Microscopic Agglutination Test	1: 400				
Cerebrospinal Fluid Analysis	Leptospira serovar Sarawak				
Cerebrospinal Fluid Culture	Pleocytosis with predominant lymphocyte count				
Cerebrospinal fluid PCR for Leptospirosis	No growth				
	Negative				

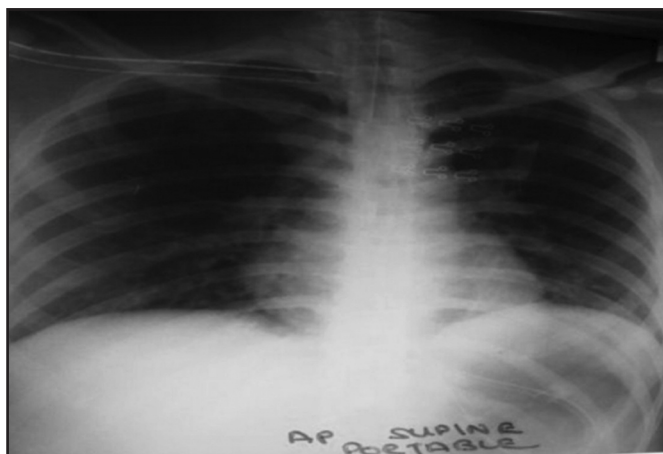


Fig. 1: Chest X-ray film at arrival to our facility which shows normal lung fields at 1327 H.

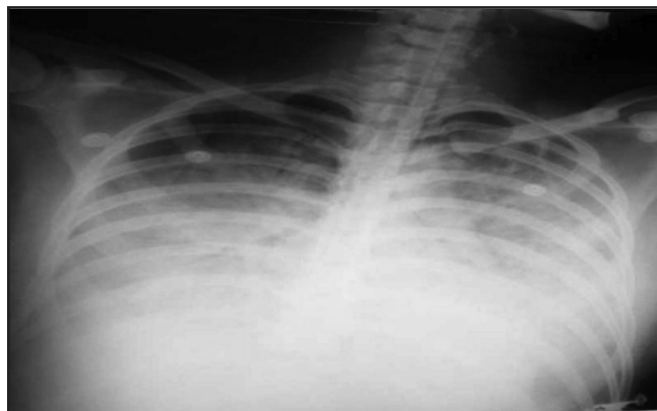


Fig. 2: Chest X-ray film repeated at 2029H shows diffused opacity in bilateral lung fields extending up to mid zones consistent with pulmonary haemorrhage.

## DISCUSSION

Human Leptospirosis is increasing, causing great morbidity and mortality.<sup>1</sup> Fatal dual infections have been reported in Leptospirosis infection.<sup>2-4</sup> Puerperal populations from Leptospirosis endemic regions are vulnerable to dual infections because they have an increased risk of *Escherichia coli* sepsis.<sup>5</sup>

Leptorapide test kit that offers rapid result was used to detect *Leptospira* specific antibody in our case. (sensitivity 88%; specificity 93%) Microscopic agglutination test was performed to affirm the positive result. (sensitivity 92%; specificity 98%)

The presentation in this case was very acute with predominant nervous system involvement manifested as generalized tonic-clonic seizure with hyperpyrexia followed by deep unconsciousness. Autopsy results showed generalized edema with tonsillar herniation complicated with Duret haemorrhage at the midbrain. There was no structural abnormality or obvious inflammation detected in the genitourinary system. We propose that concurrent Leptospirosis infection had unmasked the sub-clinical *Escherichia coli* infection that rapidly evolved into *Escherichia coli* sepsis with irreversible lethal complications.

This index case underscores the importance of considering the probability of co-infections in patients from tropical countries presented with similar rapid deterioration. In our case,

*Leptospira serovar Sarawak* that was isolated was believed to be due to either direct contact with rodents or through indirect contact with water contaminated with urine from an infected rodent. Hence, effective measures should be taken to curb Leptospirosis infection by avoiding contact.

## ACKNOWLEDGEMENT

We would like to thank Director General of Health Malaysia for his permission to publish this article. We would also like to express our appreciation to Dr Siti Zanariah for her contribution in the post-mortem discussion and Puan Nor Diyana for sharing information regarding acute Leptospirosis infection diagnostic methods.

## REFERENCES

1. Costa F, Hagan JE, Calcagno J, Kane M, Torgerson P, Martinez-Silveira MS, et al. Global Morbidity and Mortality of Leptospirosis: A Systematic Review. *PLoS Negl Trop Dis* 2015 ;9(9): e0003898.
2. Pérez Rodríguez NM, Galloway R, Blau DM, Traxler R, Bhatnagar J, Zaki SR, et al. Case series of fatal *Leptospira* spp./dengue Virus co-infections- Puerto Rico, 2010-2012. *Am J Trop Med Hyg* 2014; 91(4): 760-5.
3. Wijesinghe A, Gnanapragash N, Ranasinghe G, Ragunathan MK. Fatal Co-infection with Leptospirosis and Dengue in a Sri Lankan male. *BMC Res Notes* 2015; 8: 348.
4. Hin HS, Ramalingam R, Chunn KY, Ahmad N, Ab Rahman J, Mohamed MS. Fatal co-infection-melioidosis and Leptospirosis. *Am J Trop Med Hyg* 2012; 87(4): 737-40.
5. Bacterial sepsis following pregnancy. Royal College of Obstetricians and Gynaecologists. Green-top Guideline No. 64b. April 2012.