

# A colonic amoebic abscess mimicking colonic carcinoma

Tan Li Peng, MRCP<sup>1</sup>, Kan Foong Kee, MRCP<sup>2</sup>, Yvonne Ai Lian Lim, PhD<sup>3</sup>

<sup>1</sup>Department of Medicine, Hospital Pakar Sultanah Fatimah, Muar, Johor, <sup>2</sup>Department of Medicine, Hospital Sultanah Aminah, Johor Bahru, Johor, <sup>3</sup>Department of Parasitology, Faculty of Medicine, University of Malaya, Kuala Lumpur

### SUMMARY

Amebiasis is one of the major causes of diarrhea in the developing countries and it can present with a wide range of gastrointestinal symptoms depending on the phase of infection. We described a case of 50 year-old male patient who presented with abdominal pain, diarrhea and vomiting. After right hemicolectomy for appendicular abscess with tumour over the ileum, histopathological examinations revealed numerous trophozoites of *Entamoeba histolytica* in a background of inflammations (Figure 1). Following resection of the ameboma, he received intravenous metronidazole treatment for total of two weeks duration.

### INTRODUCTION

Amebiasis is an infection caused by a pathological intestinal protozoan parasite, *Entamoeba histolytica* which occurs in about 10% of the world's population. It is commonly seen in developing or tropical countries. Intestinal amebiasis has wide clinical presentation ranging from asymptomatic to dysentery and even extra-intestinal disease, such as brain or liver abscesses.<sup>1</sup>

*E. histolytica* is transmitted via ingestion of the environmentally hardy cysts found in faecally contaminated water, fertilizer, soil or the contaminated hands of food handlers.<sup>3</sup> Occasionally, faecal-oral transmission can also occur in the setting of anal sexual practices. The cysts can remain viable in the environment for weeks to months. Following ingestion of the cysts, they excyst in the colon, resulting in formation of trophozoites which can penetrate and invade the colonic mucosal barrier, leading to tissue destruction, secretory bloody diarrhea and colitis.

Patients with amebic colitis often present with abdominal pain, bloody diarrhea and weight loss. However, they can also present with chronic diarrhea without weight loss, which is usually neglected by elderly patients. Patients with advanced age and those who are immunocompromised tend to suffer a more severe clinical course or present with complications like toxic megacolon.<sup>1</sup>

Persistent *E. histolytica* colonic infection may cause the formation of mass-like granuloma (ameboma). Generally, ameboma present as a segmental, concentric mucosal lesion in the gastrointestinal tract causing lumen narrowing and then leads to obstructive symptoms.<sup>1</sup> Ameboma is a rare presentation of invasive amebiasis and it is estimated to occur in about 1.5% of cases. It is often misdiagnosed to be other surgically related intestinal disease such as carcinoma,

diverticulitis and Crohn's disease because ameboma can mimic colorectal carcinoma especially in the elderly.<sup>2</sup>

### CASE REPORT

A 50 year-old, previously healthy male teacher presented with acute, dull aching, lower abdominal pain over the right iliac fossa for two days. There was associated fever with chills and rigor. He experienced vomiting of two days duration, which was three episodes per day and mainly consisted of clear fluids with food particles. He also experienced a few episodes of diarrhea prior to admission. He denied loss of weight or bleeding per rectum and there was no family history of colorectal cancer. There was also no history of travelling.

On admission, he was febrile, lethargic and in pain. He had tachycardia with normal blood pressure. Physical examination revealed a tense, guarded abdomen with rebound tenderness over the right iliac fossa.

Laboratory data showed leukocytosis with normal renal and liver functions. His serum carcinoembryonic antigen (CEA) level was normal at 0.2ng/ml. The serology (ELISA IgG) testing for amebiasis was negative, but the serology was sent only after the histopathological examination. Stool for ova and cysts were negative. The blood culture showed no growth. He underwent emergency operation on admission with suspicion of a perforated appendix. However, the operation was extended intra-operatively to a laparotomy with right hemicolectomy with primary end to end anastomosis for appendicular abscess and a suspected tumour over the ileum. There were pus and multiple enlarged lymph nodes found around the ileocolic junction intra-operatively.

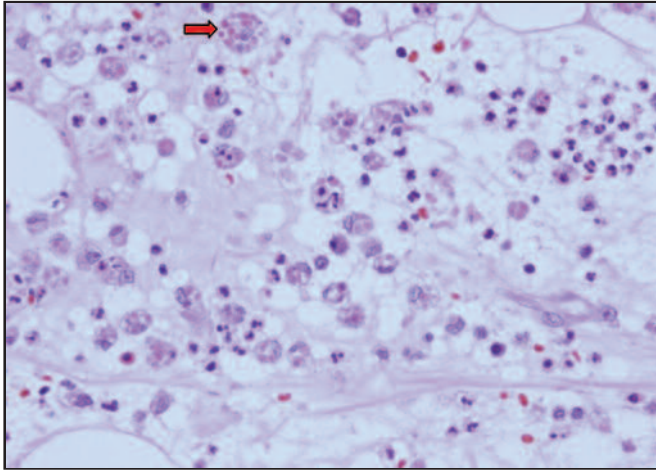
Histopathological examination of the resected bowel revealed acute inflammatory exudates and transmural neutrophilic infiltrates within the terminal ileum and appendix. There were collections of pus cells with numerous trophozoites resembling the macrophages ingesting red blood cells; the features which were consistent with amoebic abscess (Figure 2).

Following resection of the ameboma, he received intravenous cefoperazone for a week and metronidazole for total of 2 weeks duration. Subsequently, he made an uneventful post-operative recovery. To date, he has remained well and asymptomatic for 6 months following the surgery and the antibiotic therapy. This patient didn't receive any intraluminal agents due to unavailability of the medications.

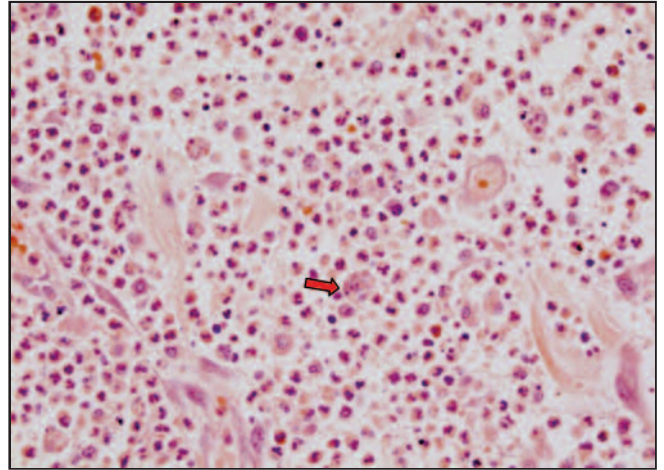
This article was accepted: 2 August 2018

Corresponding Author: Li Peng Tan

Email: j-lyn@rocketmail.com



**Fig. 1:** Suppurative inflammation with numerous trophozoites resembling macrophages ingesting red blood cells (H&E x 400).



**Fig. 2:** Acute suppurative exudates with scattered trophozoites resembling macrophages ingesting red blood cells (H&E x400).

## DISCUSSION

Cases of ameboma mimicking intra-abdominal tumor or carcinoma of colon had been reported before in countries like Japan, Taiwan and India. In previously reported cases, the patients either presented with chronic diarrhea, abdominal pain, abdominal mass or even with complications like perforative peritonitis. Some managed to have colonoscopy and biopsy done to diagnosed ameboma and hence appropriate treatment was initiated.<sup>1,2,3,4</sup>

Herein, we described a gentleman with amoebic abscess of appendix and ileocaecal junction. The diagnosis of amebiasis in this case was challenging due to the presentation of an acute abdomen instead of chronic diarrhea. Furthermore, patient also didn't have other risk factors for amebiasis such as poor sanitations or immunocompromised state. Nevertheless, it should be considered as one of the differential diagnosis in an amebiasis endemic region.

Ameboma is usually solitary and its size can be as large as 15cm in diameter. It is more common among male and those aged between 20 to 60 years. In terms of location, ameboma develops most commonly in the caecum, followed by in the appendix then in the rectosigmoid region. Hepatic flexure, transverse colon and the splenic flexure have also been reported as sites of development.<sup>3</sup>

The diagnosis of amebiasis is made by demonstrating the presence of cysts or occasionally trophozoites in stool, by immunologic techniques or detection of the nucleic acid of the protozoan by PCR. Unfortunately, there are no pathognomic radiographic or endoscopic features which can suggest of a possible invasive ameboma formation. Therefore, strong clinical suspicion coupled with appropriate serology and tissue histopathologic confirmation is the key to diagnosis.<sup>4</sup>

There is no established standard treatment strategy for amebic intra-abdominal tumour till date. The management can be combination of both surgical resections with a course of metronidazole. Following therapy for invasive amebiasis, treatment with luminal agent to eliminate intraluminal cysts

is warranted, even if stool microscopy is negative. Intraluminal infection can be treated with one of the following regimens: paromomycin (25 to 30 mg/kg per day orally in three divided doses for 7 days), diiodohydroxyquin (650 mg orally TDS for 20 days) or diloxanide furoate (500 mg orally TDS for 10 days).<sup>5</sup>

## CONCLUSION

It is difficult to differentiate ameboma with colonic carcinoma from the equivocal clinical symptoms. Hence, this case was discussed in an attempt to highlight the possibility of an ameboma mimicking colonic carcinoma, particularly in an endemic region. Ameboma should be considered as one of the differential diagnoses of masses located in the right colon (caecum and ascending colon), whereby the diagnosis requires an early colonoscopy, histopathologic studies and blood/stool tests to check for the presence of intestinal amebiasis. These measures will ensure early diagnosis and subsequently to an appropriate treatment.

## ACKNOWLEDGEMENT

The authors would like to thank the Director General of Health Malaysia for his permission to publish this article. We would also like to express our deepest gratitude to Dr Noorafidah Md Din, Pathologist of Hospital Pakar Sultanah Fatimah Muar for the HPE images.

## REFERENCES

1. Wang SY, Shih SCh, Wang TE, Chang WH, Wang HY, Lin SC. Ameboma mimicking submucosal tumor of the colon in an elderly. *Int J Gerontology* 2011; 5: 126-28.
2. Ramachandran BS, Thomas B, Baby S, Thomas R. Multicentric ameboma of the colon mimicking Crohn's disease. *J Dig Endosc* 2015; 6: 76-8.
3. Simşek H, Elsürer R, Sökmensüer C, Balaban HY, Tatar G. Ameboma mimicking carcinoma of the caecum: case report. *Gastrointest Endosc* 2004; 59(3): 453-4.
4. Hardin RE, Ferzli GS, Zenilman ME, Gadangi PK, Bowne WB. Invasive amebiasis and ameboma formation presenting as a rectal mass. *World J Gastroenterol* 2007; 13(42): 5659-61.
5. Karin Leder. Extraintestinal *Entamoeba histolytica* Amebiasis. UpToDate. Waltham, MA: UpToDate Inc