

# Ancient schwannoma of cervical sympathetic chain masquerading as carotid body tumour

Chee Chean Lim, MBBS<sup>1</sup>, Hon Syn Chong, MD<sup>1</sup>, Doh Jeing Yong, MD<sup>1</sup>, Seong Kin Foong, MD<sup>1</sup>, Prepageran Narayanan, FRCS<sup>2</sup>

<sup>1</sup>Queen Elizabeth Hospital, Kota Kinabalu, Sabah, Malaysia, <sup>2</sup>University of Malaya, Kuala Lumpur, Malaysia

### SUMMARY

**Schwannoma of cervical sympathetic chain is a rare cause of neck swelling. We report a 73-year-old male presented with anterior neck triangle swelling mimicking a carotid body tumour. Surgical excision was done, and the histopathological examination reported as ancient schwannoma. We would like to discuss the important differential diagnoses and highlight the possibility of an ancient schwannoma of cervical sympathetic chain masquerading as carotid body tumour. Also, to emphasise the importance of imaging for pre-operative planning and counselling.**

### INTRODUCTION

Schwannomas are slow growing benign tumour arising from nerve sheaths. Incidences of it occurring in the head and neck region were estimated to be 25% to 40%. Head and neck schwannomas are classified based on the nerve of origin into two groups, either cochleovestibular or non-vestibular. Majority of these schwannomas are of non-vestibular origin. Parapharyngeal space was the most common non-vestibular head and neck location with vagus nerve schwannoma being the majority of cases followed by cervical sympathetic chain schwannoma (CSCS).<sup>1</sup> Herein, we report an unusual cause of neck swelling arising from cervical sympathetic chain (CSC) mimicking as carotid body tumour (CBT).

### CASE REPORT

A 73-year-old man who had no past medical history presented with history of left progressive neck swelling for two years associated with dysphonia and dysphagia. Physical examination revealed a left submandibular swelling measuring 7x6cm in size. It was firm, smooth, regular in margins, pulsatile and non-tender. There was presence of transmitted pulsation but no bruit or cranial nerve palsies noted. Oropharyngeal examination showed that the left lateral pharyngeal wall being pushed medially.

Computed tomography scan of the neck described a left neck mass (5.2x3.9x5.8cm) with multiple feeding vessels from internal carotid artery (ICA) and external carotid artery (ECA). It crossed midline to the right filling the oropharynx with the narrowest portion of lumen measuring 0.9cm.

The patient underwent surgical excision with a transcervical approach. Intra-operatively, the mass was found lying

medial to common carotid artery (CCA), ICA and ECA; displacing them anteriorly with splaying of both ICA and ECA. Ptosis and enophthalmos were observed in the left eye after surgical excision. The patient was discharged well with oral corticosteroid for one week and subsequent follow up showed persistence of a well-tolerated partial Horner's syndrome.

Finally, histopathologic examination confirmed it to be ancient schwannoma showing extensive degenerative changes including cyst formation with hyperchromatic cells diffusely positive for S100 protein. Some cells showed degenerative atypia, but no mitotic figures were seen.

### DISCUSSION

Five variants of schwannoma have been described; common, cellular, plexiform, epithelioid and ancient type. Ackerman and Taylor first proposed the terminology "ancient" schwannoma to indicate the protracted period and degenerative changes associated with the appearance of these lesions.<sup>2</sup> It is a rare entity displaying hyperchromatic areas and nuclear atypia with variable presence of myxoid, fibrillary background and cystic degenerative changes.<sup>2</sup> Ancient schwannomas occur in a wide age range between 20-50 years with predominance in female.<sup>3</sup> Up to 20% of cases are associated with neurofibromatosis type I. Majority of ancient schwannoma occur in deep seated locations such as the retroperitoneum and posterior mediastinum, whereas only few are seen in head and neck and the extremities.

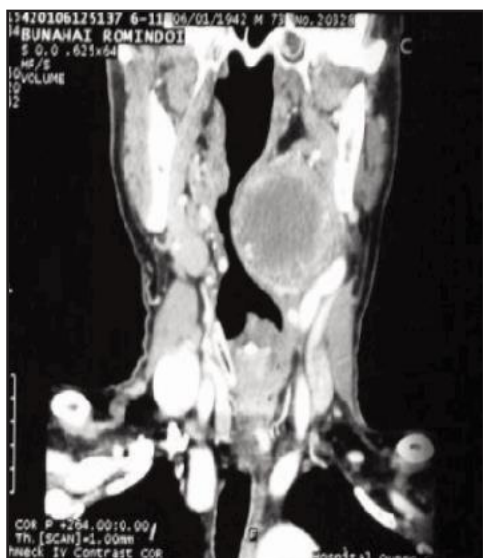This pathology can often times lead to misdiagnosis of malignancy and cause confusion with many other cystic masses of the neck from the aspirates taken. Carotid body tumour, paraganglioma, tubercular lymphadenopathy, branchial cleft cyst, lymphangioma or soft tissue sarcoma are common differential diagnosis in this area of the neck. It is also imperative to recognise that ancient schwannoma can histologically mimic malignant peripheral nerve sheath tumours (MPNST) because of their occasional appearance of hyperchromatic cells and cytological atypia.<sup>4</sup> However, ancient schwannomas have a long clinical course and react strongly with S100 protein with immunochemistry being able to differentiate it from MPNST.<sup>4</sup> This is important as a false positive diagnosis of malignancy may lead to over treatment being carried out unnecessarily.

---

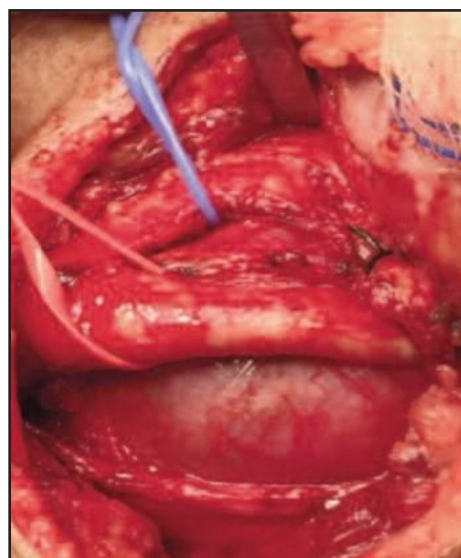
*This article was accepted: 24 September 2017*

*Corresponding Author: Chee Chean Lim*

*Email: limbie89@gmail.com*



**Fig. 1:** Well defined oval mass seen in left submandibular region with vessels encircling it.



**Fig. 2:** Schwannoma causing anterolateral displacement and splaying of ICA and ECA.

Majority of patients are asymptomatic at presentation and presence of Horner's syndrome before resection is rare as schwannoma by nature seldom impair nerve function and CSC runs in a relatively loose fascial compartment. Fine needle aspiration cytology is often unhelpful and offers little pre-surgical advantage as shown in our case. Hence, imaging characteristics obtained with computed tomography with contrast and magnetic resonance imaging are essential in the differential diagnosis process.

Carotid body tumours (CBT) typically splay the ICA and ECA producing "lyre sign" with hypervascularity.<sup>5</sup> CSCS causes displacement of carotid artery and jugular vein together, often anteriorly or laterally as they grow behind the carotid sheath.<sup>5</sup> It was also reported to cause mild splaying of ICA and ECA. Therefore, lyre sign can be observed both in CBT and CSCS. In our case, as the neck swelling was transmitting pulsation coupled with the computed tomography scan (CT scan) appearance of hypervascularity and mild splaying between the ICA and ECA, CBT had to be ruled out. The separation between the jugular vein and the CCA or ICA was not observed which is characteristically seen in vagal nerve schwannoma as they grow between the two structures.<sup>5</sup>

Schwannomas appear hypodense in general in comparison to muscle on CT scan without contrast while showing some degree of enhancement at the periphery with contrast. Magnetic Resonance Imaging (MRI) will reveal low signal intensity on T1-weighted images and high signal intensity on T2-weighted images. Diffuse weighted imaging is also helpful to differentiate a schwannoma from CBT as schwannomas will have a delayed washout of contrast relative to CBT. MRI with contrast was found to be the most informative pre-operative radiologic approach with studies reporting 80-86% diagnostic accuracy. We would like to highlight here the importance of MRI contrast as the preferred diagnostic tool as it is not only able to identify schwannomas pre-surgically, also it provides information about the nerve of origin enabling adequate counselling of the patients before being subjected to surgical excision.

Surgical excision is the preferred treatment for these tumours. In most cases, extra-capsular resection is performed with resultant nerve sacrifice. An alternative approach, intra-capsular enucleation has been shown to result in less morbidity due to nerve preservation but is frequently difficult to do so due to the intimate relationship with CSC and dense attachment of the tumour. Our patient developed a well-tolerated partial Horner's syndrome post-resection which is the most common sequelae associated with extracapsular "peeling" of the tumour.

## CONCLUSION

Ancient schwannoma of cervical sympathetic chain is a very rare entity and can mimic as carotid body tumour. Fine-needle aspiration cytology is usually inconclusive and radiological imaging characteristics with contrasted computed tomography and MRI play an indispensable role in the diagnosis. Horner's syndrome related sequela is the commonest surgical adverse event encountered with most cases persisted at follow up.

## REFERENCES

1. Navaie M, Sharghi LH, Cho-Reyes S, Keefe MA, Howie BA, Setzen G. Diagnostic approach, treatment, and outcomes of cervical sympathetic chain schwannomas: a global narrative review. *Otolaryngol Head Neck Surg* 2014; 151: 899-908.
2. Ackerman LV, Taylor FH. Neurogenous tumours within the thorax; a clinicopathological evaluation of forty-eight cases. *Cancer* 1951; 4(4): 669-91.
3. White W, Shiu MH, Rosenblum MK, Erlandson RA, Woodruff JM. Cellular schwannoma. A clinicopathologic study of 57 patients and 58 tumors. *Cancer* 1990; 66(6): 1266-75.
4. Mikami Y, Hidaka T, Akisada T, Takemoto T, Irei I, Manabe T. Malignant peripheral nerve sheath tumor arising in benign ancient schwannoma: a case report with an immunohistochemical study. *Pathol Int*. 2000; 50(2): 156-61.
5. Anil G, Tan TY. Imaging characteristics of schwannoma of the cervical sympathetic chain: a review of 12 cases. *Am J Neuroradiol* 2010; 31: 1408-12.