

# A frequently missed entity in systemic lupus erythematosus (SLE): Intestinal pseudo-obstruction (IpsO)

Shirley Lee, MRCP<sup>1</sup>, Rachel Joshua Thundyil, MRCP<sup>2</sup>

<sup>1</sup>Department of Internal Medicine, Queen Elizabeth Hospital, Sabah, Malaysia, <sup>2</sup>Department of Rheumatology, Queen Elizabeth Hospital, Sabah, Malaysia

### SUMMARY

**Intestinal pseudo-obstruction (IpsO) is defined as presence of clinical features of intestinal obstruction without identifiable mechanical obstructive lesion. IpsO is an uncommon gastrointestinal manifestation of systemic lupus erythematosus (SLE) and is largely under-recognised. There are only over 30 published cases in English literature on SLE-related IpsO. Herein, we report two cases of SLE-related IpsO to illustrate the importance of early recognition to avoid unnecessary surgical intervention, as SLE-related IpsO responds well to systemic high dose corticosteroids. These two cases also demonstrate the apparent association of IpsO with uretero-hydronephrosis, suggesting that the possible mechanism could be smooth muscle dysmotility.**

### INTRODUCTION

Gastrointestinal (GI) symptoms are common, but often overlooked in systemic lupus erythematosus (SLE), as more emphasis is usually given to concurrent involvement of other major organs which are better established.<sup>1</sup> Intestinal pseudo-obstruction (IpsO) is a rare GI manifestation of SLE. It may occur as a complication or as the initial presentation of SLE with minimal cutaneous involvement.<sup>2</sup> Essentially, IpsO is a disorder of intestinal hypomotility, causing clinical features similar to intestinal obstruction without identifiable mechanical obstructive lesion.<sup>3</sup> Here, we present two cases to demonstrate that the timely recognition of IpsO in SLE reduces morbidity.

### CASE REPORT 1

A 38-year-old lady with underlying lupus nephritis since 1996, presented repeatedly to the district hospital from July to December 2013 for recurrent abdominal pain, vomiting, diarrhoea and significant weight loss. Prior to this presentation, the lupus nephritis was in remission and did not require any immunosuppressants. In the district hospital, she was repeatedly treated as gastroenteritis with electrolyte imbalance. Upper and lower endoscopy as well as the thyroid function were normal.

In December 2013, with the worsening renal function and active urine sediments, she was referred to the nephrology unit for active lupus nephritis. Her ultrasound abdomen showed bilateral tortuous dilated uretero-hydronephrosis with ascites. Computer topography (CT) urogram showed similar findings and cystoscopy demonstrated neurogenic

bladder with vesicoureteric reflux. The renal function gradually improved with hydration but the abdominal pain and vomiting worsened. Abdominal X-ray and CT abdomen showed dilated loops of small bowels, suggestive of intestinal obstruction. The serum potassium level was 4.2mmol/L at that time. She underwent exploratory laparotomy, which found no demonstrable mechanical obstruction. The peritoneal fluid culture taken intra-operatively was negative. Post-operatively, the patient was referred to the rheumatology team for thrombocytopenia. In view of evidence of bicytopenia, low complement levels, cystitis and a 24-hours urine protein of 0.75g/day, a diagnosis of SLE flare with chronic IpsO was made. The patient was planned for methylprednisolone but was withheld due to bouts of bacteremia secondary to line related sepsis. She was given intravenous immunoglobulin and total parenteral nutrition. The gastrointestinal symptoms gradually improved with 1mg/kg/day of oral prednisolone. She was later maintained with mycophenolic acid for the ongoing active lupus nephritis.

### CASE REPORT 2

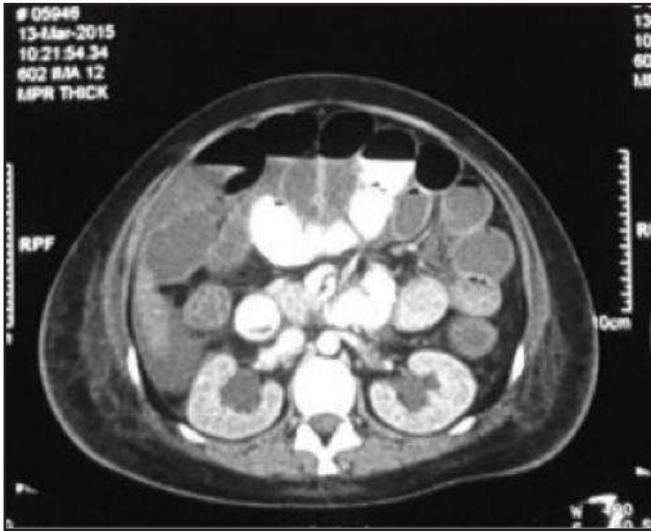
A 23-year-old lady diagnosed with SLE in 2012, presented to district hospital with an acute flare of SLE evidenced by facial rash, alopecia, oral ulcers and arthralgia. During the admission, she had complained of abdominal distension, colicky pain and loose stool and was subsequently treated as gastroenteritis. Concurrently, the patient had acute urinary retention needing continuous bladder drainage.

She was referred to tertiary centre because of worsening abdominal symptoms. The abdominal X-ray showed dilated small bowels and the electrolytes initially were normal, with a serum potassium level of 4.3mmol/L. Ultrasound abdomen showed extensive bowel gas shadows with moderate to gross ascites, mild hydronephrosis and hydroureter bilaterally but no stones were seen. A diagnosis of IpsO with bilateral uretero-hydronephrosis secondary to SLE was made and she was started on intravenous hydrocortisone 100mg 8-hourly. In the ward, she was given two weeks of oral vancomycin after testing positive for *Clostridium difficile* (CD) antigen. She underwent sigmoidoscopy and was found to have erythematous, oedematous mucosa, and small areas of aphthous ulcerations, with no demonstrable pseudopolyps or pseudomembranes. Her sigmoidoscopic biopsy was consistent with autoimmune colitis.

*This article was accepted: 7 August 2017*

*Corresponding Author: Shirley Lee*

*Email: sle1984z@gmail.com*



**Fig. 1:** Axial view of CT abdomen of case 2 patient, showing air fluid levels at some of the small bowel loops and mildly dilated pelvicalyceal system.

after testing positive for *Clostridium difficile* (CD) antigen. She underwent sigmoidoscopy and was found to have erythematous, oedematous mucosa, and small areas of aphthous ulcerations, with no demonstrable pseudopolyps or pseudomembranes. Her sigmoidoscopic biopsy was consistent with autoimmune colitis.

During this period, she was treated with motility agents and total parenteral nutrition. Her CT abdomen was delayed as she developed acute kidney injury from the high Ryle's tube aspirate, which gradually improved with hydration. The CT abdomen reported a long segment of large bowel wall thickening suggestive of colitis and with no evidence of mechanical bowel obstruction and enhancing thickened urinary bladder wall causing bilateral obstructive uropathy. Based on the clinical and radiological findings, a diagnosis of SLE-related IpsO was established. The patient made a prompt recovery after intravenous methylprednisolone 500mg per day. Subsequently, she was discharged with 1mg/kg/day of oral prednisolone and later maintained with azathioprine.

## DISCUSSION

IpsO is an uncommon gastrointestinal manifestation of SLE and is largely under-recognised. There are 30 over published cases in English literature on SLE-related IpsO.<sup>1</sup> Common clinical features are abdominal distension, pain, nausea, vomiting, constipation and diarrhoea. In our case reports, we found that SLE-related IpsO can present both acutely as in case 2 and chronically as in case 1.

Frequently, the failure of early recognition of IpsO, as in case 1 will lead to unnecessary surgical intervention. SLE-related IpsO has documented good response to high dose systemic corticosteroids.<sup>1</sup> Hence, it is crucial for the clinician to be aware of such an entity, especially in SLE patients. There is also an increasing incidence of IpsO presenting as the initial presentation of SLE, noted in a review done on lupus patients in Asia.<sup>3</sup>

Huang et al in the Southern China lupus cohort observed an association between SLE-related IpsO and uretero-hydronephrosis in 25% of patients with IpsO<sup>4</sup> while the incidence was higher (67%) in another case series by Mok et al.<sup>1</sup> Interestingly, both our patients had uretero-hydronephrosis, suggesting that the possible mechanism behind IpsO could be smooth muscle dysmotility secondary to vasculitis or immune complex deposition.<sup>3</sup> The finding of autoimmune colitis in the sigmoidoscopic biopsy in case 2 further supports the fact that the underlying pathological process is immune complex deposition.

## REFERENCES

1. Mok M, Wong RW, Lau CS. Intestinal pseudo-obstruction in systemic lupus erythematosus: An uncommon but important clinical manifestation. *Lupus* 2000; 9(1): 11-8.
2. Zhang J, Fang M, Wang Y, Mao J, Sun X. Intestinal pseudo-obstruction syndrome in systemic lupus erythematosus. *Lupus* 2011; 20(12): 1324-8.
3. Chng H, Tan B, Teh C, Lian T. Major gastrointestinal manifestation in lupus patients in Asia: lupus enteritis, intestinal pseudo-obstruction, and protein losing gastroenteropathy. *Lupus* 2010; 19(12): 1404-13.
4. Huang Q, Lai W, Yuan C, Shen S, Cui D, Zhao J, et al. Predictors of intestinal pseudo-obstruction in systemic lupus erythematosus complicated by digestive manifestation: data from a Southern China lupus cohort. *Lupus* 2016; 25(3): 248-54.