

Siphoning diesel: a fatal mistake

Leong Wei Cheng, MRCP, Brian Cheong Mun Keong, FRCP

Department of Medicine, Hospital Teluk Intan

SUMMARY

Diesel is commonly used as fuel for engines and is distilled from petroleum. Diesel has toxic potential and can affect multiple organs. Exposure can occur after ingestion, inhalation or through the dermal route. The practice of siphoning diesel using a rubber tubing and the mouth is common in rural communities. This can lead to accidental ingestion and aspiration. Here we report a case of a patient who accidentally ingested diesel during siphoning, which caused extensive erosion of the oral cavity and oesophagus leading to pneumomediastinum and severe chemical lung injury. The patient responded well initially to steroids and supportive care but required prolonged hospitalisation. He developed complications of nosocomial infection and succumbed 23 days after admission.

KEY WORDS:

Diesel; siphon; chemical pneumonitis; oesophageal perforation; pneumomediastinum

INTRODUCTION

In rural communities, it is not uncommon for people to siphon diesel from vehicles or barrels using the mouth and a simple rubber tubing. This method of siphoning can lead to accidental ingestion and aspiration of diesel. Patients can present with nausea, vomiting and chemical burns in the oral cavity as well as cough, shortness of breath and acute respiratory distress due to chemical pneumonitis. We report a case with extensive erosion of the oral cavity and oesophagus leading to pneumomediastinum and severe chemical lung injury.

CASE REPORT

A 25-year-old man, with no previous medical illness presented with four days fever, sore throat and poor appetite. He also complained of cough and shortness of breath. He did not have any diarrhoea, vomiting, skin rash or headache. He was a smoker but did not consume alcohol or any illicit substance. He worked as a manual worker in the nearby oil palm estates.

Upon admission, he was alert with blood pressure of 161/85 mmHg, heart rate 101 beats per minute and afebrile. His respiratory rate was 20 breaths/min and oxygen saturation 96% under room air. On examination of his oral cavity, multiple ulcers and raw areas were noted over his buccal mucosa, tongue and oropharynx. These areas were covered with friable slough and bled easily. There was no palpable

cervical lymphadenopathy and auscultation of his lungs revealed normal findings. Examination of other systems did not reveal any abnormalities.

Initial blood investigations showed evidence of acute kidney injury (urea: 16.7 mmol/l, sodium 129 mmol/l, potassium 3.7 mmol/l and creatinine 937 μ mol/l). There was presence of protein and erythrocytes (2+) in his urine. His full blood count showed elevated white cell count of 11,600/ μ l (neutrophil 85%) with normal haemoglobin concentration (15.9 g/dl) and platelets (185,000/ μ l). Liver transaminases were normal. Chest radiograph showed clear lung fields. His provisional diagnosis was acute tonsillitis with post-infectious Rapidly Progressive Glomerulonephritis (RPGN). Intravenous (IV) Ceftriaxone 2 g daily was started.

He became progressively more tachypnoeic in the ward with worsening renal function and metabolic acidosis. He was referred to the Intensive Care Unit where he was put on non-invasive ventilation and haemodialysis was initiated. Repeated chest radiograph showed increasing opacities in both lower zones. He was empirically started on IV Methylprednisolone 1g daily for three days to treat for presumed RPGN.

The patient's Anti-Streptolysin O Titre (ASOT) subsequently came back negative. Upon careful questioning, the patient admitted that one week ago, while siphoning diesel from a barrel, he unintentionally swallowed and choked on some of the diesel. This occurred during work and was followed by a bout of vomiting.

He developed oral ulcers the following day and shortness of breath two days later. He did not disclose this history earlier as he thought that it was not relevant. The diagnosis was then revised to alleged diesel aspiration with chemical pneumonitis.

On day nine of admission, he was noted to have subcutaneous emphysema over his neck and upper chest wall. Computed tomography (CT) of the thorax revealed a wall defect at the left side of the oesophagus at the level of T5/T6 suggestive of oesophageal perforation, bilateral lower lobe consolidation suggestive of orthostatic or aspiration pneumonia, and evidence of subcutaneous emphysema with pneumomediastinum (Figure 1). He was treated conservatively and the subcutaneous emphysema resolved. He completed 10 days of IV Ceftriaxone and repeated blood cultures were negative. His renal function improved (urea: 25 mmol/l, creatinine: 264 μ mol/l) and he was weaned down to

This article was accepted: 27 May 2017

Corresponding Author: Brian Cheong Mun Keong

Email: keabcmk@hotmail.com

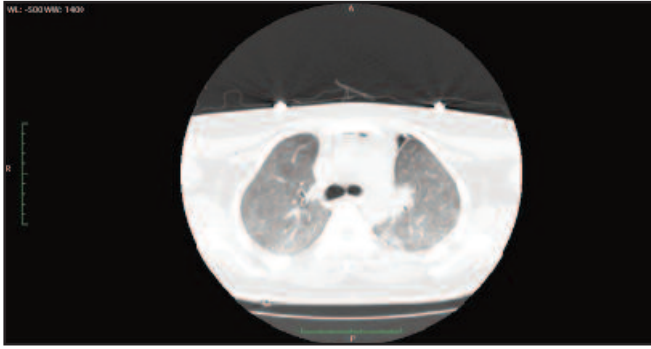


Fig. 1: Unenhanced CT thorax, lung setting:
Air pockets at anterior mediastinum in keeping with pneumomediastinum.

oxygen via a face mask. The patient remained in the ward as he was dependent on oxygen supplementation. His oxygen saturation on room air was less than 88%.

He deteriorated again on day 21 of admission when he became increasingly tachypnoeic with another episode of fever. His oxygen saturation dropped to 55% and he had to be mechanically ventilated. He was treated for hospital acquired pneumonia as his chest radiograph showed features of worsening consolidation over the mid and lower zones of both lungs. There was no radiological evidence of recurrence of pneumomediastinum. Intravenous Piperacillin/Tazobactam was commenced. Patient continued to deteriorate and succumbed to his illness two days later (after 23 days of admission). It is not known whether the patient's family sought or received compensation from Social Security Organization (SOCSO) later.

DISCUSSION

Diesel is commonly used as fuel for engines and is distilled from petroleum. Diesel has toxic potential and can affect multiple organs. Exposure can occur after ingestion, inhalation or through the dermal route. It can occur intentionally, for example ingestion during a suicide attempt or inhaling for recreational abuse. More commonly, exposure is accidental either as an occupational hazard through fumes and spillage or young children unintentionally ingesting it. As alluded to earlier, siphoning diesel can lead to accidental ingestion and aspiration. Diesel has a high potential for aspiration due to its low viscosity and high volatility.¹

Although local irritation to the oral cavity and oesophagus following ingestion has been described before, severe erosion leading to oesophageal perforation and pneumomediastinum as in our case is rare. Injuries of such nature are more common with corrosive agents. It can be complicated by mediastinitis. Mediastinitis carries a high mortality and can be diagnosed by CT scan, which typically show sternal separation, sub-sternal fluid collection or air-fluid-levels within the mediastinum.² These features were not present in our patient.

The clinical manifestations of chemical pneumonitis due to diesel aspiration are often non-specific and include breathlessness, cough, chest pain and haemoptysis.³ There is no specific investigation to detect the level of diesel exposure either in the blood or lungs. Diagnosis is usually suspected from the patient's history. However, bronchoscopy specimens usually reveal the presence of lipid laden macrophages.⁴ Some authors have used the term exogenous lipoid pneumonia to describe pneumonitis due to aspiration of mineral or vegetable oil. Bronchoscopy was not performed in our patient. Characteristic CT findings of hydrocarbon pneumonitis are air-space consolidations predominantly in the right middle lobe and areas of low attenuation within the consolidation.⁵

Most reported cases recovered after initial supportive measures. The use of steroids is thought to limit inflammation and fibrosis.⁴ Although its effectiveness has not been demonstrated in studies, it is commonly used with variable results in reported cases. As highlighted by our case, patients may respond initially to treatment with steroids and supportive care, but may require prolonged hospital stay due to difficulty weaning off oxygen. This exposes the patient to risk of hospital acquired infections.

CONCLUSION

The practice of siphoning diesel using the mouth is common in rural communities. This leads to accidental aspiration and ingestion of diesel. Management is supportive and patients may require prolonged hospitalisation. Education to create awareness regarding this type of accidental injury is important to prevent its occurrence.

ACKNOWLEDGEMENT

The authors would like to thank the Director-General of Health Malaysia for allowing this case report to be published and Dr Nur Ainaa Bt Othman, Radiologist, Hospital Teluk Intan for assisting us with the diagnostic imaging and reports.

REFERENCES

1. Ramnarine M, Santoriello M. Hydrocarbons toxicity. [updated 17 Aug 2015]. Available from: <http://emedicine.medscape.com/article/1010734-overview>.
2. Mueller DK, Dacey MJ. Mediastinitis. [updated 16 Dec 2015]. Available from: <http://emedicine.medscape.com/article/425308-overview>.
3. Kapoor D, Goel N, Manpreet Singh, Jasveer Singh. A rare case of fatal acute respiratory distress syndrome following diesel oil siphonage. *Indian J Anaes* 2013; 57(6): 625-7.
4. Venkatnarayan K, Madan K, Walia R, Kumar J, Jain D, Guleria R. Diesel siphoner's lung: Exogenous lipoid pneumonia following hydrocarbon aspiration. *Lung India* 2014; 31(1): 63-6.
5. Yi M S, Kim K I, Jeong Y J, Park H K, Lee M K. CT findings in hydrocarbon pneumonitis after diesel fuel siphonage. *Am J Roentgenol* 2009; 193(4): 1118-21.