

# Perforated gastric ulcer in severe dengue infection: A case report

Chiun Yann Ng, MRCP<sup>1</sup>, Soon Liang Lee, MRCP<sup>1</sup>, Siang Lin Foo, MS<sup>2</sup>

<sup>1</sup>Department of Internal Medicine, Hospital Pakar Sultanah Fatimah, Muar, Johor, <sup>2</sup>Department of Surgery, Hospital Pakar Sultanah Fatimah, Muar, Johor

### SUMMARY

Abdominal pain is one of the common presentations in severe dengue infection. We report a rare case of perforated gastric ulcer in a young man diagnosed with severe dengue infection and the challenges we faced in managing this patient. Perforated gastric ulcer need to be considered if there are signs of peritonitis and persistent abdominal pain that does not conform to the natural history of dengue. Proper imaging and early surgical intervention in perforated gastric ulcer is vital in preventing further complication and reducing the risk of mortality.

### KEY WORDS:

*Perforated gastric ulcer; severe dengue*

### INTRODUCTION

Dengue fever is a major public health problem with high morbidity and mortality in tropical and subtropical countries.<sup>1</sup> Dengue infection may result in a spectrum of illness ranging from undifferentiated mild febrile illness to severe disease, with or without plasma leakage and organ impairment.<sup>1</sup> Atypical manifestations of dengue are also on the rise as the incidence of dengue is increasing globally.<sup>2</sup>

We hereby report a very rare case of perforated gastric ulcer in a patient with severe dengue infection. It had only been reported once from our literature review.

### CASE REPORT

A 39-year-old man presented with fever, arthralgia and myalgia for five days. He had experienced two days history of abdominal pain and diarrhoea followed by two episodes of haematemesis on the day of admission. He had no history of taking nonsteroidal anti-inflammatory drugs and steroids. He does not consume alcoholic beverages or smoke cigarettes. Upon arrival, he was conscious but lethargic looking. His temperature was 38°C and blood pressure was 108/75mmHg. However, his pulse rate was 120 beats per minutes and was of low volume. His respiratory rate was 28 breaths per minute with oxygen saturation of 96% under high flow 15L oxygen. His lungs were clear on auscultation. His abdomen was distended, tender and guarded over the epigastrium. There was dullness over bilateral flank and the bowel sounds were sluggish.

The initial full blood count showed haemoglobin of 18.8g/dl with a haematocrit of 55.8%, thrombocytopenia ( $48 \times 10^9/L$ ), and a normal white cell count. ( $4.4 \times 10^9/L$ ). The dengue non-structural protein-1 antigen was positive. The arterial blood gas on high flow oxygen therapy showed severe metabolic acidosis with pH of 7.257, PaCO<sub>2</sub> of 22.5mmHg, PaO<sub>2</sub> of 275mmHg, HCO<sub>3</sub><sup>-</sup> of 13.5mmol/L and lactate level of 10.4mmol/L. His creatinine was 132umol/L and urea was 11.3mmol/L. There was mild derangement of liver enzymes with aspartate transaminase (AST) of 177u/ml and alanine transaminase (ALT) of 53u/ml. Serum amylase was 157 u/L. He had prolonged Activated Partial Thromboplastin Time (APTT) of 160 seconds. Chest and abdominal radiographs were unremarkable.

He was admitted to intensive care unit and required mechanical ventilation due to worsening respiratory distress. He was resuscitated with multiple crystalloid and colloid fluid boluses and intravenous dobutamine infusion was initiated in view of persistent hypotension. An ultrasonography of the abdomen was done and it revealed complex ascites and interloop free fluid on the right side of the abdomen. Contrast enhanced computed tomography (CECT) abdomen was performed on day five of admission when he was hemodynamically stable. The scan showed complex ascites at perihepatic, perisplenic, paracolic gutter, interloop and pelvis with extraluminal air suggestive of perforated viscus.

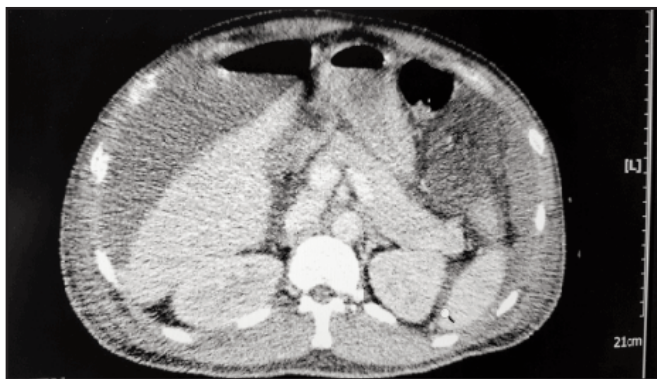A midline exploratory laparotomy was performed and perforated gastric ulcer was diagnosed intra-operatively. The perforated ulcer was repaired and three litres of turbid peritoneal collection was drained. Four units of platelets were transfused intra-operatively and the estimated blood loss was 175mls. Piperacillin/tazobactam was initiated for the intraabdominal sepsis. The peritoneal fluid grew pseudomonas aeruginosa and klebsiella pneumonia which were sensitive to piperacillin/tazobactam. There was no evidence of malignancy from the histopathological examination of the ulcer edge biopsies.

Follow-up abdominal ultrasonography 2-week post-operatively showed residual complex fluid collection over the right hypochondrium indenting onto the right lobe of the liver that required pigtail drainage. The pigtail was removed after two weeks and he was discharged well after one month of hospital admission. The repeat abdominal ultrasonography during his follow-up a month later showed complete resolution of the right hypochondriac collection.

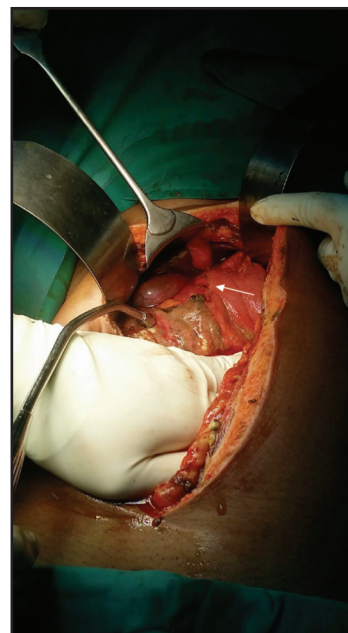
This article was accepted: 1 February 2017

Corresponding Author: Chiun Yann Ng

Email: yann731@yahoo.com



**Fig. 1:** A Contrasted Enhanced Computed Tomography of the abdomen showed extra-luminal air with ascites forming an air fluid level.



**Fig. 2:** A perforation seen at the pyloric area of the stomach as marked by white arrow.

## DISCUSSION

Abdominal pain has been regarded as one of the factors that is associated with severe dengue.<sup>1</sup> An epigastric tenderness in dengue may be perceived as a result of pancreatitis, acalculous cholecystitis or more commonly hepatitis.<sup>2</sup> In this case, the initial assessment of abdomen revealed localised tenderness and guarding at the epigastrium raising suspicion of pancreatitis, cholecystitis and hepatitis rather than gastrointestinal perforation which is rarely reported in dengue infection. However, the serum amylase was not markedly elevated to suggest pancreatitis so as the liver enzymes to consider fulminant hepatitis. Cholecystitis has been ruled out by a bedside ultrasonography. Hence, features that do not conform to the natural history of dengue such as persistent abdominal pain in reabsorption phase or presence of peritonism should alert the clinicians to the possibility of complications or concurrent illnesses such as perforated viscus.

Diagnosis of the perforated viscus in this case was delayed due to hemodynamic instability of the patient and the fact that the initial chest radiography was not able to detect any free gas under the diaphragm. In addition, the abdominal ultrasonography was not conclusive as there was no free intraperitoneal air seen. The intraabdominal free fluid detected was unable to be differentiated as the result of the perforated viscus or ascites secondary to plasma leakage in severe dengue. In view of high clinical suspicion of viscus perforation, contrast enhanced CT of the abdomen was performed. The presence of pneumoperitoneum on CT abdomen ascertained the clinical diagnosis of viscus perforation and hence surgical intervention was planned. CT abdomen is useful to assess gastrointestinal perforation in patients with non-diagnostic radiography and ultrasonography results as it allows detection of even small amounts of free air in the abdomen.<sup>3</sup>

The patient does not have risk factors of gastric ulcer. The exact mechanism of gastrointestinal perforation in dengue fever remains unclear as mentioned in a few previous cases reports.<sup>4,5</sup> More research is needed to identify the relationship of perforated viscus and dengue infection.

As illustrated in this case, management of perforated gastric ulcer in severe dengue was challenging. There was a delay in diagnosis and surgical intervention due to hemodynamic instability, severe thrombocytopenia and coagulopathy of the patient. Owing to the delay, he developed intraabdominal sepsis that resulted in a prolonged hospital stay. Hence, early surgical intervention is needed to aid in resolving the peritonitis, sepsis and increasing the patient's chance of survival.<sup>5</sup>

## CONCLUSION

Gastrointestinal manifestations are common in severe dengue infection. Perforated gastric ulcer needs to be considered if there are signs of peritonitis and persistent abdominal pain despite improvement of other clinical parameters. Early surgical intervention is important to prevent further complications and reducing the risk of mortality.

## REFERENCES

1. World Health Organization. Dengue guidelines for diagnosis, treatment, prevention and control. World Health Organization, Geneva 2009; p.3-14
2. Gulati S, Maheshwari A. Atypical manifestations of dengue. *Trop Med Int Health* 2007; 12(9): 1087-95.
3. Coppolino FF, Gatta G, Di Grezia G, Reginelli A, Iacobellis F, et al. Gastrointestinal perforation: ultrasonographic diagnosis. *Critical Ultrasound Journal* 2013; 5(Suppl 1): S4
4. Dengue presenting as gastric perforation: first case reported till date. Nisha M, Sharique A, Tanveer S, Sandesh D, Abhishek M, et al. *Int J Res Med Sci*; 2015; 3(8): 2139-2140
5. Alam SM, Bhuiya MMR, Islam A, Paul S. Perforated Gas Containing Hollow Viscus : A study in a Hospital, Bangladesh. *The ORION*. 2002. Available from: <http://www.orion-group.net/medicaljournal/pdf/84.pdf>