

Subcutaneous mycosis presenting as a non-healing left calf ulcer in an immunocompromised patient

Andy Tang Sing Ong, MRCP¹, Yong Kar Ying, MRCP¹, Jacqueline Wong Oy Leng, MPath², Chua Hock Hin, MRCP³, Chew Lee Ping, MRCP⁴

¹Department of Internal Medicine, Miri General Hospital, Sarawak, Malaysia, ²Department of Pathology, Sarawak General Hospital, Sarawak, Malaysia, ³Infectious Disease Unit, Department of Internal Medicine, Sarawak General Hospital, Sarawak, Malaysia, ⁴Haematology Unit, Department of Internal Medicine, Sarawak General Hospital, Sarawak, Malaysia

SUMMARY

This is a case report of subcutaneous mycosis presenting as a non-healing left calf ulcer in an immunocompromised patient. Traumatic inoculation of the causative agent is the most likely route of infection. The diagnosis requires a detailed history and high clinical suspicion, confirmed by histopathological examination. The management requires a multidisciplinary team approach involving surgeon, pathologist, physician sub-specialised in infectious disease, wound care nursing team as well as social support services. The literature review recommended that the treatment of choice for such infection is surgical debridement in addition to optimal antifungal therapy.

KEY WORDS:

Subcutaneous mycosis; non-healing ulcer; immunocompromised

INTRODUCTION

Subcutaneous mycosis is a chronic localised infection of the cutaneous and subcutaneous tissue following fungal inoculation during traumatic injury. Phaeohyphomycosis and chromoblastomycosis are examples of this causative agent. They are darkly pigmented (dematiaceous) or melanised fungi, which are widely distributed in the environment. This infection can occur in both immunocompetent and immunocompromised patients but more prone in the latter.¹ Here, we report a case of subcutaneous mycosis in an immunocompromised patient who presents to us with a non-healing left calf ulcer.

CASE REPORT

A 30-year-old gentleman who has immune thrombocytopenic purpura and chronic hepatitis C had splenectomy done in 2012 for refractory thrombocytopenia. He presented to us in October 2014 with a non-healing left calf ulcer. This occurred after he sustained a small puncture wound over his left calf following a trivial fall. No medical treatment had been sought until 10 months later when the calf ulcer was infected with pus discharge. He worked as a supervisor in an oil palm estate and was an ex-intravenous drug abuser. He had been on long term azathioprine treatment since December 2014. Prednisolone 100mg daily was given and tapered down over two months' period.

Our initial clinical impression was either malignancy or chronic infections such as tuberculosis or fungal infections. He was treated with antibiotics and wound debridement was performed, with intra-operative findings of 5x4 cm encapsulated left calf abscess. Following the operation, he was on regular outpatient wound dressing.

The histopathological examination (HPE) demonstrated subcutaneous mycosis in which phaeohyphomycosis and blastomycosis need to be considered. It was stained positive under Periodic acid-Schiff (PAS) (Figure 1) and Gomori's methenamine silver (GMS) stain (figure 2). There were no evidence of malignancy and tuberculosis. A second wound debridement was carried out three months later as the clinical improvement was unsatisfactory in which the HPE showed chronic active inflammation with fungal infestation. He was commenced on oral fluconazole 400 mg once daily following the second operation and his HPE persistently showed evidence of fungal infection. After two months of anti-fungal treatment, he underwent a wide excision of the infected left calf as apparently the wound was still dirty and not healing well. The HPE did reveal similar findings. Following three operations and six months of oral fluconazole, his wound was fully healed and he returned to work as usual.

DISCUSSION

There is no published statistical data about the prevalence and incidence of subcutaneous mycoses in Malaysia. The prevalence of subcutaneous mycoses in South Korea was reported to be 8 cases per 100,000 persons.² The same study also highlighted that this disease entity was most prevalent among those aged 60-69 and 80-89 years, when analysed by age group.² Chromoblastomycosis, one of the subtypes of subcutaneous mycoses, is relatively prevalent in Africa and Latin America. Infection rates of 1 per 24,000 and 1 per 32,500 persons respectively have been revealed by surveys.³

In general, there are three types of subcutaneous mycoses: chromoblastomycosis, mycetoma, and sporotrichosis. All appear to be caused by traumatic inoculation of the etiological fungi into the subcutaneous tissue. Chromoblastomycosis is a subcutaneous mycosis characterised by verrucoid lesions of the skin (usually of the

This article was accepted: 28 December 2016

Corresponding Author: Andy Tang Sing Ong

Email: atso1986@yahoo.com

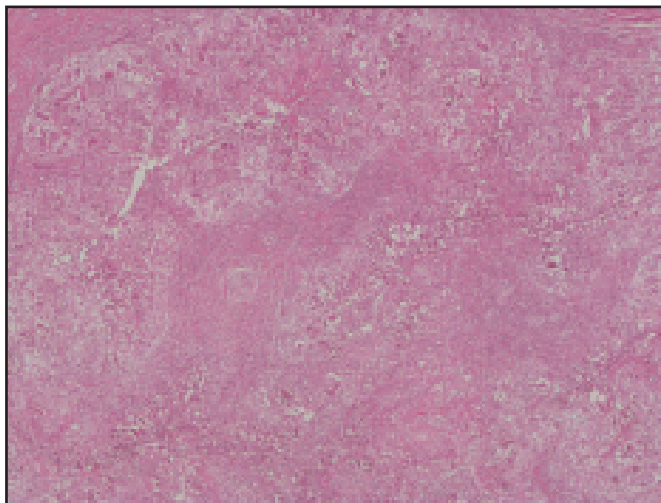


Fig. 1: Subcutaneous mycosis under Periodic acid-Schiff (PAS)stain.

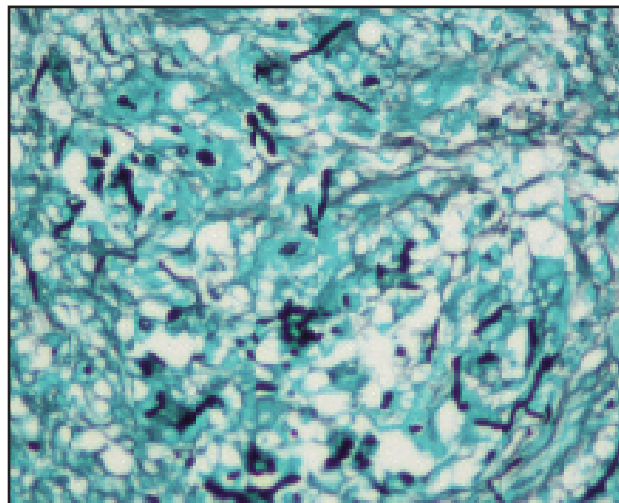


Fig. 2: Subcutaneous mycosis under Gomori's methenamine silver (GMS) stain.

lower extremities); HPE reveals muriform cells (with perpendicular septations), “copper pennies” are characteristic of this infection. Chromoblastomycosis is generally limited to the subcutaneous tissue with no involvement of bone, tendon, or muscle.⁴

Chromoblastomycosis and mycetoma are caused by only certain fungi. *Fonsecaea pedrosoi*, *Fonsecaea compacta*, *Cladosporium carionii*, and *Phialophora verrucosa* are the most common aetiology of chromoblastomycosis. The fungi causing mycetoma are usually pigmented brown to black. These organisms are known as dematiaceous (melanised) fungi. These fungi may cause a vast variety of infection, ranging from superficial to subcutaneous to deep (visceral) infection. Such deep infections due to dematiaceous fungi are termed phaeohyphomycosis.^{1,4}

Phaeohyphomycosis is caused by brown to black pigmented fungi of the cutaneous, superficial, and deep tissues. These infections are rare, life-threatening, and more prone to occur in immunocompromised patients.^{4,5}

Our case report shows that subcutaneous mycosis should be considered in immuno-compromised patients presented with a non-healing ulcer, particularly among those taking immunosuppressive therapy. The fungus likely gained entry when he sustained a puncture wound following a fall. Fungal culture and sensitivity is essential in differentiating the

subtypes of fungus species. A review of literature recommended that the treatment of choice for such infection is surgical debridement in addition to optimal antifungal therapy which includes itraconazole, voriconazole, posaconazole or caspofungin.¹ Our patient has responded to surgical debridement and anti-fungal therapy.

CONCLUSION

Subcutaneous mycosis is a rare clinical entity. This case raises awareness among clinicians to consider the possibility of subcutaneous mycosis in similar historical context, particularly among immunocompromised patients.

REFERENCES

1. Hospenthal DR. Uncommon Fungi and Prototheca. In Mandell GL, Bennett JE, Dolin R, editors. Mandell, Douglas, and Bennett's Principles and Practice of Infectious Diseases. Churchill Livingstone Elsevier 2010; 7th Ed: 3365-76.
2. Yoon HJ, Choi HY, Kim YK, Song YJ, Ki M. Prevalence of fungal infections using national health insurance data from 2009-2013, South Korea. Epidemiol Health 2014; 36: e2014017.
3. Director-General. Mycotic Diseases. World Health Organization Official Records 1975; 29
4. Thomas JW, Dennis MD. Medical Microbiology. The University of Texas Medical Branch at Galveston 1996; Fourth edition: Chapter 75 Spectrum of Mycoses.
5. Matsumoto T, Ajello L, Matsuda T, Szanislo PJ, Walsh TJ. Developments in phaeohyphomycosis and hyalohyphomycosis. J Med Vet Mycol 1994; 32 (suppl 1): 329-49.