

Idiopathic thrombocytopenic purpura in childhood, Langerhans cell histiocytosis in adulthood: More than a chance association?

Kuan Yueh Chien, MRCP¹, Nurain Mohd Noor, MMed (Int Med)²

¹Department of Medicine, Sarawak General Hospital, 93586 Kuching, Sarawak, Malaysia. ²Endocrine Unit, Department of Medicine, Putrajaya Hospital, Malaysia

SUMMARY

Described herein, a case of Langerhans cell histiocytosis (LCH) in an adult with Idiopathic Thrombocytopenic Purpura (ITP) diagnosed at age ten. She presented with cranial diabetes insipidus, later developed hypogonadotropic hypogonadism and multiple cervical lymphadenopathy from which histopathology of excisional biopsy confirmed LCH. Magnetic resonance imaging showed thickened pituitary stalk. Association of ITP and LCH is unknown but the question of LCH presenting as isolated thrombocytopenia in childhood only to be discovered in adulthood when there was pituitary and bone involvement remains. It reemphasizes the need for high index of suspicion and the challenges in diagnosing LCH at the outset.

KEY WORDS:

Langerhans cell histiocytosis, cranial diabetes insipidus, idiopathic thrombocytopenic, purpura, hypothalamic-pituitary axis

INTRODUCTION

Langerhans cell histiocytosis (LCH) is a rare disease, more so in adults, characterised by proliferation of large mononuclear cells.¹ Primary Immune Thrombocytopenia, previously known as Idiopathic Thrombocytopenic Purpura (ITP) is an autoimmune disorder characterised by isolated thrombocytopenia and remains a diagnosis of exclusion.² This case report describes the clinical features of a young adult female with LCH who was diagnosed to have chronic ITP in childhood.

CASE REPORT

A 23-year-old female presented with polyuria and polydipsia – drinking up to five litres a day for past one month. She has ITP diagnosed at age ten from trephine biopsy for which she has been taking oral prednisolone 5 mg every other day for at least a year with stable platelet counts above 100,000/ μ L.

Physical examination was unremarkable with normal visual field on confrontation and no neurological deficit. Blood pressure was 116/94 mmHg with no postural drop.

Water deprivation test was done which showed excessive plasma concentration 311 mOsmol/kg after five hours, with

inappropriately hypotonic urine at 186 mOsmol/kg and urine to plasma osmolality ratio of only 0.6 (< 1.9). After desmopressin, the patient was able to concentrate urine to 466 mOsmol/kg - more than 150% from the previous highest urine osmolality value. This confirmed cranial diabetes insipidus.

Initial assessment of anterior pituitary hormonal function was normal (Table I). Magnetic resonance imaging of the pituitary revealed thickened pituitary stalk measuring 4.6 mm in width with intense contrast enhancement and loss of the normal T1 hyperintensity of the posterior pituitary (Figure 1). The pituitary gland was otherwise not enlarged and the optic chiasm was normal. The working diagnosis then was lymphocytic hypophysitis and she was given oral desmopressin 0.1 mg twice daily.

Months later, patient complained of amenorrhea and anterior pituitary hormonal assay revealed hypogonadotropic hypogonadism (Table I). Following that, she developed multiple cervical lymphadenopathy and bony parietal swellings. Microscopic examination of an excised right cervical lymph node showed lymphoid tissue with partial effacement of the architecture by clusters and sheets of mononuclear cells positive for S-100 (Figure 2) and CD1a from immunohistochemical studies. This confirmed the diagnosis of LCH.

Computed tomography scan revealed multiple neck and pelvic lymphadenopathy (largest measuring 2.3 x 1.5 cm adjacent to left external iliac artery), as well as multiple lytic bone lesions in the scapula, vertebrae, pelvis and hip.

She completed six cycles of cytarabine monotherapy with zoledronic acid at six monthly intervals but continued to require hormonal replacement therapy and desmopressin.

DISCUSSION

Langerhans cell histiocytosis, historically called Histiocytosis X, is characterised by the aberrant proliferation of a specific dendritic cell from the monocyte-macrophage system known as Langerhans cell – named after its founder Paul Langerhans. Aetiology and underlying pathology of LCH is unknown. However, the demonstration of the cancer-

This article was accepted: 7 October 2016

Corresponding Author: Kuan Yueh Chien, Department of Medicine, Sarawak General Hospital, Jalan Hospital, 93586 Kuching, Sarawak

Email: kychien2006@yahoo.com

Table I: Serial anterior pituitary hormonal assays of the patient

	6/2/2014	23/6/2015	29/12/2014	26/1/2015
Free T4 (10-20 pmol/L)	10.7	13	14.3	11.7
TSH (0.5-6 mU/L)	2.323	0.976	1.98	1.697
FSH (follicular phase 3.1-7.9 mU/ml)	3.8	9.3	9.1	-
LH (follicular phase 1-18 mU/ml)	3.7	9.3	9.1	-
Estradiol (proliferative phase 220-918 pmol/L)	366	88	<73	-
9 AM cortisol (170-540 nmol/L)	426	-	-	363
Prolactin (<500 µU/ml)	424	228	185	-

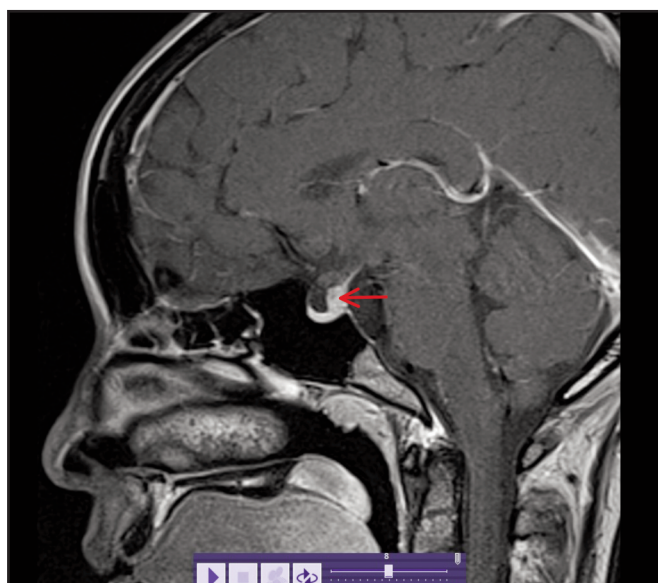


Fig. 1: Contrast-enhanced sagittal T1-weighted MRI image of the pituitary demonstrating thickening of the pituitary stalk (red arrow). The pituitary gland and optic chiasm appear normal.

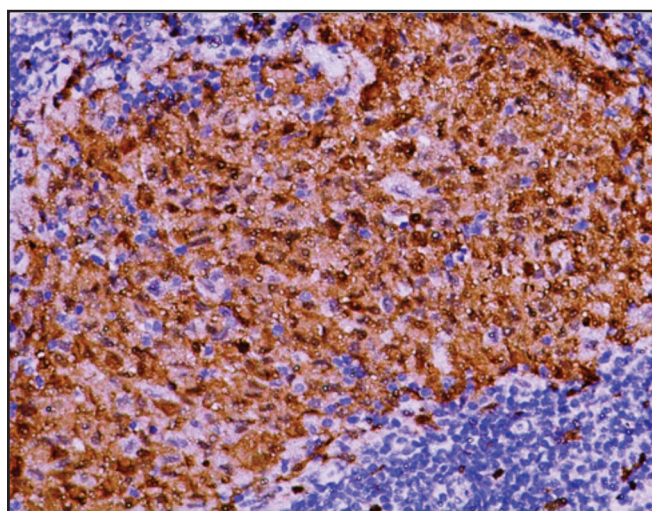


Fig. 2: Right cervical lymph node biopsy – S-100 staining. Magnification x20.

associated, activating oncogenic *BRAFV600E* gene mutation in more than 50% of cutaneous specimens of LCH examined suggests that it is a neoplastic disorder.³

LCH is rare in adults resulting in a paucity of data in this population. The International Registry of the Histiocyte Society reported 274 adults with biopsy proven LCH in 13 countries from January 2000 to June 2001. There was a female preponderance (143 vs 126) and the mean age of onset was two years earlier than at diagnosis, more than two-third had multisystem disease and 30% had cranial diabetes insipidus (CDI).⁴

LCH has been reported to infiltrate the hypothalamic-pituitary axis in up to 50% of patients in autopsy findings. This can result in permanent posterior and/or anterior

pituitary hormonal deficiencies. The most common and usually earliest endocrinological dysfunction is CDI, reported in 15-50% of patients with LCH and can predate anterior pituitary hormone deficiencies involvement by a median of 2 years (range 1-16 years).¹

The diagnosis of CDI, in LCH, can occur any time during the course of disease and predate that of the underlying disease as demonstrated in this case.¹ The patient developed cervical lymphadenopathy months after diagnosis of CDI and subsequent histopathological examination of an excised cervical lymph node confirmed LCH. This case demonstrates why onset of CDI and diagnosis of LCH can differ by up to 1-2 years particularly if the disease is not suspected due to its rarity, and lesions deemed accessible for sampling only develop later.

This case is particularly interesting as the patient was diagnosed to have ITP in childhood, and 13 years later found to have LCH. ITP unlike LCH (which is a neoplastic disorder) is an autoimmune disorder with the underlying pathophysiology of autoimmune destruction of platelets and inhibition of platelet production.² Although it has been reported that patients with chronic ITP have a 1.8% 5-year cumulative rate of developing haematological malignancy namely non-Hodgkin's lymphoma and acute myeloid leukaemia,² no association with LCH has ever been reported as far as we know. There is also the question of whether the patient could have LCH presenting as isolated thrombocytopenia in childhood which was diagnosed as ITP because of absence of other system or organ involvement particularly the bone. Single system LCH in children is more commonly seen in bone, skin, lymph node, central nervous system, lungs and even the thyroid and thymus.⁵ Thrombocytopenia in LCH is usually seen in the presence of anaemia and hepatosplenomegaly which would have made the diagnosis of ITP void.⁵

CONCLUSION

This is a rare case of LCH in adult with ITP diagnosed 13 years prior. Association of ITP and LCH is unknown but the question of LCH presenting as isolated thrombocytopenia in childhood only to be discovered in adulthood when there was pituitary and bone involvement remains. It reemphasizes the need for a high index of suspicion and highlights the challenges in diagnosing LCH at the outset.

REFERENCES

1. Kaltsas GA, Powles TB, Evanson J, Plowman PN, Drinkwater JE, Jenkins PJ, et al. Hypothalamo-pituitary abnormalities in adult patients with Langerhans cell histiocytosis: clinical, endocrinological, and radiological features and response to treatment. *J Clin Endocrinol Metab* 2000; 85(4): 1370-6.
2. Beardsley DS. ITP in the 21st century. *Hematology AM Soc Hematol Educ Program* 2006; 1: 402-7.
3. Varga E, Korom I, Polyánka H, Szabó K, Széll M, Baltás E, et al. BRAFV600E mutation in cutaneous lesions of patients with adult Langerhans cell histiocytosis. *J Eur Acad Dermatol Venereol* 2015; 29(6): 1205-11.
4. Aricò M, Girschikofsky M, Généreau T, Klersy C, McClain K, Grois N, et al. Langerhans cell histiocytosis in adults. Report from the International Registry of the Histiocyte Society. *Eur J Cancer* 2003; 39(16): 2341-8.
5. Haupt R, Minkov M, Astigarraga I, Schäfer E, Nanduri V, Jubran R, et al. Langerhans cell histiocytosis (LCH): guidelines for diagnosis, clinical work-up, and treatment for patients till the age of 18 years. *Pediatric Blood Cancer* 2013; 60: 175-84.