

# Idiopathic duodenal varix presenting as a massive upper gastrointestinal bleeding: A case report

Zubaidah Nor Hanipah, MS, Asraf Haslam Jasmani, MB BCH BAO, Lee Limi, MS, Tikfu Gee, MS

Department of Surgery, Faculty of Medicine and Health Sciences, University Putra Malaysia, Serdang, Selangor, Malaysia

### SUMMARY

**Ectopic variceal bleeding is both a diagnostic dilemma and a therapeutic challenge, especially when it is located in the third part of the duodenum. Varix is rare in the absence of cirrhosis or portal hypertension. Because the diagnosis of this condition is usually delayed, treatment is administered late resulting in high morbidity and mortality rate. We report a case of a 61-year-old lady with an idiopathic duodenal varix presenting as an upper gastrointestinal bleeding.**

### KEY WORDS:

*Bleeding, cirrhosis, portal hypertension, varix*

### INTRODUCTION

An ectopic varix is the presence of portosystemic collateral anywhere in the abdomen apart from the typical location in the gastroesophageal region. It can occur in the small bowel, colon, rectum, peristoma, bladder and vagina<sup>1</sup>. Duodenal varices are rare, account for 1-3% in cirrhotic patients.<sup>1,2</sup> The commonest sites are the duodenal bulb followed by the second part of the duodenum.<sup>2</sup> Two-thirds of these varices are due to portal hypertension secondary to liver cirrhosis. Extrahepatic portal hypertension causes the remaining duodenal varix, either due to the portal and splenic vein thrombosis or as a result of primary haematological diseases.<sup>3</sup>

Duodenal varices present with massive haematemesis or lower gastrointestinal bleeding. Mortality from duodenal variceal bleeding can be up to 40%.<sup>2</sup> Clinical presentation of bleeding from the third part of duodenal (D3) varices can be clinically misleading as it is potentially missed during a routine upper endoscopy. We present a rare case of idiopathic D3 varices complicated with massive bleeding.

### CASE REPORT

A 61-year-old lady presented with a sudden onset of massive melaena for the first time at home. She was pale and tachycardic but normotensive. Abdominal examination was normal. Her haemoglobin count was 7.2 g/dl with normal platelet and coagulation factors. Her liver function was normal and hepatitis screening was negative. Despite blood transfusion, she was still anaemic, but she was haemodynamically stable. Initial Oesophagogastroduodenoscopy (OGDS) showed large Forrest 2B ulcer at the first part of the duodenum which was injected with adrenaline endoscopically. There were multiple Forrest III

ulcers in the antrum and pre-pyloric region. Despite the intravenous infusion of proton pump inhibitor and packed cells transfusions, she was still tachycardic and continued to have haematochezia. Colonoscopy was normal but repeated OGDS showed varices at D3 with a cherry red spot (shown in figure 1), suggesting a recent bleeding episode. There was no endoscopic evidence of portal gastropathy or other varices. Computed tomography (CT) angiography of the mesentery showed varicosities at D3 with no extravasation of contrast and there was no evidence of liver cirrhosis or portal hypertension.

The patient was treated with endoscopic histo-acryl sclerotherapy. The procedure was uneventful and there was no evidence of bleeding during her hospital stay. Subsequently, she was discharged home well with propranolol and a plan for a frequent elective upper endoscopy to monitor the progression of varix.

### DISCUSSION

An idiopathic duodenal varix is a rare entity with high mortality risk. Two-thirds of the aetiology of this varix are due to cirrhosis of the liver with portal hypertension.<sup>3</sup> Its clinical presentation is usually that of a massive haematochezia. In the absence of liver cirrhosis and portal hypertension, varices are in the third part of the duodenum can be difficult to diagnose. Bleeding from such a lesion is often massive and technically difficult to achieve haemostasis endoscopically.

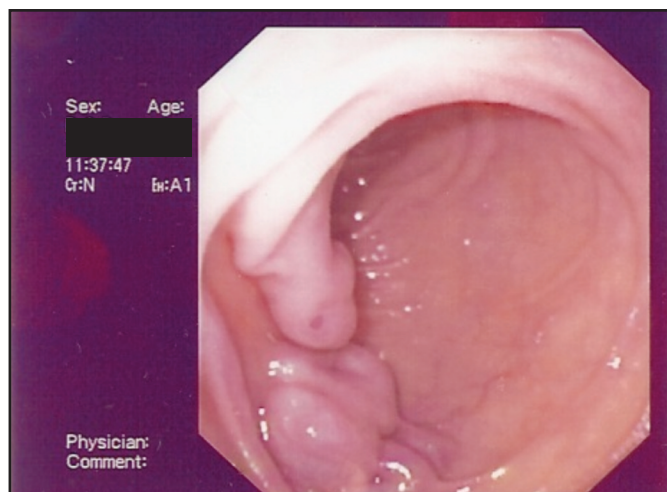
In cases of massive gastrointestinal bleeding, upper endoscopy is mandatory. If OGDS and colonoscopy were unremarkable, an endoscopic examination of the entire small bowel is recommended especially in a patient who presents with portal hypertension and history of previous gastrointestinal bleeding. In the absence of an obvious source of bleed, CT angiography should be considered as the primary modality for diagnosing ectopic varices.<sup>1</sup> In an acute setting, the role of magnetic resonance imaging (MRI) and capsule endoscopy are of little value.

There is no standard consensus with regards to the treatment option in the management for ectopic varices. Management of duodenal varix can be divided into pharmacological therapy, endoscopic interventions, radiological interventions and surgical intervention. Our patient was managed with pharmacological and endoscopic sclerotherapy injection. Endoscopic treatment consists of injection of liquid tissue

*This article was accepted: 17 June 2016*

*Corresponding Author: Zubaidah Nor Hanipah, Department of Surgery, Faculty of Medicine and Health Sciences, University Putra Malaysia, 43400 Serdang, Selangor, Malaysia*

*Email: n\_baidah@upm.edu.my*



**Fig. 1:** Endoscopic view of duodenal (D3) varices with stigmata of recent bleeding marked by a cherry-red spot (arrow)

adhesive, sclerosant with or without band ligation. Endoscopic sclerotherapy has been successful in securing haemostasis for bleeding duodenal varices. However, it has high rebleeding rate and damaging effect on the surrounding tissue which leads to complication such as perforation and stricture.<sup>5</sup> Interventional radiological management such as transjugular intrahepatic portosystemic shunt (TIPSS), portocaval shunting or variceal obliteration using balloon-occluded retrograde transvenous obliteration (BRTO) has reported the successful management of this varix.<sup>1</sup> Surgical intervention is usually performed in cases which failed endoscopic and radiological interventions. Surgical management includes ligation of varices, duodenal dearterialization and stapling or selective resection of the duodenum.<sup>1</sup>

Despite all these interventions, bleeding duodenal varix has a poor prognosis with a high mortality rate of 40% especially in the absence of an aetiology of the varix.<sup>5</sup> Therefore, prompt treatment and diagnosis with a multidisciplinary approach by the surgeon, gastroenterologist and interventional radiologist is recommended in the management of such a rare condition.

### CONCLUSION

An idiopathic duodenal varix is a rare entity dogged with a diagnostic and therapeutic dilemma. An immediate endoscopy along with a definitive therapy such as sclerotherapy is warranted. Frequent surveillance is vital in preventing future massive bleeding.

### REFERENCES

1. Nabeel M, Akhter, Ziv J, Haskal. Diagnosis and management of ectopic varices. *Gastrointestinal Intervention*. 2012;1:3-10.
2. Jonnalagadda SS, Quiason S, Smith OJ. Successful therapy of bleeding duodenal varices by TIPS after failure of sclerotherapy. *Am J Gastroenterol*. 1998; 93: 272-4.
3. Cottam D, Clark R, Hayn E, Shaftan G. Duodenal varices: A novel treatment and literature review. *Am Surg*. 2002; 68(5): 407-9.
4. Sato T, Akaike J, Toyota J, Karino Y, Ohmura T. Clinicopathological features and treatment of ectopic varices with portal hypertension. *International journal of hepatology*. 2011.
5. Akahoshi T, Hashizume M, Shimabukuro R, Tanoue K, Tomikawa M, Okita K, Gotoh N, Konishi K, Tsutsumi N, Sugimachi K. Long-term results of endoscopic Histoacryl injection sclerotherapy for gastric variceal bleeding: a 10-year experience. *Surgery*. 2002; 131(1): S176-81.