

Thoracic Aortic Aneurysm as A Cause of Ortner's Syndrome – A Case Series

Ismazizi Zaharudin, MS, Zainal Ariffin Azizi, MS

Department of General Surgery, Hospital Kuala Lumpur, Jalan Pahang, 50586 Kuala Lumpur

SUMMARY

Hoarseness due to left recurrent laryngeal nerve paralysis was first described in 1897 by Norbert Ortner. Various cardiopulmonary and thoracic arch aorta pathologies associated with left recurrent laryngeal nerve palsy have been described over the last 100 years and is also known as cardio-vocal syndrome.

We report our experience with seven cases of Ortner's syndrome due to thoracic aortic aneurysm with compression of the left recurrent laryngeal nerve and resultant hoarseness.

KEY WORDS:

Thoracic aortic aneurysm, hoarseness, recurrent laryngeal nerve

INTRODUCTION

In 1987, Nobert Ortner first described left recurrent laryngeal nerve palsy from compression of an enlarged left atrium as a sequelae of severe mitral stenosis. Now this rare syndrome has been attributed to any cardiovascular disease resulting in impingement of the left recurrent laryngeal nerve at the aorto-pulmonary window, hence, it is sometimes known as cardio-vocal syndrome.¹

In the superior mediastinum, left recurrent laryngeal nerve arises from the vagus, descends down antero-lateral to the arch of aorta, hooks under the arch of aorta crossing the ligamentum arteriosum and then ascends in the trachea-oesophageal groove. The nerve can be compressed between the aorta, ligamentum arteriosum and left pulmonary artery as the aneurysm expands.

This report describes our experience in managing Ortner's Syndrome from thoracic aortic aneurysms. The patient's characteristic, initial symptoms, type of interventions and outcome will be presented and discussed.

CASE REPORT

We report a series of seven patients with Ortner's Syndrome due to thoracic aortic aneurysm, encountered in the Vascular unit, Hospital Kuala Lumpur between 2011 till 2014. All presented with hoarseness ranging from altered voice quality, pitch and loudness and four with associated dysphagia. Five patients agreed for intervention and underwent thoracic endovascular aneurysm repair (TEVAR) using a Valiant® thoracic stent graft (Medtronic Santa Rosa, USA) but two

patients refused any surgical intervention and were subsequently lost to follow-up. Out of seven patients, six of them were males, age ranging from 56 to 78 years old. The aneurysms were mainly arising from the arch and proximal descending aorta. All patients who underwent surgical intervention showed improvement from initial symptoms after one year follow-up except for one patient. The patients demographic, co-morbidities, initial symptoms, morphology of the aneurysm and size, surgical procedures and outcome are all summarized in Table I.

DISCUSSION

Ortner's syndrome is a rare cause of left recurrent laryngeal nerve palsy and is due to compression of this nerve by any structure that bounds the aorto-pulmonary window. In the superior mediastinum, left recurrent laryngeal nerve arises from the vagus, descends down antero-lateral to the arch of aorta, hooks under the arch of aorta crossing the ligamentum arteriosum and then ascends in the trachea-oesophageal groove. The nerve can be compressed between the aorta, ligamentum arteriosum and left pulmonary artery.^{1,2}

Causes of Ortner's syndrome include left atrial enlargement, severe pulmonary hypertension and thoracic aortic aneurysms.^{1,2} The incidence of thoracic aortic aneurysms (TAA) are estimated to be 16.3 per 100 000 in males and 9.1 per 100 000 in females. In our case series, there was a male preponderance. Most thoracic aneurysms are asymptomatic. Ortner's Syndrome is suspected when there is a complain of hoarseness with a widened mediastinum on CXR (Fig. 1) as up to 5% of patients with TAAs develop cardio-vocal hoarseness when the aneurysm involving the proximal part of descending aorta, or distal aortic arch (Fig 2). Direct laryngoscopy of the patients will reveal left vocal cord palsy. Other symptoms include dysphagia due to compression of the oesophagus and breathing difficulties due to incomplete opening of the glottis.³ The morphology of the aortic aneurysms can be either saccular, fusiform or dissecting. Early diagnosis of syndrome may be helpful in starting immediate treatment to restore vocal cord function and prevent permanent damage to the left recurrent laryngeal nerve. Voice improvement is expected within a few weeks of surgery and hoarseness has been reported to resolve completely at least within 4 months after surgery.⁴ Endovascular stent grafting of the underlying TAA causes progressive shrinkage of the excluded and thrombosed aneurysm reducing the nerve compression leading to resolution of the left recurrent laryngeal nerve palsy. The

This article was accepted: 23 March 2016

*Corresponding Author: Zainal Ariffin Azizi, Consultant General/ Vascular Surgeon, Head of Department of General Surgery, Kuala Lumpur Hospital, Jalan Pahang, 50586, Kuala Lumpur
Email: mrzainalhkl@gmail.com*

Table I: summary of the patients age, sex, co-morbid, type of thoracic aneurysm , size, procedure and type of debranching and patient initial symptom outcome

| Case No) Gender /Age (yrs) | Co-morbid | Initial symptoms | Type of thoracic aneurysm / size (cm) | Procedure/ proximal landing zone/ type of debranching | Outcome after one year |
|----------------------------------|---|-------------------------|--|---|--|
| 1) male / 78 | Diabetes mellitus, Hypertension, CKD & smoker | Hoarseness Dysphagia | Fusiform / 9 | TEVAR/ zone 2 / carotid-carotid crossover bypass | Dysphagia resolved & improvement of hoarseness |
| 2) male / 67 | Diabetes mellitus, Hypertension, CKD & smoker | Hoarseness Dysphagia | Fusiform / 8 | TEVAR/ zone 1/ carotid-carotid crossover bypass | Dysphagia resolved & improvement of hoarseness |
| 3) male / 74 | Smoker | Hoarseness | Saccular / 8 | TEVAR/ zone 1/ carotid-carotid & carotid- LSA bypass | Dysphagia resolved & improvement of hoarseness |
| 4) male / 56 | Hypertension, Smoker | Hoarseness Dysphagia | Saccular / 8 | TEVAR/ zone 1/ carotid-carotid crossover bypass | Dysphagia resolved & improvement of hoarseness |
| 5) female / 73 | Hypertension CKD | Hoarseness | Saccular / 6 | TEVAR/ zone 1/ carotid-carotid crossover bypass | Dysphagia resolved but hoarseness remain |
| 6) male / 56 | Diabetes mellitus, Hypertension Smoker | Hoarseness | Fusiform / 8 | Refused intervention | Lost to follow up |
| 7) male / 73 | Hypertension Smoker | Hoarseness Dysphagia | Saccular / 8 | Refused intervention | Lost to follow up |

CKD- chronic kidney disease
LSA- left subclavian artery

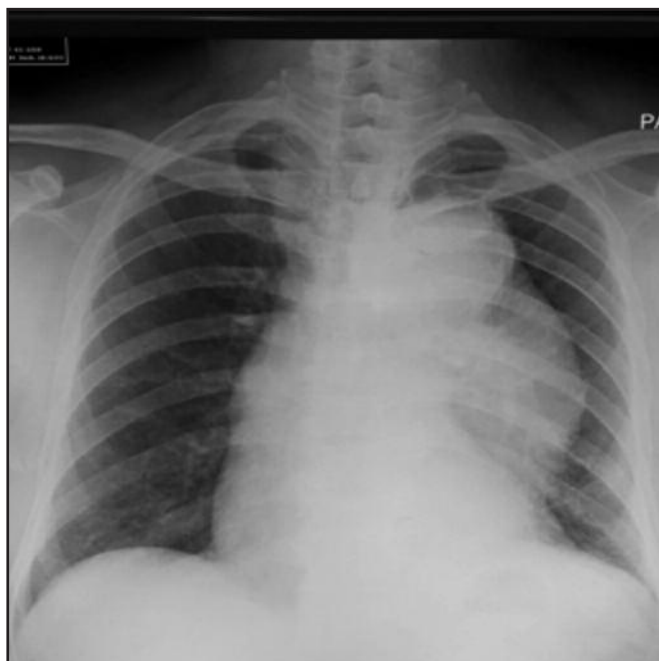


Fig. 1: Chest x-ray showing a widened mediastinum due to a descending aortic aneurysm.

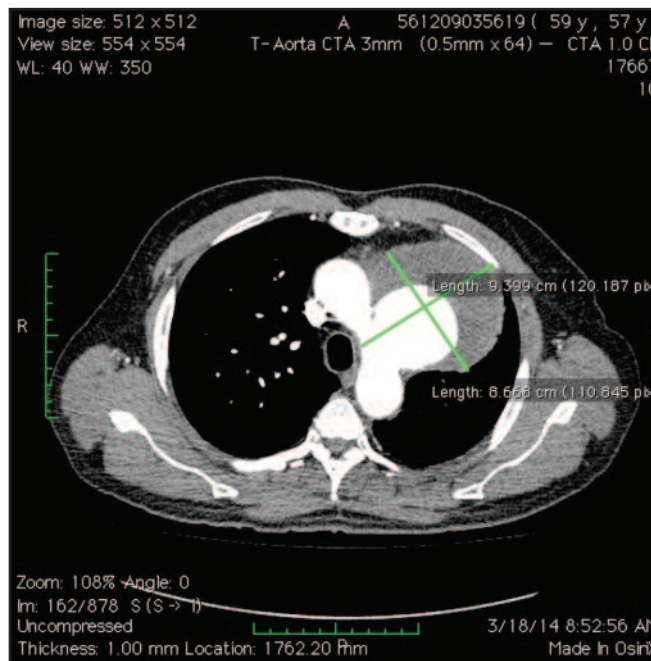


Fig. 2: Sagittal view of computed tomography the saccular aneurysm involving the aortic arch in a patient with hoarseness.

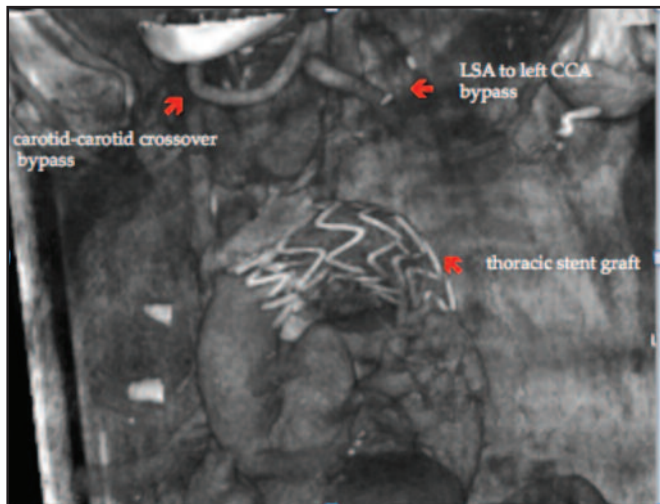


Fig. 3: Reconstructed CTA of patient showing the debranching bypass procedure and the TEVAR stent in-situ.

earliest report of recovery from Ortner's syndrome following endoluminal treatment was in 2004.⁵ TEVAR is less invasive, less expensive and of a lower operative risk compared to standard open repair of aneurysms.^{4,5} especially if the patient is at high risk for the open intervention.

CONCLUSION

Ortner's Syndrome is uncommon. When a patient presents with hoarseness, one should never overlook the possibility of a cardiovascular cause so that a delay in diagnosis is avoided and an immediate therapy is started as recovery is possible with early intervention. The use of endovascular stenting have reduced the mortality and morbidity of intervention.

REFERENCES

1. Ali Shah MU, Siddiqi R, Chaudhri MS, Khan AA, Chaudhry I. Aortic Aneurysm : A rare cause of Ortner's Syndrome. *J Coll Physicians Surg Pak* 2014; 24: 282-4.
2. Gulel O, Elmali M, Demir S, Tascanov B . Ortner's Syndrome associated with aortic arch aneurysm. *Clin Res Cardiol* 2007; 96(1): 49-50.
3. Bruno LD, Lenilton CC, Helder CM, Vagner MV, Rodolfo ED, Andre Geraldo SD. Ortner's syndrome: A case report and review of literature. *Radio Bras* 2015; 48(4): 260-2.
4. Eccles SR, Banks J, Kumar P. Ascending Aortic aneurysm causing hoarse voice – A variant of Ortner's syndrome. *BMJ Case Reports* 2012; 2012: 1-3.
5. Escribano JF, Carnés J, Crespo MA, Antón RF. Ortner's syndrome and endoluminal treatment of thoracic aortic aneurysm : A case report. *Vasc Endovascular Surg* 2006; 40: 75-8.