

Sinonasal angioleiomyoma

Yu Wei Lau¹, MD, Vikneswaran Tharumalingam¹, MS, Tee Yong Tan¹, MS, Ing Ping Tang^{1,2}, MS

¹Dept of ORL-HNS, Sarawak General Hospital, Kuching, Sarawak, ²Dept of ORL-HNS, Faculty of Medicine, University Malaysia Sarawak, Sarawak

SUMMARY

Background: Angioleiomyoma of the nasal cavity is an extremely rare benign neoplasm. It usually occurs in the lower extremities. Up to date, only few cases of angioleiomyoma have been reported. First case of angioleiomyoma of nasal cavity was reported in 1966. We report a rare case of angioleiomyoma arising from the right maxillary sinus.

Case Report: A 43-year-old lady presented with recurrent epistaxis and right nasal obstruction for two months duration. Clinical examination revealed a huge right nasal mass obstructing the right nasal cavity. The tumour was excised completely via endoscopic endonasal surgical approach. Histopathological examination confirmed the tumour is sinonasal angioleiomyoma. Postoperatively, she recovered well without any recurrence after a year of follow-up.

Conclusion: This tumour has an excellent prognosis and recurrence is extremely rare if excised completely.

KEY WORDS:

Nasal cavity, angioleiomyoma

INTRODUCTION

Angioleiomyoma is a benign tumour arising from the vascular smooth muscle (tunica media) which is rarely found in the nose and paranasal sinus.¹ In 1966, Maesaka et al. reported the first case of angioleiomyoma of the nasal cavity.² Hachisuga et al. reported only five cases of angioleiomyoma identified in the nasal cavity from 1966 to 1978.³ Since then, only a few cases have been reported. To the best of our knowledge, no cases have been reported in Malaysia.

CASE REPORT

A 43-year-old lady presented to ENT clinic with the chief complaint of right nasal recurrent epistaxis associated with nose blockage, rhinorrhea and right facial pain for two months duration. Physical examination is unremarkable. Nasal endoscopy showed a nasal mass obstructing the entire right nasal cavity. Computed tomography (CT) scan of paranasal sinuses showed a nasal mass occluding the right maxillary antrum, right anterior and posterior ethmoidal sinuses completely with erosion of medial wall of maxillary antrum (Figure 1 and 2). A punch biopsy revealed inflammatory nasal polyps. She subsequently underwent endoscopic endonasal resection of tumour. Intraoperative, a vascular right maxillary sinus mass was found filling up the

whole nasal cavity. It involved the lateral wall of nasal cavity, inferior turbinate, middle turbinate and anterior as well as posterior ethmoidal sinuses. Posterior maxillary sinus bony wall was also eroded. The tumour most likely originated from right lateral nasal wall. Right sphenopalatine artery was ligated to secure haemostasis. Right inferior meatus, right inferior turbinate and lateral wall of right nasal cavity was removed together with the tumour. Histopathological examination revealed the tumour had low-to-moderate cellularity consisting of spindle to stellate cell proliferation, set in dense hyalinized fibrocollagenous stroma, focal area of high vascularity exhibiting focal crowding cavernous type of vessels forming papillary endothelial hyperplasia in areas. This tumour cells expressed diffuse smooth muscle actin positivity. Additional immunostains for CD34 and desmin were negative (Figure 3). This confirmed the diagnosis of sinonasal angioleiomyoma. She recovered well after the operation and has been disease free after a year of follow-up.

DISCUSSION

Leiomyomas are benign soft tissue neoplasms that arise from smooth muscle. They are very rare found in the head and neck region. The World Health Organization (WHO) classified leiomyoma into leiomyoma, angioleiomyoma (vascular leiomyoma and angioleiomyoma) and epithelioid leiomyoma (bizarre leiomyoma and leiomyoblastoma).⁴ Angioleiomyoma is classified into three histologic types; solid or capillary, cavernous and venous. Solid tumour is mainly found in the limbs while the venous type is more frequently found in the head and neck. According to Enzinger and Weiss, 95% of 7748 leiomyomas occurred in the female reproductive system, 3% in the skin, 1.5% in the gastrointestinal tract and the remainder in various human parts.¹ Only less than 1% of all vascular leiomyoma is in the nasal cavity.³ A review of 562 cases of angioleiomyoma by Hachisuga et al. over a 17-year period, only 48 were seen in the head and neck area and only five of these in the nasal cavity (Table I).

Three hypotheses have been proposed to explain the presence of smooth muscle tumour in the nasal cavity. Firstly, the smooth muscle in nasal cavity may arise from erector pilae muscle and sweat gland of nasal vestibule. Secondly, they may originate in the aberrant undifferentiated mesenchyme and lastly is the presence of smooth muscle elements in the walls of the blood vessels.

The most common location of sinonasal angioleiomyoma is at the inferior turbinate. Other sites include the nasal vestibule, within nasal polyps and from the nasal septum.

This article was accepted: 30 March 2016

Corresponding Author: Ing Ping Tang, University Malaysia Sarawak, Otorhinolaryngology Head and Neck Surgery, Lot 77, Seksyen 22, Kuching Town Land District, Jalan Tun Ahmad Zaidi Adruce, 93150 Kuching, Kuching, Sarawak 93150, Malaysia
Email: ingptang@yahoo.com

Table I: Angioleiomyoma case reported from 1966 to 1987

Authors	Age/Gender	Year	Site	Symptom
Maesaka <i>et al.</i>	49/F	1966	Vestibule	Facial pain
Wolfowitz <i>et al.</i>	42/F	1973	Inferior turbinate	Epistaxis
Schwartzman <i>et al.</i>	57/M	1973	Sphenoid sinus, ethmoid and maxillary	Nasal obstruction, headache, epistaxis
Trimiryaleev <i>et al.</i>	25/F	1973	Septum	Epistaxis, nasal obstruction, headache
McCaffrey <i>et al.</i>	76/F	1978	Inferior turbinate	Epistaxis, nasal obstruction

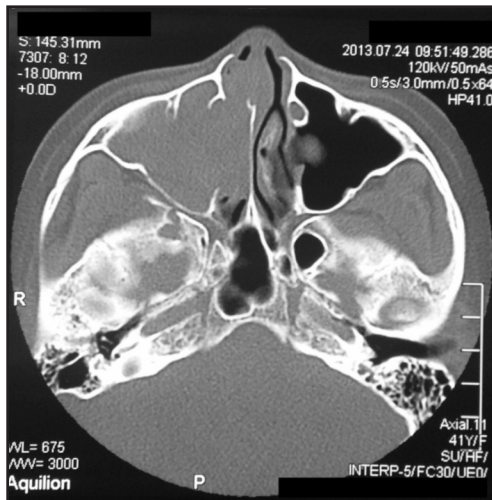


Fig. 1 : CT scan axial view homogenous mass at right nasal cavity and right maxillary sinus.

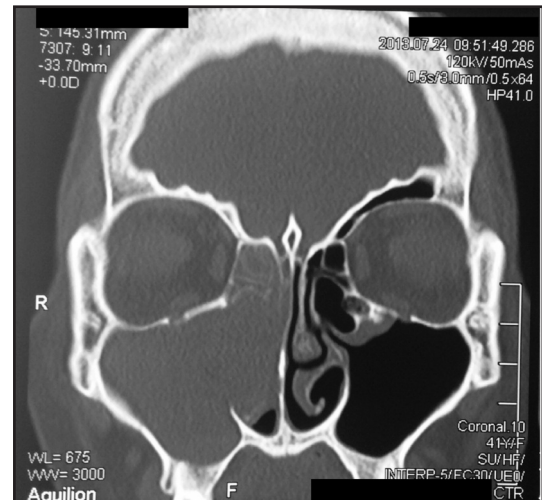


Fig. 2 : CT scan coronal view homogenous mass at right nasal cavity and right maxillary sinus.

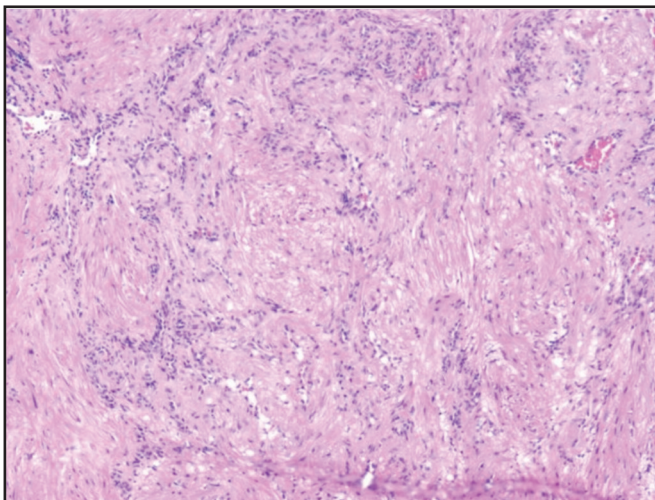


Fig. 3 : Histology of spindle cells that resemble smooth muscle and numerous vessels.

Barr *et al.* explained inferior turbinate is common location due to the presence of excess contractile vascular tissue in the inferior turbinate. Females are more prone with age ranged from 25 to 76 and average of 55.6 years old.

The causes of sinonasal angioleiomyoma are unknown although trauma, steroid therapy and hormonal imbalance have been implicated in the past. The common symptoms of sinonasal angioleiomyoma are nasal obstruction, epistaxis, facial pain and headaches.

There is no characteristic radiological finding for angioleiomyoma, but CT or MRI is needed to identify extent of tumour and surgical planning. The only way to determine the diagnosis is surgical excision with histologic examination. Several stains have been used to identify angioleiomyoma such as desmin, vimentin, actin, myosin and Masson's trichrome.⁵ In our case, the tumour is positive for smooth muscle actin.

The treatment of choice is surgical resection. Recurrence can occur if incomplete resection. This event shows potential recurrence after incomplete resection and the need for complete excision in order to guarantee a definitive treatment.

In conclusion, this tumour has an excellent prognosis and recurrence is extremely rare if excised completely.

REFERENCES

1. Enzinger F, Weiss S. Soft tissue tumours. Second ed. St. Luis: Mosby; 1988. 21. pp. 383-401.
2. Maesaka A, Keyaki Y, Nakahashi T. Nasal angioleiomyoma and leiomyosarcoma: report of 2 cases. *Otologia (Fukuoka)* 1966; 12: 42.
3. Hachisuga T, Hashimoto H, Enjoji M. Angioleiomyoma: a clinicopathologic reappraisal of 562 cases. *Cancer* 1984; 54(1): 126-30.
4. Muroso S, Ohmura T, Sugamori S, Furukawa M. Vascular leiomyoma with abundant adipose cells of the nasal cavity. *Am J Otolaryngol* 1998; 19(1): 50-3.
5. Wang CP, Chang YL, Sheen TS. Vascular leiomyoma of the head and neck. *Laryngoscope* 2004; 114: 661-5.