

Primary breast tuberculosis (TB) in a patient with known invasive breast carcinoma: A case report

Chang Haur Lee, MBBS, Siti Zubaidah Sharif, MS

Queen Elizabeth Hospital Kota Kinabalu, Sabah Malaysia

SUMMARY

Breast tuberculosis (TB) is rare even in endemic countries. Most of these cases occur as secondary TB due to a concurrent infection. Primary breast TB is diagnosed when it is the only site of disease without other foci of infection. The presentation of primary breast TB may often mimic carcinoma of the breast. While imaging is not specific, histopathology provides a definitive diagnosis. Here, we present a case of primary breast TB in a breast cancer patient and review the literature.

KEY WORDS:

Tuberculosis, breast tuberculosis, breast cancer Case Report

INTRODUCTION

Breast tuberculosis (TB) is rare. The incidence rate of this disease entity in the developed and industrialized nations range from 0.025-0.1%, increasing to approximately 4% in endemic countries.¹⁻⁴ It can be primary when there is no other source of infection in the body except the breast, or secondary due to concurrent infection. Primary breast TB lesions may be difficult to diagnose and may often mimic carcinoma.⁵ Here, we report a case of isolated primary breast TB in a known breast cancer patient.

CASE REPORT

We present a 41-year-old lady with history of right breast invasive ductal carcinoma grade 2, TNM staging T1, N26/26, M0. Lymphovascular invasion was positive, Oestrogen and Progesterone Receptor were negative. Her-2 was 2+ (equivocal). She underwent right mastectomy and axillary clearance, followed by 6 cycles of chemotherapy (FEC), 15 fractions of radiotherapy and 17 cycles of trastuzumab (Herceptin).

Routine ultrasonography and mammography of the left breast a year later showed two ill-defined lesions at the 1 o'clock position measuring 0.9x0.5 and 1.2x0.4cm respectively with dilated ducts (Figure 1). These lesions were classified as BIRADS IV and hook-wire guided wide local excision of the lesions revealed fibroadenomas.

One year following the wide local excision, the patient complained of left breast mastalgia without any palpable lesions in the left breast. Ultrasonography showed a well-defined sub-areolar cyst measuring 11x8x10mm at the 6

o'clock position containing avascular debris, probably representing an inflamed cyst (Figure 2). The patient was treated conservatively with close follow-up and a repeat ultrasound 3 months later showed the same lesion, a fluid component with an echogenic foci representing a seroma, and classified as BIRADS 2 (Figure 3). There were no enlarged or suspicious axillary lymph nodes detected during both ultrasonography sessions and mammography was unremarkable as well.

Following persistence of the lesion, fine needle aspiration was attempted but did not yield any aspirate. A core needle biopsy was then performed and histopathology showed breast tissue with areas of oedema and mixed acute and chronic inflammation. Fibrosis was seen with several foci of foamy histiocytes and vague granulomatous aggregates of epithelioid histiocytes and giant cells. There were minute pieces of polarisable refractile foreign material seen entrapped within fibrin. The final impression was that of inflammation due to suture granuloma. She was then treated conservatively and planned for serial ultrasound to monitor the lesion.

However, she presented again 2 months later with a small ruptured abscess cavity measuring 1x1cm over the previous left breast surgical site. The cavity was excised entirely and histopathology report revealed breast TB, as evidenced by numerous foci of epithelioid granulomas consisting of epithelioid histiocytes surrounded by lymphocytes and numerous Langhan-type multinucleated giant cells. Ziehl-Neelsen stain for acid fast bacilli was positive.

Pulmonary TB work-up was negative. She was started on anti-tuberculous therapy with oral Akurit and continues to be followed-up by our Tuberculosis and Infectious Diseases Unit. During a recent review, no new lumps were detected and there was no evidence of local or regional recurrence, or distant metastases of her right breast carcinoma thus far.

DISCUSSION

TB breast is uncommon as breast tissue, like the spleen and skeletal muscle, is naturally resistant to tuberculosis.¹ Primary TB breast is rare and is postulated to occur resulting from skin infection through skin abrasions or lacrimal duct openings in the nipple, which commonly occurs in lactating women during breastfeeding.² The majority of case are classified as secondary breast TB, which is commoner and is

This article was accepted: 18 March 2016

Corresponding Author: Chang Haur Lee, Queen Elizabeth Hospital, Kota kinabalu, Sabah

Email: lchaur@gmail.com

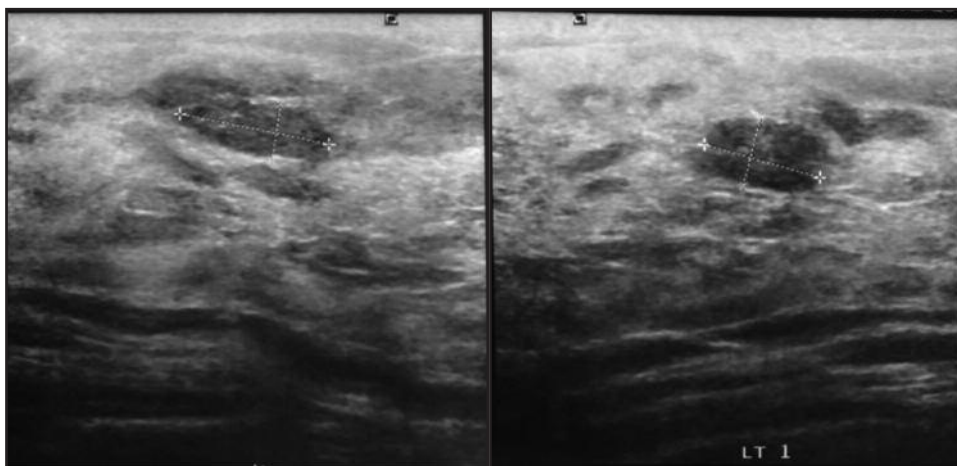


Fig. 1: Two ill-defined lesions at left breast.

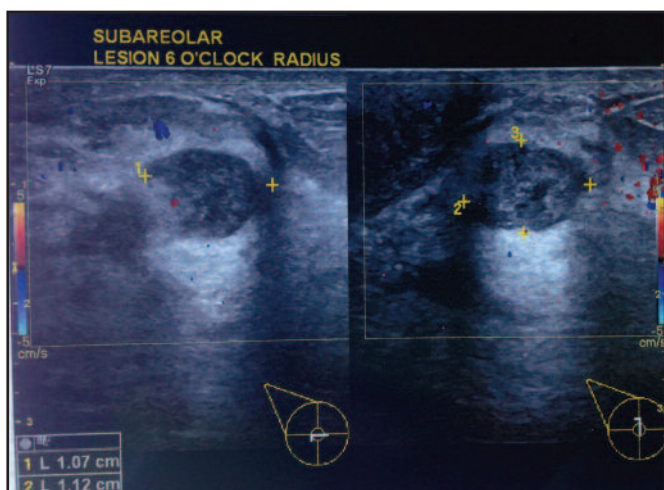


Fig. 2: 11x8x10mm cystic lesion containing avascular debris suggestive of an inflamed cyst.

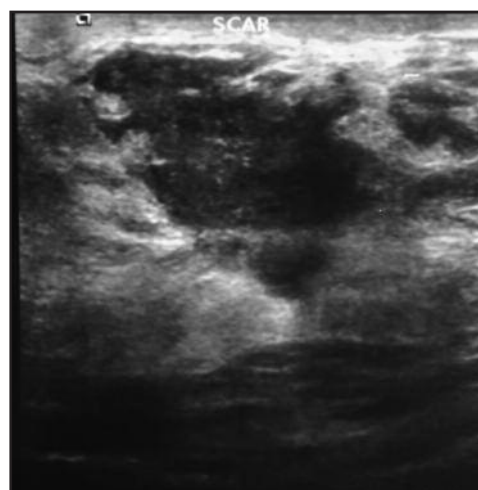


Fig. 3: Ill-defined lesion with fluid component and echogenic foci.

usually as a result of underlying infection that has spread to the breast. Spread occurs typically via 3 routes-hematogenous spread, lymphatic spread from affected lymph nodes or direct spread from the lungs.² Although this condition predominantly affects the female population, some authors have also reported the odd case of male breast TB and should alert the clinician of the possibility of this entity in male patients with a suspicious breast lump.¹⁻²

Tewari *et.al* recently classified TB breast to 3 categories-nodulo-caseous tubercular mastitis, disseminated/confluent tubercular mastitis, and tubercular breast abscess.³ The approach to investigate breast TB is similar to how one would normally approach a breast lesion; clinical examination, imaging modalities and histological studies.

Studies have reported that the commonest presentation of breast TB is of the nodulo-caseous variety; that of a fibroadenoma, or more sinisterly as a hard ill-defined lesion that may be fixed to the underlying muscle or skin not unlike the appearance of a carcinoma.⁴⁻⁵ Some patients with breast

TB may present with a discharging sinus which may suggest an underlying abscess cavity but this non-exclusive clinical feature may also occur in cases of actinomycosis, of which utility of fungal cultures will confirm the latter.² Disseminated or confluent tubercular mastitis is even more perplexing as this condition mimics chronic mastitis, a condition where diagnosis can often be also misdiagnosed as inflammatory carcinoma.² The presence of constitutional symptoms typical of TB such as fever, night sweats, loss of weight and generalised malaise is rather atypical and the combination of symptoms commonly vary among patients.^{1-3, 5} Our patient who presented with an initial nodular, hard lump subsequently evolving into an abscess could probably represent a progression from the nodulo-caseous to the abscess-like variant. She did not have any of the aforementioned usual constitutional symptoms of TB.

Ultrasonographic imaging may not be specific to TB and as in our patient, may show heterogenous hypoechoic lesions with irregular borders similar to an abscess.¹ Mammography is just as non-specific, displaying dense solitary lesions with

fibrous spicules, surrounding tissue oedema and nipple retraction that would be often seen in different presentations of carcinoma.¹ Computed tomography and magnetic resonance imaging does not improve diagnostic accuracy and may show a cystic lesion with peripheral enhancement with associated surrounding enhancing lesions indicating micro-abscesses.⁵ Likewise, our patient had non-specific features on ultrasonography describing a suspicious cystic lesion and a normal mammographic study.

Due to diagnostic ambiguity via clinical examination and diagnostic imaging, aids to diagnosis are usually found using histopathologic, bacteriological and serologic means. Fine-needle and core-needle biopsies are usually the first methods of obtaining histopathological samples without being overly invasive. The presence of caseating granulomas, epithelioid cells and lymphohistiocytosis will likely point to the diagnosis of breast TB, and although the detection of acid-fast bacilli is pathognomonic, it is not always seen in histopathological samples.^{1,2} Bacteriological cultures of pus aspirates may grow tuberculous bacilli but growth is often slow and of low yield leading to delay in diagnosis and treatment.¹ Polymerase chain reaction for tuberculous mycobacterium is another alternative which may be more efficacious but is technology dependent and is costly.¹ Therefore, pathologists and lab technicians should also be aware and vigilant in ruling out possible differentials such as plasma cell mastitis, fat necrosis and actinomycosis accordingly. The occurrence of a new lesion at the previous site of wide local excision with core-needle biopsy result suggesting that of suture granuloma further confounded the underlying diagnosis of TB in our patient. The rupture of the abscess in her case helped clinch the diagnosis only after a wide local excision specimen revealed presence of acid-fast bacilli.

Treatment of breast TB employs the usual combination drugs of isoniazid, rifampicin, pyrazinamide and ethambutol with a similar six month regime consisting of a two month intensive phase followed by four months of maintenance therapy.⁵ Surgery is usually only performed for treatment resistant cases, reserving mastectomy only for rare and severely debilitating forms of the disease. Our patient received six months treatment with anti-tuberculous medication.

CONCLUSION

Breast TB is rare, even in endemic countries. It is difficult to diagnose and may mimic carcinoma or an abscess. Imaging is not specific and may not aid much in diagnosis. Definitive diagnosis is achieved by histopathology and isolation of the tubercular bacilli. An astute clinical judgement is required to ensure that the diagnosis is made as early as possible so that treatment can be initiated promptly.

REFERENCES

1. Harris SH, Khan MA, Khan R, Haque F, Syed A, Ansari MM. Mammary tuberculosis: Analysis of thirty-eight patients. *ANZ J Surg* 2006; 76: 234-7.
2. Khanna R, Prasanna GV, Gupta P *et al.* Mammary tuberculosis: report on 52 cases. *Postgrad Med J* 2002; 78: 422-4.
3. Gupta S, Singh VJ, Bhatia G, Dhuria K. Primary tuberculosis of the breast manifested as abscess: a rare case report. *Acta Med Indones* 2014 Jan; 46(1): 51-3.
4. Prathima S, Kalyani R, Parimala S. Primary tubercular mastitis masquerading as malignancy. *J Nat Sci Biol Med* 2014; 5(1): 184-186. doi:10.4103/0976-9668.127324.
5. Akçay MN, Saçlam L, Polat P, Erdoğan F, Albayrak Y, Povoski SP. Mammary tuberculosis – importance of recognition and differentiation from that of a breast malignancy: report of three cases and review of the literature. *World Journal of Surgical Oncology* 2007; 5: 67.