

The sensitivity, specificity and predictive values of post mortem computed tomography in detecting liver and splenic injury due to road traffic accident

Norzailin Abu Bakar, MMed (Radiology) UKM*, Noor Azman Shairi, MMed (Radiology) UKM**, Mohammad Helmi Mohammad Nor, MMed (Radiology) UKM***, Khairul Anuar Zainon, MMed (Pathology)****

*Radiology Department, Faculty of Medicine, National University of Malaysia, Kuala Lumpur, **KPJ University College, Nilai, Negeri Sembilan, ***Radiology Department, Hospital Kuala Lumpur, Kuala Lumpur, ****Forensic Department, Hospital Kuala Lumpur, Kuala Lumpur

ABSTRACT

Objective: The purpose of the study was to determine the sensitivity, specificity, positive predictive value (PPV) and negative predictive value (NPV) of post mortem computed tomography (PMCT) in detecting liver and splenic injuries due to road traffic accidents.

Material & Method: 61 road traffic accidental death cases underwent both PMCT and conventional autopsy. The imaging findings were compared to the conventional autopsy findings.

Result: The sensitivity, specificity, PPV and NPV for liver injuries in PMCT was 71%, 82%, 68% and 85% while that of splenic injuries was 73%, 80%, 55% and 90% respectively. The accuracy of PMCT scan was 79% for both liver and splenic injuries. There is strong association between lower left ribs fracture and splenic injury ($p=0.005$) and significant association between positive liver and splenic PMCT finding and intraabdominal fatal injury ($p=0.037$).

Conclusion: In conclusion PMCT has high specificity and NPV for liver and splenic injuries; however the sensitivity and PPV are low. The overall accuracy is not high enough to enable PMCT to be used as a replacement for conventional autopsy; however it is a useful complementary examination and has potential to be used as decision making tool for selective internal autopsy.

KEY WORDS:

Post mortem CT scan; virtual autopsy; conventional autopsy; sensitivity of post mortem CT; accuracy of post mortem CT

INTRODUCTION

Autopsy is a Greek word which means "see for yourself". It is a surgical operation or procedure, performed by specially-trained physicians, on a dead body. Other terms usually used are necropsy or post mortem examination. It is traditionally performed to establish the cause of death, to assist in determining the manner of death for example homicide or suicide, to produce accurate vital statistics in the field of medical research, for medico-legal and litigation purposes.

Invasive internal or "body-opening" autopsy represents the traditional means of post mortem examination. Despite advances in the field of medical imaging, the use of imaging techniques in forensic lagged behind other clinical fields. Brogdon,¹ in his book *Forensic Radiology*, makes the following statement: "The sad truth is that a century after the first x-ray was introduced as evidence in a court of law, there is no general appreciation of the extent of the radiologic potential in the forensic sciences". Diagnostic imaging is still underused in forensics, mainly due to unawareness of its potential and the lack of teaching and experience.

The first forensic application of computed tomography (CT) was a description of the pattern of gunshot injury to the head by Wullenweber *et al.* in 1977.² In our country, the idea of imaging autopsy was introduced in 2005 as announced by the Ministry of Science, Technology and Innovation.³

In our county, road traffic accident was a major issue with fatalities of over 6,000 per year since 2003.⁴ Based on our hospital departmental records, 20 to 22% of the numbers of autopsies performed yearly were due to fatalities from road traffic accidents. Road traffic accidents make up more than 50% of major intra-abdominal injuries.⁵ The organs most commonly involved were spleen and liver.⁶

Since autopsy imaging is relatively new in our country, a lot of data and research are needed to determine the value and to validate post mortem imaging findings. This is important due to the medico legal nature of the examination. Road traffic accidents cases are ideal due to the high prevalence in this country and the necessity of post mortem study in these cases. This study aims to compare the post mortem imaging findings with conventional autopsy finding and determine the value of post mortem imaging in the cases of liver and splenic injuries due to traffic accident using conventional autopsy finding as the gold standard.

Literature reviews were limited as not many study of this nature worldwide. A study in 1989 comparing non-contrast and contrast enhanced CT scan showed that non-contrast CT study is inferior to contrast enhanced study in detecting intra-abdominal organs injuries in living patient. The sensitivity

This article was accepted: 27 November 2015

Corresponding Author: Norzailin Abu Bakar, Consultant Radiologist & Lecturer, Radiology Department, Faculty of Medicine, National University of Malaysia, Jalan Yaacob Latif, Bandar Tun Razak, 56000 Cheras, Kuala Lumpur, Malaysia
Email: divaleen@gmail.com

for all abdominal injuries in non-contrast study was 64% compared to 92% in contrast enhanced study.⁷ However, in post mortem computed tomography (PMCT), the use of contrast medium is not technically and physiologically possible due to absence of blood flow in a dead body.

In 1999, a study in 41 haemodynamically unstable trauma cases documented a sensitivity of 67% and specificity of 89% for the detection of traumatic liver injuries using non-contrast CT study in living patients.⁸

In a PMCT study in 2007 (termed as perimortem study) using 113 traumatic death cases, the sensitivity, specificity, positive predictive value (PPV) and negative predictive value (NPV) of CT detection of liver injuries were 75% , 90%, 50% & 97% respectively and 50%, 86%,43% & 89% for splenic injuries respectively in 16 cases of abdominal solid organs injuries.⁹

In 2008, a study using both PMCT and post mortem magnetic resonance imaging (MRI) in 34 cases of road traffic accident fatality found that CT alone has sensitivity of 53% and specificity of 84% for liver injury while for splenic injuries, the value is 33% and 93% respectively. This study also noted that the sensitivity and specificity was higher in the higher grade injuries.¹⁰ No local data available so far in this area.

The objectives of the study are:

1. To determine the sensitivity, specificity, PPV and NPV of PMCT and gross autopsy (gold standard) in detecting liver and splenic injuries due to road traffic accidents.
2. To determine the association between lower ribs fractures and the underlying solid organ injuries by PMCT findings.

MATERIALS AND METHODS

This was a retrospective cross-sectional study. The total number of sample in this study was based on the number of brought in dead bodies of motor vehicle accident ordered for post-mortem examination by the police department. The bodies then underwent PMCT prior to conventional internal autopsy. Decomposed bodies were excluded.

All cases were registered and were put inside body bag prior to PMCT. The body was scanned by a trained radiographer using Toshiba Aquillon 64 multislices machine. PMCT was conducted using two blocks CT for whole body:

For the head and neck block:

Head: conventional scan mode, 120 kV, 250 mA, 1 sec/rotation, and 8 mm collimation.

Neck: helical scan mode, 120 kV, 200–450 mA, 0.75 sec/rotation, and 5 mm collimation.

For the body block (thorax, abdomen, pelvis, and lower limbs): helical scan mode, 120 kV, 200–400 mA, 0.5 sec/rotation, and 5 mm collimation (cardiac: 2 mm collimation).

The digital images were processed using Toshiba software and stored into Infiniti PAC system.

Complete conventional internal autopsy was performed after PMCT scan by forensic pathologist in accordance to the standard practice of our department of Forensic Medicine. Reports on autopsy findings were recorded.

Comparison:

The conventional autopsy and CT images were performed and reported by a specific forensic pathologist and radiologist respectively, who were blinded to each other reports. The same forensic pathologist and radiologist reported all the cases in this study. The findings were recorded in terms of subcapsular haematoma, parenchymal laceration, organ rupture, avulsion, perihepatic or perisplenic haematoma and free fluid for both liver and spleen. Additional finding of lower ribs fracture was recorded for CT scan. Lower ribs fracture was defined as fracture of 6th to 12th ribs either right, left or both sides. Additional finding of fatal injury causing death was recorded for conventional autopsy.

The findings of both radiological and gross autopsy reports were documented in a table and compared. Taking the findings of gross autopsy as the gold standard, data was then put in a 2 x 2 table to determine the sensitivity, specificity, PPV and NPV for PMCT scan in terms of liver and splenic injuries respectively.

Comparison was made between lower ribs fracture detected by PMCT scan and associated underlying liver or splenic injury discovered on internal autopsy. Comparison was also made between positive post mortem finding and cause of death as diagnosed by conventional autopsy.

All the data were entered into the Microsoft Excel software. Data was analysed using Microsoft Excel statistical analysis tools. Continuous data were presented as mean (\pm SD) and median (range) for not normally distributed variables. Categorical variables were presented as number and percentage. Continuous variables were analysed using the Student t test according to data distribution. Categorical variables were analysed using contingency tables analysis (Fisher's exact test). A p value less than 0.05 were considered statistically significant ($p < 0.05$).

This study also received ethical approval from the ethical committee in the hospital where this study was conducted.

RESULTS

A total of 61 death cases due to road traffic accident occurred were analysed. A total of 57 male and 4 female bodies underwent CT scan prior to conventional autopsy. The cases in our study involved multiracial origin reflecting the population distribution. The demographic data were summarised in Table I. The final results of the study were summarised in Table II, Table III, Table IV, Table V and table VI.

There was no significant association (p value = 0.17) between right lower ribs fracture detected using PMCT scan and underlying liver injury discovered on internal autopsy. In contrast, there was extremely strong association between left lower ribs fracture detected using PMCT scan and underlying

The sensitivity, specificity and predictive values of post mortem computed tomography in detecting liver and splenic injury

Table I: Demographic data of cases of brought in dead bodies that underwent both post mortem CT scan and conventional autopsy at Hospital Kuala Lumpur from July 2011 to April 2012

	Number of patients; (n: 61)	Percentage (%)
Gender		
Male	57	93
Female	4	7
Ethnic		
Malay	23	38
Chinese	15	25
Indian	13	21
Non Malaysian citizen	9	15
Unknown	1	2
Age group		
10-19	5	8
20-29	22	36
30-39	15	25
40-49	9	15
50-59	3	5
60-69	6	10
Unknown	1	2

Table II: Cases of liver and splenic injuries in this study (PMCT and conventional autopsy)

	Number of patients; (n)	Percentage (%)
Total cases		
Cases presented with liver and/or splenic injuries	29	48
Cases presented with normal liver and spleen	32	52
Liver injury only	14	23
Splenic injury only	8	13
Both liver and splenic injuries	7	11
Both liver and splenic normal	32	52

Table III: Result of PMCT in detecting liver injury using internal autopsy finding as gold standard

	Number of patients; (n)	Percentage (%)
True positive	15	25
True negative	33	54
False positive	7	11
False negative	6	11
Sensitivity	15/21	71
Specificity	33/40	82
Positive predictive value	15/22	68
Negative predictive value	33/39	85
Overall accuracy	48/61	79

Table IV: Result of PMCT in detecting splenic injury using internal autopsy finding as gold standard

	Number of patients; (n)	Percentage (%)
True positive	11	18
True negative	37	61
False positive	9	15
False negative	4	7
Sensitivity	11/15	73
Specificity	37/46	80
Positive predictive value	11/20	55
Negative predictive value	37/41	90
Overall accuracy	48/61	79

Table V: Pattern of lower ribs fracture detected by PMCT and association with underlying solid organs injuries

	Number of patients; (n)	Percentage (%)
No rib fracture	30	49
Right lower ribs fracture only	10	16
Left lower ribs fracture only	7	12
Bilateral lower ribs fracture	14	23
Right lower ribs fracture with underlying liver injury	11	18
Right lower ribs fracture with no liver injury	13	21
Liver injury without right lower ribs fracture	10	16
No liver injury and no right lower ribs fracture	27	44
Left lower ribs fracture with underlying splenic injury	11	18
Left lower ribs fracture with no splenic injury	10	16
Splenic injury without left lower ribs fracture	4	7
No splenic injury and no left lower ribs fracture	36	59

Table VI: Fatal injury pattern or cause of death

	Number of patients; (n)	Percentage (%)
Head and neck injury	25	41
Thoracic injury	11	18
Abdominal and pelvis injury	3	5
Multiple injuries (Head/thorax/abdomen)	16	26
Others	4	7
Not recorded	2	6
Total intra-abdominal fatal injury (Included multiple injuries)	15	25

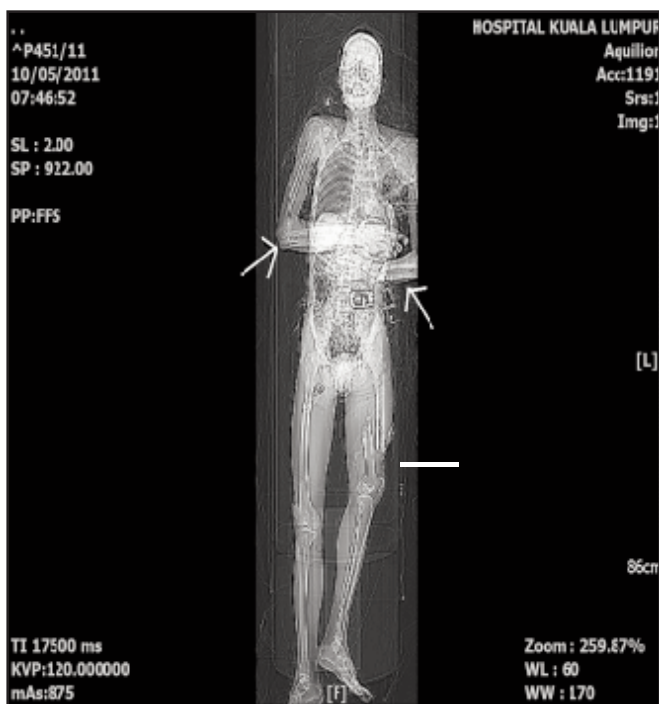


Fig. 1a: Topogram in coronal view showing standard body positioning during post mortem CT scan. Note the position of upper limbs (white arrow) which caused streak artefacts to the liver and spleen from hands and forearms bones.

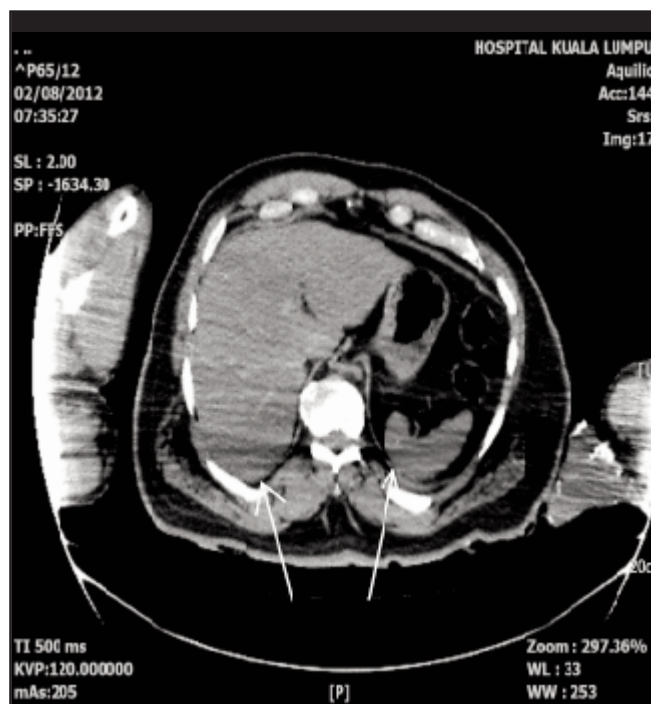


Fig. 1b: Axial view of post mortem plain CT scan of the same patient in Figure 1 (A). Note the linear hypodensity (white arrow) across liver and spleen representing streak artefacts from hands and forearms bones. This artefact can be confused with laceration.

splenic injury discovered on internal autopsy (p value = 0.0005). There was statistically significant association between positive liver or splenic post mortem finding and intra-abdominal cause of death diagnosed by conventional autopsy (p value = 0.0357).

DISCUSSION

The use of PMCT is relatively new. A lot of studies are needed to validate its usage and uncover its limitation and potential. In our study, the sensitivity, specificity, PPV and NPV of PMCT in detecting liver and splenic injuries were 71%, 82%, 68% & 85% and 73%, 80%, 55% and 90% respectively. The overall

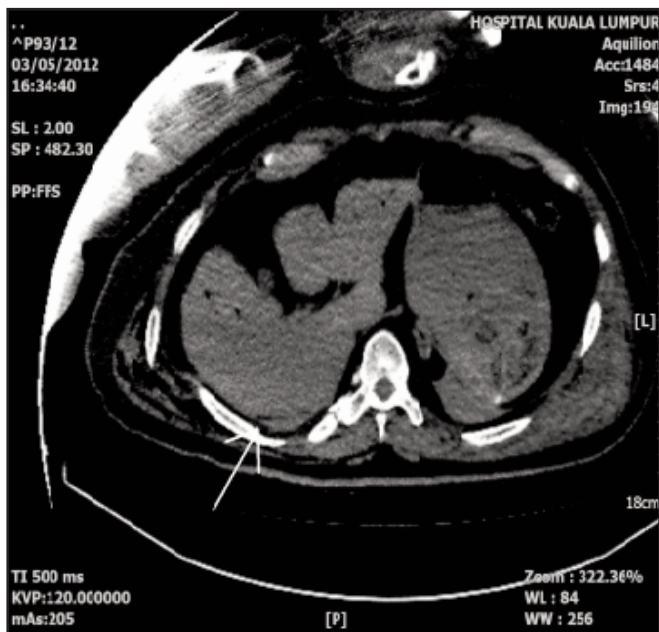


Fig. 2a: Axial view of plain post mortem CT scan of showing laceration at the posterior margin of right liver (arrow).

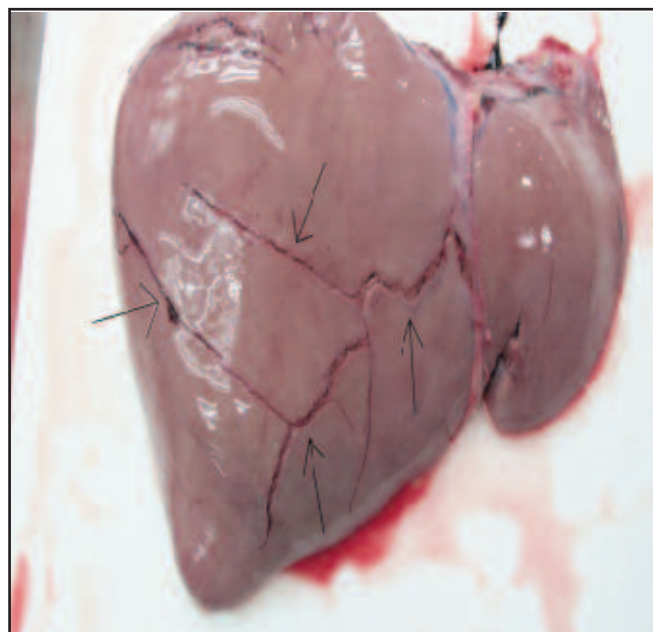


Fig. 2b: Internal conventional autopsy of the same patient in Figure 2 (A) showed multiple liver lacerations (arrow). True positive finding.

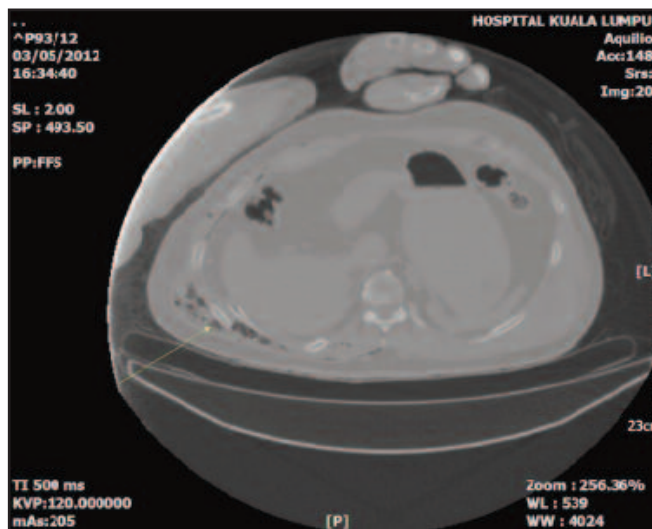


Fig. 2c: Axial view of plain post mortem CT scan of same patient in Figure 2 (A) in bone window showing associated lower rib fracture (arrow). Demonstration of bony fracture was an advantage of post mortem CT as compared to conventional autopsy.

accuracy of PMCT in detecting liver and splenic injuries was 79%.

In 2007, a study comparing PMCT scan and conventional autopsy showed that PMCT scan has the sensitivity, specificity, PPV and NPV of 75%, 90%, 50% & 96% and 50%, 86%, 43% and 89% respectively in detecting liver and splenic injuries in traumatic death.⁹ Even though the study in 2007 used larger sample size as compared to our study, our study has larger number of liver and splenic injuries. This was because the inclusion criteria used. Our study included only road traffic accidental deaths while the study in 2007 included all traumatic deaths. This was the reason why our

study had higher percentage of liver and splenic injuries as compared to their study. Our study showed comparable sensitivity (71% vs. 75%) for liver injury detection and NPV for splenic injury (90% vs. 89%) as compared to study done in 2007. Our study has better PPV for liver injury (68% vs. 50%), better sensitivity and PPV for splenic injury (73% vs. 50% & 55% vs. 43% respectively) but lower specificity and PPV for liver injury (82% vs. 90% & 85% vs. 96%) as well as specificity for splenic injury (80% vs. 86%) compared to study done in 2007. These differences were mainly due to large difference in the sample size.

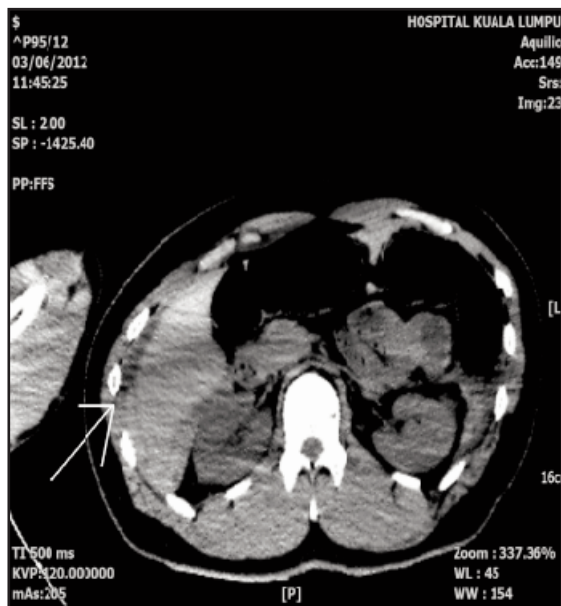


Fig. 3a: Axial view of plain post mortem CT scan of a patient showing perihepatic haematoma (arrow) at the inferior margin of the right liver. Some parts of the liver margin lost its smooth delineation and were irregular.

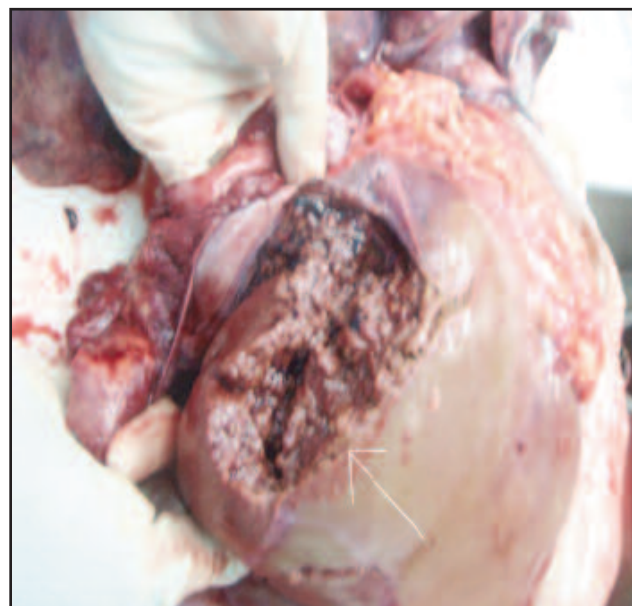


Fig. 3b: Internal conventional autopsy of the same patient in Figure 3 (A) showed liver rupture (arrow) at the inferior margin of the right liver. True positive finding.

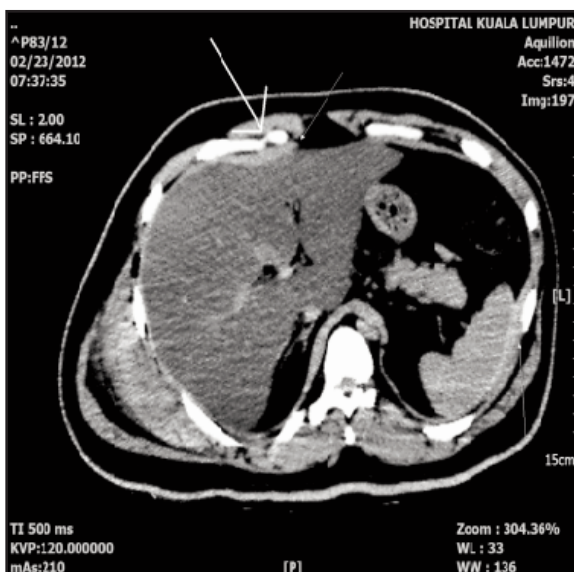


Fig. 4: Axial view of plain PMCT scan of a patient showing hyperdense perihepatic and perisplenic haematomas (thin arrows). Right lower rib fracture (thick arrow) detected. CT diagnosis of liver and splenic injuries was made. Subsequent internal conventional autopsy showed the liver and spleen were normal, a false positive finding.

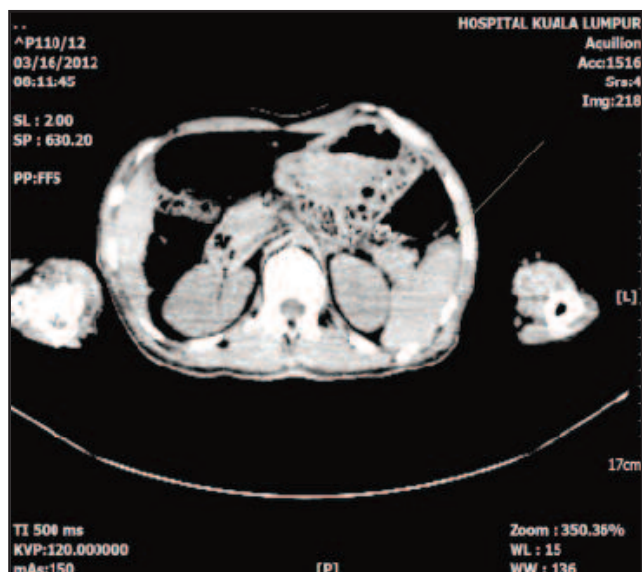


Fig. 5: Axial view of plain post mortem CT scan of a patient showing hypodense perisplenic haematomas (thin arrow). CT diagnosis of liver and splenic injuries was made. Subsequent internal conventional autopsy showed the liver and spleen were normal, a false positive finding.

The sensitivity of PMCT was not high enough to enable CT finding to be used as the only examination in detecting liver and splenic injuries (71% and 73%). Conventional autopsy still needed for accurate diagnosis and injuries description. The overall accuracy of PMCT in detecting liver and splenic injuries at 79% was inadequate for CT findings to be used alone in the court of law.

The specificity and negative predictive value of PMCT in detecting liver and splenic injuries were 82% & 85% and 80% & 90% respectively. These values were reasonably high and together with statistically significant correlation between positive liver/spleen PMCT finding and intra-abdominal fatal injury (Two tailed P value = 0.0357), there was potential for PMCT to be used as a decision making tool for performing or

not performing internal abdominal autopsy in selected cases, taking into account other organ findings, presence of bony injuries and detection of obvious cause of death from PMCT images and the level of accuracy needed for medico-legal reason. However further study was needed for this purpose.

CT scan was superior to conventional autopsy in detecting bony injuries. Together with its ability for evidence storage and 3D visualisation, PMCT imaging has incomparable advantage over the conventional autopsy. In our study, 51% of the cases (n=31) presented with lower ribs fracture. In 2006, a study on autopsy cases of liver blunt trauma done in India showed 54% out of 61 liver blunt trauma cases has ribs fracture. Our study showed almost similar figure of 52% (11 out of 21 cases).

The presence of right lower ribs fracture was not statistically associated with liver injury (p=0.17) while the presence of left lower ribs fracture was strongly associated with splenic injury (p=0.005). These findings can be explained by the differences in these organs sizes. Liver, being much larger than spleen, was easily injured without the need for high impact trauma as represented by ribs fracture. These findings were helpful for radiologist in making diagnosis in difficult cases.

Incorporating PMCT scan into current practice did not result in delay or disruption in performing conventional internal autopsy or delay in releasing the body for burial. All scans were completed within 20 minutes. In a forensic facility in which dedicated CT machine is available, additional PMCT did not cause any disadvantage in term of time and convenience. However, cost effectiveness of PMCT was beyond the scope of this study.

There were a few limitations in this study:

1. *Severe artefact*: Due to post mortem body positioning during CT scan, in which the forearms were placed anteriorly at the upper abdomen (Figure 1), there was severe streak artefacts from the bones of the upper limbs. The body positioning was mainly due to cultural reasons rather than a technical requirement for CT scanning. The region most affected by the artefacts was the upper abdomen where the liver and spleen are located. We had difficulties in interpreting CT images of the liver and spleen due to this artefact. Approximately 75 % of our cases were significantly affected by this problem. This limitation may be reduced by changing the standard body positioning during CT scan or having special post processing artefact correction incorporated in the PMCT protocol.

2. *Lack of experience*: PMCT is new in our country; therefore, experience in interpreting PMCT images is limited. We have only one dedicated radiologist with limited experience doing post mortem work, therefore we were unable to conduct this study using 2 experienced radiologists to interpret the images. We have more false positive results than false negative results, a total of 16 false positives as compared to

10 false negative cases. False positive results represent over diagnosis. While false negative results were expected due to difficulty in detecting minor injury in plain CT, false positive results can be improved with further formal training and experience. In time, with more experience and formal training, the result may improve. Despite this, our study results were comparable to other previous studies in this area.

3. *Number of usable cases*: There were 84 road accidental death cases during the study period. However, only 61 cases were usable for this study. The reasons for unusable data included incomplete CT scan, PMCT not done, CT scan images not retrievable due to technical problem, incomplete autopsy and autopsy report not yet completed by the time data analysis made. A bigger sample size will make this study more statistically significant.

CONCLUSION

In conclusion, PMCT scan has reasonably high specificity and NPV for liver and splenic injuries; however the sensitivity and PPV were low. The overall accuracy was not high enough to enable PMCT to be used as a replacement for conventional autopsy. PMCT was a useful complementary examination and has potential to be used as decision making tool for selective internal autopsy. More studies are required for this purpose.

REFERENCES

1. Brogdon BG. Forensic radiology. CRC Press, 1998.
2. Wüllenweber R, Schneider V, Grumme T. [A computer-tomographical examination of cranial bullet wounds (author's transl)]. *Z Rechtsmed* 1997; 80: 227-46.
3. NST Computime, 15 Nov 2005.
4. Royal Malaysian Police, Traffic Division, Bukit Aman. Annual Road Accident Statistic. Kuala Lumpur. 2007.
5. Rose JS, Levitt MA, Porter J, Hutson A, Greenholtz J, Nobay F, et al. Does the presence of ultrasound really affect CT scan use? A prospective randomized trial of ultrasound in trauma. *J Trauma* 2001; 51(3): 545-50.
6. Yao DC, Jeffrey RB Jr, Mirvis SE, Weekes A, Federle MP, Kim C, et al. Using contrast-enhanced helical CT to visualize arterial extravasations after blunt abdominal trauma: incidence and organ distribution. *AJR Am J Roentgenol* 2002; 178(1): 17-20.
7. Kelly J, Raptopoulos V, Davidoff A, Waite R, Norton P. The value of non-contrast-enhanced CT in blunt abdominal trauma. *AJR Am J Roentgenol* 1989; 152(1): 41-8.
8. Petridis A, Pilavaki M, Vafiadis E, Palladas P, Finitis S, Drevelegas A. CT of hemodynamically unstable abdominal trauma. *Eur Radiol* 1999; 9(2): 250-5.
9. Monila DK, Nicholas JJ, Dimaio VJ. The sensitivity of CT scans in detecting trauma: are CT scans reliable enough for courtroom testimony? *J Trauma* 2007; 63(3): 625-9.
10. Christe A, Ross S, Oesterhelweg L, Spendlove D, Bolliger S, Vock P, et al. Abdominal trauma- Sensitivity and specificity of postmortem noncontrast imaging findings compared with autopsy findings. *J Trauma* 2009; 66(5): 1302-7.
11. Devi TM, Nabachandra H, Singh TS. Blunt Hepatic Trauma: A study. *Medico-Legal Update* 2006; 6(3): 73-6.
12. Salimi J, Bakhtavar K, Solimani, M, Khashayar P, Meysamie AP, Zargar M. Diagnostic accuracy of CT scan in abdominal blunt trauma. *Chin J Traumatol* 2009; 12(2): 67-70.