

Barlow's Repair: Light in the Dark Tunnel: A Case Report Could Omit' Light in A Dark Tunnel'

Mohd Alkaf Ab Latip, MBBS*, Simon Vendargon, MSurg*, Taweesak Chotivatanapong, FRCS, Abdul Rahman I, MSurg***

*Department of Cardiothoracic Surgery, Hospital Sultanah Aminah Johor Bahru (HSAJB), Jalan Persiaran Abu Bakar, 80100 Johor Bahru, Johor, Malaysia, ** Central Chest Institute of Thailand, Department of Cardiothoracic Surgery, Nonthaburi, 11000 Thailand

SUMMARY

Barlow's disease has a complex pathology requiring reconstructive surgery. Despite the complicated surgery it holds a positive outcome. We report a successful case of Barlow's disease who underwent mitral valve reconstructive surgery at our centre. Post-operative echocardiography shows a well-functioning repaired mitral valve without significant mitral regurgitation.

KEY WORDS:

Barlow's disease, mitral valve prolapse

INTRODUCTION

Barlow's disease causes the most complicated and mysterious form of mitral regurgitation (MR) in degenerative mitral valve disease. It was first demonstrated by Barlow in 1966 through cine-ventriculography.¹ Carpentier and colleagues described the surgical lesions in Barlow's disease which is used as a reference now. The term Barlow's disease is used interchangeably with mitral valve prolapse syndrome, click-murmur syndrome or myxomatous valve disease.

CASE REPORT

A-63 year old gentleman presented with reduced effort tolerance and palpitation. Physical examination showed pan-systolic murmur which best heard at the apex located at 6th left intercostal space in the anterior axillary line. The heart rate was in irregular rhythm, corresponding with atrial fibrillation (AFib) showed in electrocardiogram. Chest radiography showed pulmonary edema features. He was clinically in New York Heart Association (NYHA) functional class I. He also noted to have hypertension.

Following admission, the transthoracic echocardiography (TTE) showed severe mitral regurgitation (MR) with moderate to severe tricuspid regurgitation (TR). The anterior mitral valve leaflet (AMVL) was prolapsed. Upon that time, he was opted for medical treatment. Two years later, he had worsening effort tolerance associated with orthopnea and lethargy (NYHA II). Transesophageal echocardiography (TEE) revealed prolapsed A2, A3 and P3 segments with ruptured A2 chord. The mitral valve annulus was dilated. The severe TR was found pathologically insignificant.

Intra-operative TEE confirmed the findings.

Cardiopulmonary bypass was established with bicaval cannulation. The patient was cooled to 28 degrees centigrade. The mitral valve was visualised via the transeptal approach. Intra-operative findings showed Carpentier type II prolapse of A2, A3 and P3 with excessive redundant tissue of A3 and P3 segments. The A2 chord was found ruptured while the A3 chord elongated. Goretex 5/0 suture was used to create a new chord for A2 and A3. Meanwhile the redundant tissue at A3 and P3 were plicated to the adjacent annulus by a conventional sliding and folding plasty technique with Prolene 5/0. The anterior mitral valve leaflet was measured and a size 40mm, Physio II annuloplasty ring used to support the annulus. The intraoperative water test on the reconstructed valve showed a competent valve.

Repeat TTE on post-operative day 5 showed trivial MR with good left ventricular function. There was a small posterior pericardial effusion which was treated conservatively. He was in controlled AFib. He was discharged home after stabilization of the international normalisation ratio (INR). One year post surgery, TTE shows a well-functioning mitral valve without significant residual MR.

DISCUSSION

Barlow's disease is a subset of degenerative mitral valve disease. It is believed that Barlow's disease has a genetic or familial component, making it among the commonest cause of degenerative mitral valve disease after fibroelastic deficiency. The thickened redundant leaflets occur as a result of myxoid infiltration which is abnormal connective tissue altering the leaflet architecture. The mechanism of mitral valve regurgitation in Barlow's disease is a consequence of prolapsed leaflets secondary to chordae elongation or rupture, involving multiple segments which is seen in our case. Carpentier and colleagues described the typical surgical features of Barlow's disease where there is a thickened leaflet, large redundant scallops, chordal elongation or rupture with annular dilatation.²

Multiple techniques are used in reconstructing the billowing mitral valve. David and colleagues advocate the use of a large annuloplasty ring up to size 40mm to minimize the risk of systolic anterior motion (SAM) and left ventricular outflow

This article was accepted: 1 April 2015

Corresponding Author: Mohd Alkaf Ab Latip, Department of Cardiothoracic Surgery, Hospital Sultanah Aminah Johor Bahru (HSAJB), Persiaran Abu Bakar Sultan, 80100 Johor Bahru, Johor, Malaysia Email: alkaf334@yahoo.com

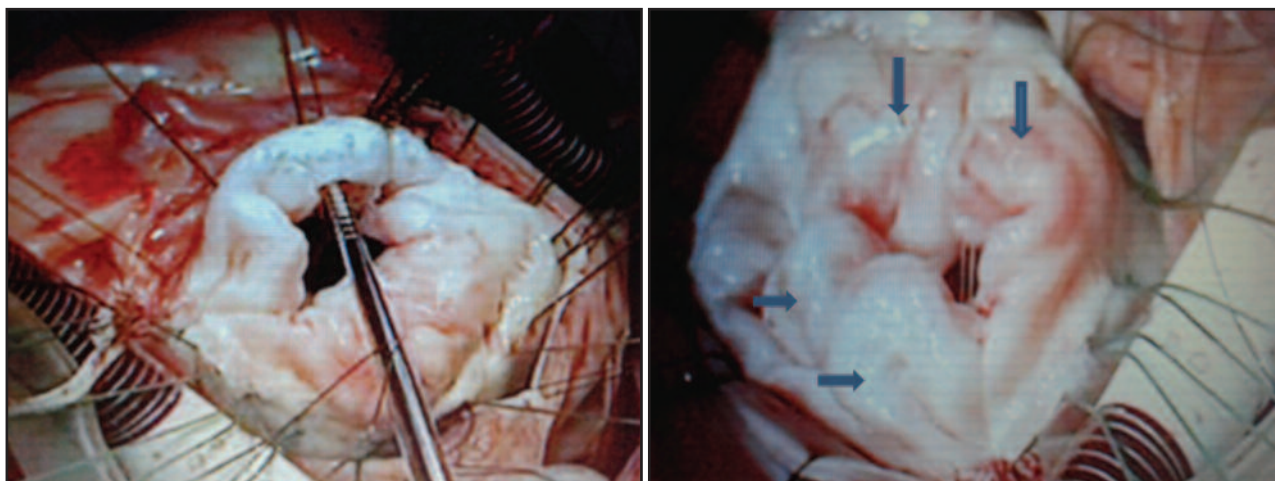


Fig. 1: The intra-operative findings seen from the surgeon's view: Billowing of the posterior and anterior leaflets of the mitral valve. It shows the A2 and A3 scallops are grossly redundant (vertical arrow). The P2 and P3 are also looked bulky and thick (transverse arrow).

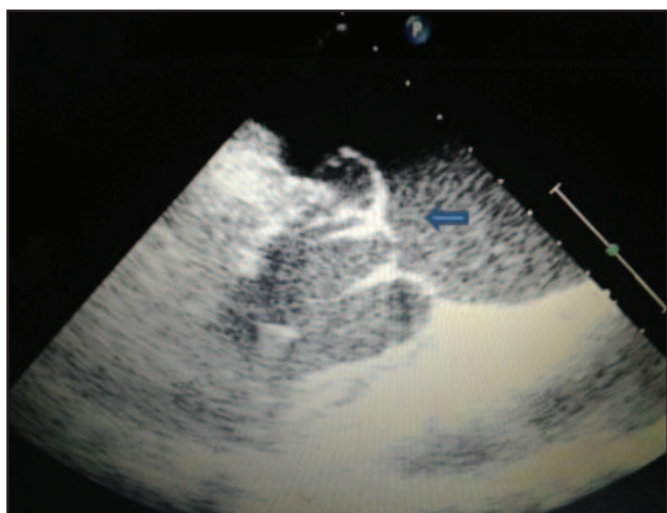

Fig. 2: The trans-thoracic echocardiography in short-axis view showed a mitral valve prolapsed with thickened and billowing leaflet above the plane of annulus (transverse arrow). The chords are elongated.

tract obstruction.³ He also emphasizes this technique as an important adjunct to establish repair techniques in a patient with a large annulus and excessive leaflet tissue, as seen in our case.

Mitral valve repair is synonymous with high risk of reoperation and other various complications. Repair of Barlow disease provides a very promising outcome. A short term follow-up post Barlow repair in 2 years showed 93% survived with NYHA functional class I or II. Long-term survival 10 years after repair shows an excellent outcome with 80.1% survival rate and freedom from reoperation is 94.4% in a study involving 348 patients undergoing mitral valve repair of Barlow disease.⁴ The recurrence rate of mitral regurgitation remains between 2% -3% a year which is probably related to the aging process.

CONCLUSION

Barlow's disease is repairable with an excellent outcome. The advanced in mitral valve reconstructive surgery specifically changed the perception to have good quality of life after surgery for many years to come.

ACKNOWLEDGEMENT

I would like to express my gratitude to the Director General of Health for giving us permission to write this case report by using the infrastructure of the Ministry of Health. I also would like to thank Sister Ramah of CICU, Sister Salinder of COT and Sister Lee of CTK as well as our Cardiothoracic Surgery staff for their kind assistance and contribution in completing this case report.

REFERENCES

1. Barlow JB, Pocock WA, Marchand P, Denny M. The significant of late systolic murmurs. *Am Heart J* 1963; 66: 443-452.
2. Carpentier A, Chauvaud S, Fabiani JN, *et al.* Reconstructive surgery of mitral valve incompetence: ten-year appraisal. *J Thorac Cardiovasc Surg* 1980; 79:338-48.
3. David H Adams, Ani C Anyanwu, Parwis B Rahmanian, Vivian Abascal, Sacha P Salzberg and Farzan Filsoufi. Large annuloplasty rings facilitate mitral valve repair in barlow's disease. *Ann Thorac Surg* 2006; 82:2096-101
4. Willem Flaming, Bart Meuris, Paul Herigers, Marie-Christine Herregods. Durability of mitral valve repair in barlow disease versus fibroelastic deficiency. *J thorac Cardiovasc Surg* 2008; 135: 274-282