

Posterior Intraorbital Metallic Foreign Body : A Case Discussion

Vinodh Vayara Perumall, MD, Pulivendhan Sellamuthu, MBBS, FRCS (Surgical Neurology) Edin, Rahmat Harun @ Haron, MBChB, MS (Neurosurgery), Mohd Sofan Zenian, MBBS, MS (Neurosurgery)

Hospital Queen Elizabeth 2, Department Of Neurosurgery, Level 8, Jalan Bersatu, Off Jalan Damai, Kota Kinabalu, Sabah 88300, Malaysia

SUMMARY

Intraorbital foreign body (IOFB) has been a rare phenomenon in the cases of gunshot wounds and always represents a dilemma in medical management. In Sabah, this scenario is becoming common as there is still certain population in the interiors who owns self made guns for hunting. They either present with self inflicted gunshot injuries or after being mistakenly shot while hunting. There are very few articles on this topic especially when it is located posteriorly in the orbit and occurs without visual impairment. This case reports the challenges faced in the management of the patient with a posteriorly located metallic IOFB. The appropriate management of the patient is discussed based on several international literatures. Author describes a 37 years old male farmer, who was referred from a nearby district hospital after he sustained gunshot injuries to his face and scalp. Urgent computed tomography (CT) scan showed that bullet pellets were at the left orbital floor, the left mandible and the left frontal bone. All bullet pellets were located extracranially only without intracranial involvement. Patient clinically does not have any neurologic deficit and without any visual impairment, thus he refused any surgical intervention. As there is no proper guideline in managing such cases, decision was made based on evidences from international literatures. It was concluded that metallic IOFB located in the posterior orbit may be conservatively managed with observation and regular follow-ups as they are well-tolerated and does not cause much impact on visual deterioration unless inflammation, infection, optic neuropathy or functional deficit occurs. This avoids unnecessary surgery and prevents risk of iatrogenic injury to the eye.

KEY WORDS:

Intraorbital; metallic bullets; retained foreign body; management of intraorbital foreign body; gunshot injury; penetrating eye injury

CASE PRESENTATION

A 37 years old male farmer was referred from a nearby district hospital after he sustained gunshot injuries to his face and scalp. He was carrying a self-made gun when he accidentally slipped and fell, during which he accidentally pulled the trigger and fired the gun to his face.

At presentation to the hospital, he has no neurologic deficit of any form. There was minimal bleeding from the bullet entry sites which stopped upon compression. There was no other bleeding from the nose or ears. Patient was fully conscious and had no increased intracranial pressure symptoms. He had no visual deficit as well. His Glasgow Coma Scale (GCS) score was full.

On examination, 3 entry wounds noted on his face and scalp without any exit wounds. These entry wounds were located at the temple region, the forehead and the lower jaw. Examination of the oral cavity too revealed no exit wounds. His bilateral pupils were 3 millimeters equal and reactive with stable vital signs. He had no visual deficit and was formally assessed by the ophthalmology team as well. Visual acuity of bilateral eyes is 6/6 vision and bilateral visual fields are within normal limits as well. Examination of all the cranial nerves was intact. No further vascular tests were performed as everything else was unremarkable.

He was then transferred to the neurosurgical centre and urgent computed tomography (CT) scan was done which showed that all bullet pellets were located extracranially only without intracranial involvement.

Results of CT scan on cranial bone window shows bullet pellets at the left orbital floor (Fig. 1 and Fig. 2), the left mandible (Fig. 3) and the left frontal bone (Fig. 4).

He was conservatively treated for his intraorbital foreign body and he also refused operative intervention for his retained bullet pellets at mandible and frontal bone. He was treated with prophylactic course of cefuroxime for one week. He was then discharged home well and currently on regular follow-ups at our clinic without any complaints.

DISCUSSION

Intraorbital foreign body (IOFB) has been a rare phenomenon in the cases of gunshot wounds and always represents a dilemma in medical management. In Sabah, this scenario is becoming common as there is still certain population in the interiors who owns self made guns for hunting. They either present with self inflicted gunshot injuries or after being mistakenly shot by someone while

This article was accepted: 25 December 2013

Corresponding Author: Vinodh Vayara Perumall, Hospital Queen Elizabeth 2, Department Of Neurosurgery, Level 8, Jalan Bersatu, Off Jalan Damai, Kota Kinabalu, Sabah 88300, Malaysia Email: vinodhvayara@gmail.com

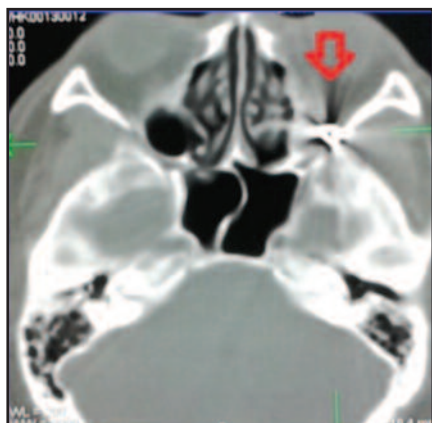


Fig. 1 : CT scan axial view of cranial bone window showing a bullet (red arrow) at the left orbital floor.

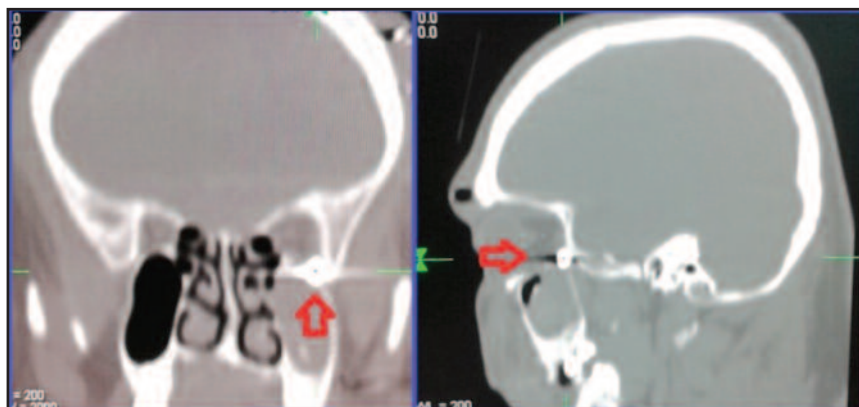


Fig. 2 : CT scan coronal and sagittal view of cranial bone window showing a bullet (red arrow) at the left orbital floor.

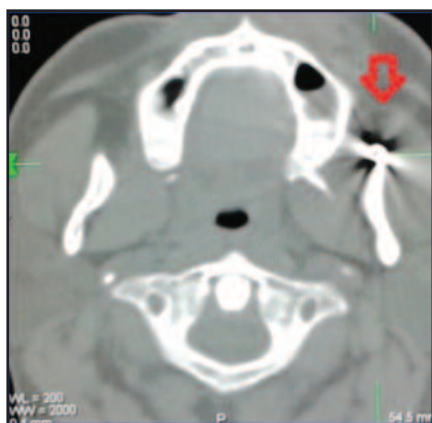

Fig. 3 : CT scan axial view of cranial bone window showing a bullet (red arrow) at the left mandible.

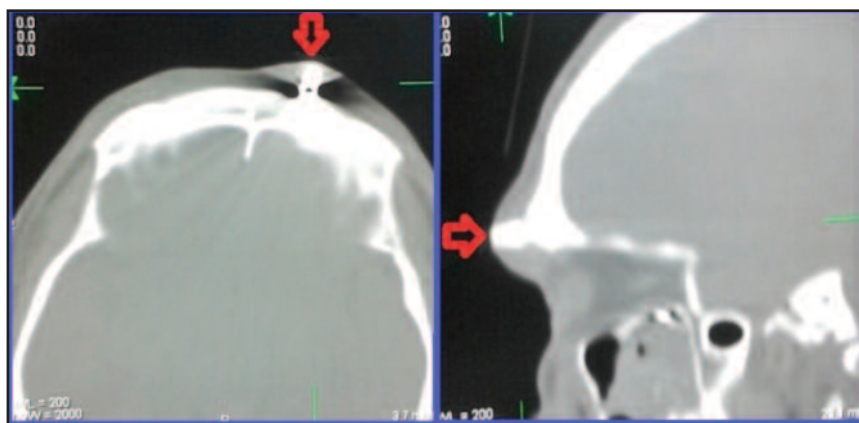


Fig. 4 : CT scan axial and sagittal view of cranial bone window showing a bullet (red arrow) at the left frontal bone.

hunting. There are very few articles on this topic especially when it is located posteriorly in the orbit.

In the study by Finkelstein *et al.* which was done retrospectively over a period of 7 years, they gathered a total of 27 patients with such injuries but all involving only metallic foreign bodies. Results of this study were that 13 projectiles were lodged anteriorly, 4 were in an epibulbar position, and the remaining 10 were posterior to the equator. Out of these, all except one of anterior and 8 of posterior positions were operated. It shows that 80percent of posteriorly positioned foreign bodies were not operated and safely left behind¹.

Another review of 40 patients seen at two regional orbital surgery departments with intraorbital foreign bodies was done by Fulcher *et al.* Out of them, 22 had metallic - inorganic; 5 had nonmetallic - inorganic; and 13 had organic intraorbital foreign bodies. All of them had surgery except for 6 patients as they had posteriorly located inorganic foreign

bodies. They concluded that posteriorly located inorganic IOFB should be treated conservatively unless it causes major orbital complications².

Ho *et al.* performed a retrospective review of 43 patients treated during a period of 6 years with retained intraorbital metallic foreign bodies. 37 patients had the metallic foreign bodies located posterior to the globe. Out of the 20 cases with no ocular involvement, only 2 patients had secondary complications that required surgical intervention. The metallic foreign bodies were retained from 6 months to 68 years with a median value of 2 years. There were no late complications from the retained foreign bodies in 95 percent of cases when the eye remained intact³.

Our final literature review was by Robert J. Peralta *et al.* which is about posterior intraorbital foreign body and the appropriate management of whether to remove it or leave it undisturbed. They summarized a pathway of approach towards patients which begins with complete full systemic

evaluation and to rule out an ophthalmologic emergency such as ruptured globe. It is also stated that empiric broad-spectrum antibiotics should be administered to all patients and then appropriate imaging can be obtained to help identifying the foreign body. All organic foreign bodies should be removed, although there is a paucity of data on those located in the posterior orbit. Inorganic foreign bodies on the other hand should be removed if located anteriorly and freely palpable. Non-palpable anterior, epibulbar and posterior foreign bodies can be managed conservatively given the risk of further damage during surgical extraction⁴.

CONCLUSION

Retained intraorbital metallic foreign bodies are well-tolerated and does not cause much impact on visual deterioration, thus they should be managed conservatively in the absence of specific indications for removal. So a metallic foreign body located deep in the posterior orbit may be only observed and given appropriate supportive care, thus avoiding potential iatrogenic injury to the eye and surrounding structures. All organic IOFB should be removed and all patients with IOFB should receive prophylactic broad spectrum antibiotics.

REFERENCES

1. Finkelstein M, Legmann A, Rubin PA *et al*. Projectile metallic foreign bodies in the orbit: a retrospective study of epidemiologic factors, management, and outcomes; *Ophthalmology* 1997 Jan; 104(1): 96-103.
2. Fulcher TP, McNab AA, Sullivan TJ *et al*. Clinical features and management of intraorbital foreign bodies; *Ophthalmology* 2002 Mar; 109(3): 494-500.
3. Ho VH, Wilson MW, Fleming JC, Haik BG *et al*. Retained intraorbital metallic foreign bodies; *Ophthal Plast Reconstr Surg*. 2004 May; 20(3): 232-6.
4. Robert JP, Christopher Z, Gary J.L. Jr *et al*. Posterior Intraorbital Foreign Body: Take it or Leave it?; *Open Reconstructive and Cosmetic Surgery* 2008, 1: 1-3 1