

# Emergency Lung-Sparing Surgical Repair of a Complete Transection of the Right Mainstem Bronchus due to Blunt Chest Trauma

**Anand Sachithanandan, FRCSI(CTh), Tan Yong Sheng, MBBS, Abdul Muis Jasid, MS, Rapi Abdul Rahman, MMed (Anaesthesia), Mohd Arif Mohd Noor, MS, Balaji Badmanaban, FRCSI(CTh), Mohd Hamzah Mohd Kamarulzaman, FRCS**

Hospital Serdang, Cardiothoracic Surgery, Jalan Puchong, Kajang, Selangor 43000, Malaysia

### SUMMARY

Traumatic chest injury with complete tracheo- bronchial disruption is uncommon and occurs in approximately 1 % of motor vehicle accidents (MVA) (1,2). Such injuries carry a high mortality and patients rarely survive transfer to hospital. A high index of suspicion facilitates early diagnosis. Early operative intervention is vital for survival. We describe a rare case of traumatic complete disruption of the right mainstem bronchus (RMB) due to blunt chest trauma. The transected airway was reanastomosed emergently avoiding a lung resection.

### INTRODUCTION

Traumatic chest injury with complete tracheo- bronchial disruption is uncommon and occurs in approximately 1 % of motor vehicle accidents (MVA) (1,2). Such injuries carry a high mortality and patients rarely survive transfer to hospital. A high index of suspicion facilitates early diagnosis. Early operative intervention is vital for survival. We describe a rare case of traumatic complete disruption of the right mainstem bronchus (RMB) due to blunt chest trauma. The transected airway was reanastomosed emergently avoiding a lung resection.

### CASE SUMMARY

A 28-year-old male drug abuser was a motorcyclist who allegedly collided into the back of a near-stationary car. On admission he was neurologically intact but haemodynamically unstable (GCS 15/15, blood Pressure 80/50 mmHg, heart rate 114/min) and tachypnoeic (respiratory rate 30/min). Pulse oxymetry showed hypoxia (SpO<sub>2</sub> 70-76%) on room air that failed to improve with supplemental oxygen. Auscultation revealed decreased air entry over the right chest. An intercostal chest drain (ICD) was promptly inserted with no improvement in oxygenation. A large and persistent air leak was noted from the ICD. A chest radiograph (Figure 1) revealed a fully collapsed right lung. A cardiothoracic opinion was sought and the patient was subsequently intubated with a double lumen endotracheal tube (ETT) to isolate the right lung and selectively ventilate the left. The air leak reduced and the

patient's saturations improved (SpO<sub>2</sub> 80-85 %). A computed tomography (CT) scan suggested a right sided major airway injury with chronic bronchiectatic changes in the left lower lobe (Figure 2).

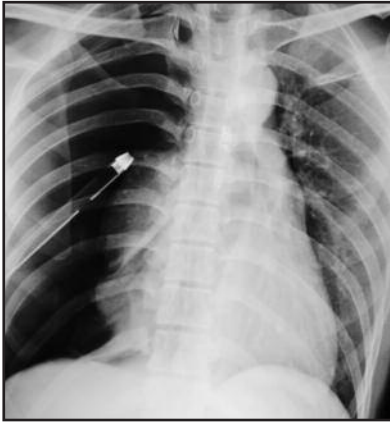On transfer to our facility the patient remained hypoxic (SpO<sub>2</sub> 75-85%) despite maximal ventilation. A pre-thoracotomy flexible bronchoscopy suggested a disrupted RMB as the pleural cavity could be directly visualized. At emergency thoracotomy, the right lung was found to be fully disconnected from the RMB and only held together only by the hilar pulmonary vessels (Figure 3). The azygous vein was ligated and divided to gain better exposure to the proximal RMB stump. The distal stump was debrided and following judicious mobilization of peribronchial tissues, an end to end bronchial re-anastomosis was performed with simple interrupted absorbable (4-0 Vicryl) sutures placed circumferentially. Prior to tying down the final anterior suture line, we repeatedly aspirated the right lung with direct suctioning of the distal airway. The transected ends of the azygous vein were loosely re-approximated to cover the anastomosis anteriorly. A concomitant upper lobe lung laceration was repaired with 4-0 prolene and two Teflon buttressing strips. Following thoracotomy closure, a repeat bronchoscopy revealed an intact airway and further secretions were aspirated.

The immediate and early post-operative CXRs (Figure 4) were highly satisfactory with a fully reinflated right lung and no residual air leak. The patient was extubated on the 3rd post-operative day (POD) but re-intubated 6 hours later for respiratory distress. Copious thick secretions were aspirated from the right lung. He remained intubated for a fortnight due to a multi-resistant acinetobacter pulmonary infection. His concomitant injuries; splenic and liver lacerations, a stable pelvic fracture and a fractured 2nd right rib and scapula were all treated conservatively. The ICDs were removed by the 5th POD in the absence of any air leak. He was re-extubated on the 14th POD with no neurological deficit. His biohazard screen confirmed positive serology for hepatitis C and syphilis and appropriate therapy commenced. The patient was discharged home a week later and remains well at early follow-up.

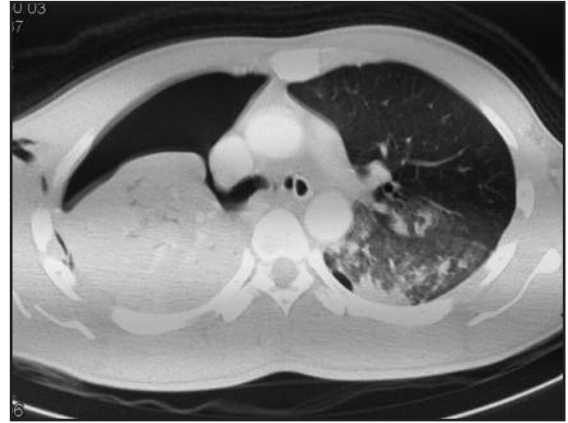*This article was accepted: 25 December 2013*

*Corresponding Author: Anand Sachithanandan, Hospital Serdang, Cardiothoracic Surgery, Jalan Puchong, Kajang, Selangor 43000, Malaysia*

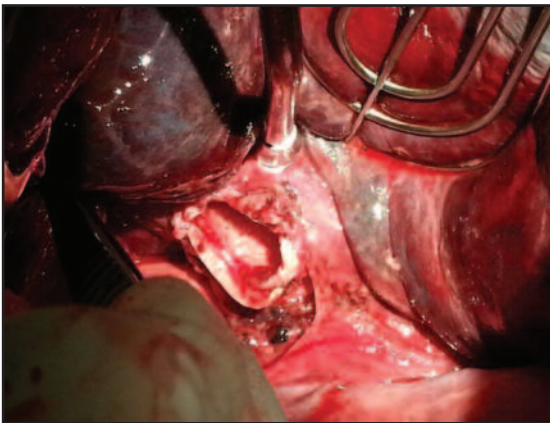
*Email: anandsachithanandan@yahoo.com*



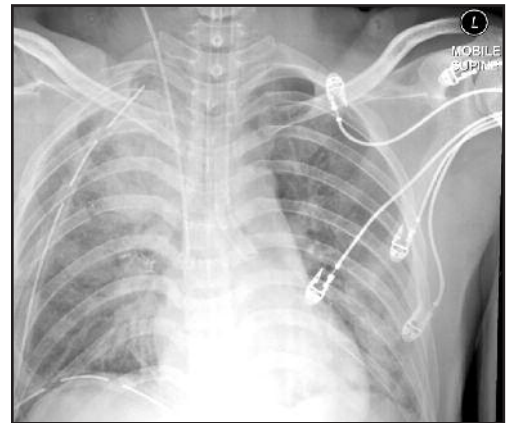
**Fig. 1 :** Chest radiograph which revealed a completely collapsed right lung.



**Fig. 2 :** Computed tomography scan demonstrating the 'fallen lung' sign suggestive of a major airway injury.



**Fig. 3 :** Intra-operative finding of a fully transected right main bronchus. The lung was held together at the hilum only by the major pulmonary vessels.



**Fig. 4 :** An early post-operative chest radiograph showing a fully reconnected and re-expanded right lung.

## DISCUSSION

Traumatic chest injury is one of the leading causes of death in a MVA. A major tracheo-bronchial injury is rare and seen in approximately 1% of chest trauma victims with few survivors to hospital<sup>1,2</sup>. A high velocity impact on the chest wall and the sudden rapid deceleration can lead to a tearing or shearing injury. Injuries may include multiple ribs fracture, a flail chest, haemopneumothorax, major thoracic vessel injury, pneumo or haemopericardium, oesophageal injury, cardiac contusion and cardiac tamponade. Immediate or early identification of such injuries can be truly life saving. The failure of the right lung to re-expand and no improvement in the oxygenation of our patient despite insertion of the ICD, coupled with a large and persistent air leak was highly suggestive of a major airway injury. The priority was to secure a patent and functioning airway to ventilate the patient, accomplished by inserting a left sided double lumen ETT. This however requires a trained anaesthesiologist. Alternatively a standard single lumen ETT can be used and passed selectively down the uninjured main bronchus although this is more difficult on the left. A CT scan will confirm the diagnosis with the characteristic 'fallen lung' sign<sup>3</sup>.

Early operative intervention is associated with the best outcome so as to minimize soiling of the ipsilateral pleural cavity and prevent bronchial stump necrosis. Division of the azygous vein can be done with impunity and provides excellent exposure and access to the proximal RMB. The surgeon must strive for a tension free anastomosis with minimal peribronchial dissection thereby preserving the blood supply. Covering the anastomosis with vascularized tissue such as the azygous vein enhances healing and minimises air leak or fistula formation. Similarly use of absorbable sutures reduces future granuloma, stricture or fistula formation<sup>4</sup>. Application of a glue or sealant is a useful adjunct and was prophylactically used here.

The extensive and deep nature of the upper lobe lung laceration precluded a simple excisional stapled wedge resection. We were not keen to perform a lobectomy in such circumstances hence a buttressed plication was performed to achieve haemopneumostasis. The surgeon must be vigilant of concomitant intra thoracic injuries that may not be initially apparent.

Post-operative care is vital for a good outcome and includes elective ventilation, regular chest physiotherapy, surveillance suction bronchoscopy and targeted anti-microbial therapy. The use of a double lumen tube and separate differential ventilation of the lungs can help minimize barotrauma on the airway anastomosis<sup>5</sup>.

#### CONCLUSION

We report a rare case of successful lung preserving surgical repair of a complete traumatic RMB transection. A high index of suspicion facilitates an early diagnosis. Securing a functioning airway is paramount and early judicious operative intervention may be life saving once the diagnosis is confirmed with appropriate imaging. Meticulous post-operative care and regular surveillance are vital for a durable and good outcome.

#### REFERENCES

1. Zarama V, Velasquez M. Mainstem bronchus transection after blunt chest trauma. *J Emerg Med* 2013 44(1):187-8.
2. Noda M, Matsumura Y, Hoshi F, Miyamoto A, Ishida I, Sado T, Hoshikawa Y, Endo C, Okada Y, Suzuki S, Kondo T. *Kyobu Geka*. 2006 Oct; 59(11): 990-5. Bronchoplasty without lung resection for the complete transection of the left main bronchus due to blunt trauma.
3. Wintermark M, Schnyder P, Wicky S. *Eur Radiol*. 2001; 11(3): 409-11. Blunt traumatic rupture of a mainstem bronchus: spiral CT demonstration of the "fallen lung" sign.
4. Chakaramakil MJ, Jim LY, Soon JL, Agasthian T. Continuous absorbable suture technique for tracheobronchial sleeve resections. *Asian Cardiovasc Thorac Ann*. 2011; 19(1): 44-7.
5. Katsaragakis S, Stamou KM, Androulakis G. Independent lung ventilation for asymmetrical chest trauma: effect on ventilatory and haemodynamic parameters. *Injury* 2005;36 (4): 501-4.