

ANCA-Associated Vasculitis - Revisited, and its Association with Autoimmune Thyroid Disease

J Y Lai, MRCP*, N H Nik Yahya, MPath**, S G Ong, FRCP*

*Department of Medicine, Kuala Lumpur Hospital, Jalan Pahang, 50586 Kuala Lumpur, **Department of Pathology, Kuala Lumpur Hospital, Jalan Pahang, 50586 Kuala Lumpur

SUMMARY

Antineutrophil cytoplasmic antibody (ANCA)-associated vasculitides (AAV) are a group of uncommon diseases. Given its rarity and multisystem clinical presentation which are usually serious and potentially fatal, prompt recognition and early treatment are of utmost importance. We report a case of AAV that presented with digital infarcts, cutaneous vasculitis, rapidly progressive glomerulonephritis, mononeuritis multiplex, eosinophilia and positive myeloperoxidase (MPO)-ANCA antibody. Apart from renal damage, there was complete recovery in other systems following intravenous cyclophosphamide and high-dose glucocorticoids albeit the response was delayed. This response obviates the need for second-line therapy with newer agent such as rituximab (anti-CD20 monoclonal antibody). We would also like to highlight that this is the first case of AAV that is associated with autoimmune thyroid disease to be reported from Malaysia.

INTRODUCTION

ANCA-associated vasculitides (AAV) comprise three syndromes with systemic vasculitis: Granulomatosis with polyangiitis (GPA – previously known as Wegener's granulomatosis), Churg-Strauss syndrome (CSS) and microscopic polyangiitis (MPA). Classification of AAV remains confusing because of unknown aetiology and considerable overlap in the clinical expression of the different vasculitic syndromes. The diagnosis of AAV is established based on clinical manifestations, biopsy of a relevant involved organ and the presence of ANCA. Even though the association between autoimmune thyroid disease and AAV is infrequent, this case shows that routine testing of thyroid function in cases of AAV who are otherwise asymptomatic for thyroid disease, is essential so as to avoid delayed diagnosis and treatment.

CLINICAL PRESENTATION

A 60 year-old gentleman with long-standing diabetes mellitus and hypertension presented to the vascular surgical department with a 1-month history of progressive numbness and weakness of both lower limbs. This was associated with dusky discolouration of both feet and a history of intermittent claudication. Dorsalis pedis and posterior tibial pulses in both lower limbs were absent. He was not a smoker and he denied consumption of any supplements or medications apart from his antihypertensive and antidiabetic drugs.

A provisional diagnosis of peripheral vascular disease was made and patient was treated with aspirin and subcutaneous fondaparinux. In the interim, Duplex scan of both lower limbs showed reduced blood flow in the right anterior tibial artery and absent blood flow distal to the left tibio-peroneal trunk. Electrocardiogram (ECG) was normal. Transthoracic echocardiography revealed normal cardiac chambers and valves, with good ejection fraction of 70%. CT angiography of the lower limbs was not pursued given the elevated serum creatinine of 199µmol/L.

Four days after admission, patient developed left wrist drop consistent with radial nerve palsy, and a rheumatology consult was made. The muscle power on wrist extension was of grade 0/5. Further history revealed he had constitutional symptoms of lethargy, anorexia and weight loss.

Physical examination revealed a medium built gentleman who appeared pale. His heart rate was regular at 80 beats per minute and cardiovascular examination was unremarkable. He had bilateral lower limb oedema and multiple purpuric lesions on his legs. By this time, he had developed gangrene over the pulps of the great and little toes on the right foot. Serum creatinine had risen to 315µmol/L.

Given the multisystem involvement, a provisional diagnosis of systemic vasculitis was made and extensive workup was performed, with particular attention paid to the possibilities of polyarteritis nodosa (PAN), granulomatosis with polyangiitis (GPA) and Churg-Strauss syndrome (CSS). There was no history of bronchial asthma, recurrent sinusitis or allergic rhinitis which are common manifestations of CSS. There was no history of oral ulcer, bloody nasal discharge, or abnormal lung radiograph to support GPA or MPA. He had not had any gastrointestinal symptoms or testicular pain to suggest PAN either.

Laboratory studies showed normochromic normocytic anaemia with Hb of 9.4g/dL, mean corpuscular volume of 88fL, platelet count of 216x10⁹/L, white cell count of 13.3x10⁹/L. Of note there was persistently raised eosinophil count (absolute count ranging from 0.9 to 1.2x10⁹/L). Stool for ova and cyst was however negative. Acute phase proteins were elevated with ESR of 85mm/hr and C-reactive protein (CRP) of 153.5mg/L (normal <5mg/L). Fasting serum lipids were normal. Whilst C3 was slightly low at 0.78g/L (0.82-1.85g/L), C4 was normal. Serologic test results were positive

This article was accepted: 27 February 2014

Corresponding Author: Swee Gaik Ong, Department of Medicine, Kuala Lumpur Hospital, Jalan Pahang, 50586 Kuala Lumpur, Malaysia

Email: ongsweeg@gmail.com

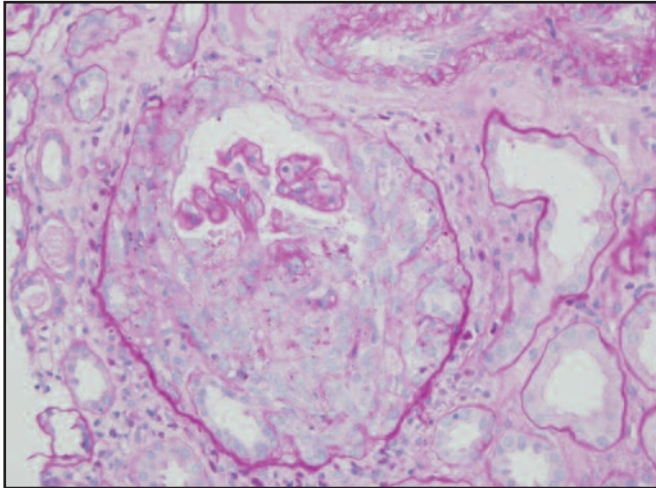


Fig. 1 : Renal biopsy showing a glomerulus with cellular crescent (PAS X 400).

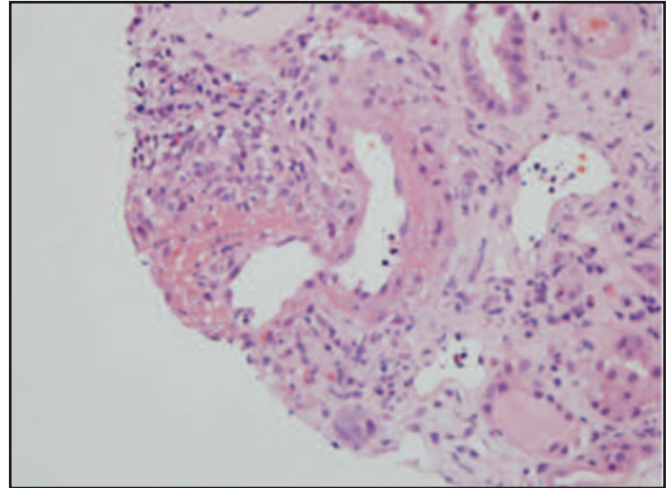


Fig. 2 : Renal biopsy showing active vasculitis with fibrinoid necrosis of the arterial wall (H&E X 200).

for myeloperoxidase (MPO)-ANCA however proteinase3 (PR3)-ANCA was negative. Antinuclear antibody (ANA) was nonreactive. Serum cryoglobulin was not detected. Thyroid function test revealed a low free thyroxine level of $<5.2\mu\text{g/dL}$ and elevated thyrotropin level of $>75\text{mIU/L}$. Antithyroglobulin and anti-microsomal antibodies were both positive, indicative of Hashimoto's thyroiditis. Serologies for HIV, Hepatitis B and C infections were negative. Tumour markers were within normal range. Blood and urine cultures were negative. Chest radiography was normal. Urinalysis showed active urine sediments with proteinuria and microscopic haematuria. Twenty four-hour urine protein showed significant proteinuria at 1.14g .

With the above findings of cutaneous vasculitis, mononeuritis multiplex, eosinophilia, raised ESR and CRP, active urine sediments with impaired renal function, and positive MPO-ANCA, a provisional diagnosis of ANCA-associated vasculitis (AAV) was considered. A tissue diagnosis was essential to clinch the diagnosis, hence renal biopsy was arranged. In the meantime, oliguric acute kidney injury ensued with further rise of serum creatinine to $447\mu\text{mol/L}$ and fluid overload, which necessitated 2 sessions of haemodialysis.

Renal biopsy showed pauci-immune focal active necrotizing and sclerosing glomerulonephritis with crescents and associated vasculitis. There was severe chronic tubulointerstitial damage. There was also patchy dense interstitial lymphocyte and plasma cell infiltration admixed with many eosinophils. No granuloma was noted and of note, there were no diabetic changes.

With that, a diagnosis of ANCA-associated vasculitis (AAV) was confirmed. As this condition was complicated with rapidly progressive glomerulonephritis and mononeuritis multiplex, both of which carried high morbidity, patient was then commenced on pulsed intravenous methylprednisolone of 500mg daily for 3 days followed by high dose oral

prednisolone of 1mg/kg/day , and pulsed intravenous cyclophosphamide 500mg every fortnightly.

Following 2 doses of IV cyclophosphamide, the eosinophil count, anaemia and raised inflammatory markers had normalised. There was also no proximal extension of digital gangrene. A review during the fourth dose of cyclophosphamide revealed that his renal function had improved somewhat with serum creatinine hovering around $250\mu\text{mol/l}$.

In the meantime, he was also treated for hypothyroidism with $50\mu\text{g}$ of L-thyroxine and he showed good response.

During the course of treatment, patient developed dendritic herpetic keratitis of the left eye and herpes zoster involving the left T4 dermatome as a consequence of immunosuppression. These infections were promptly treated, with good results.

Despite completion of 6 doses of cyclophosphamide, the left wrist drop persisted with muscle power of grade 3/5 on wrist extension. Nevertheless he was switched to Azathioprine as remission maintenance therapy with a decision for no further doses of cyclophosphamide. Electrodiagnostic studies at 8 months after his initial presentation showed chronic axonal neuropathy of the left radial nerve, associated with bilateral axonal sensorimotor polyneuropathy. During his follow-up visit at 12 months, there was partial recovery of the left radial nerve palsy with power of 4/5 on wrist extension. At 15 months, we were indeed very surprised and delighted to note that there was complete recovery of the nerve palsy. Indeed this case demonstrated that neurological recovery can occur with first-line therapy of cyclophosphamide and corticosteroids, albeit with some delay and there is no urgency to resort to biologic therapy even though the desired response was not apparent at the end of remission induction therapy.

DISCUSSION

Systemic vasculitis should be considered as a potential diagnosis in any patient presenting with multisystem disease. A high index of suspicion is important and it is prudent to exclude other conditions that may mimic ANCA-associated vasculitis (AAV), particularly infection and malignancy. The classification of AAV is based on the 2012 Revised International Chapel Hill Consensus Conference Nomenclature of Vasculitides¹. Our patient had overlap features of the different vasculitic syndromes and thus was labelled as AAV and not a specific vasculitic syndrome. Nevertheless current standard of care treatment remains similar and he received 6 doses of intravenous cyclophosphamide and high-dose glucocorticoids as remission induction therapy². This was followed by remission maintenance therapy with azathioprine. Even though there was no neurological improvement after induction therapy, the decision for additional therapy with Rituximab (anti-CD20 monoclonal antibody) was not considered given the fact that two randomized controlled trials, Rituximab for ANCA-associated Vasculitis (RAVE) and Randomised Trial of Rituximab versus Cyclophosphamide for ANCA-Associated Renal Vasculitis (RITUXVAS), failed to demonstrate significant superiority over cyclophosphamide as induction therapy³. Intravenous cyclophosphamide and glucocorticoids were efficacious as there was normalization of eosinophilia and inflammatory markers, arrest of digital gangrene, resolution of cutaneous vasculitis and notably, complete recovery of left radial nerve palsy albeit delayed after a 9-month interval.

With regard to our patient's renal function, he remained in stage 4 chronic kidney disease in spite of immunosuppressive therapy. This could be explained by the fact that he had aggressive glomerulonephritis which had already led to renal scarring and damage as demonstrated by chronic tubulointerstitial changes on biopsy. Though future progression of renal dysfunction is inevitable, we hope that it can be slowed down with maintenance therapy of azathioprine coupled with tight control of diabetes and hypertension.

The natural history of untreated AAV is of a rapidly progressive course and is often fatal. However with immunosuppressive therapy AAV follows a chronic relapsing-remitting time course with considerable morbidity and mortality. Our patient developed dendritic herpetic keratitis of the left eye and herpes zoster involving the left T4 dermatome while receiving therapy. Infections are well recognized adverse events related to immunosuppressive therapy and our patient was no exception. Most early deaths in the first year after diagnosis are due to infections and active vasculitis.

In general, the extent and number of organ involvement determine the prognosis of AAV. The 'five factor score' (FFS) developed by Guillevin *et al.*⁴ showed that poor prognosis was associated with age >50 years and the presence of cardiomyopathy, nephropathy (proteinuria >1g/L; creatinine >1.58mg/dL), gastrointestinal tract involvement and nervous system involvement. An FFS of ≥ 2 is associated with 53% mortality at 6 years compared with 14% in patients with an FFS of 0. Our patient had an FFS of 3 thus indicating a poorer prognosis.

Incidentally our patient had associated Hashimoto's thyroiditis. Literature search revealed that association between autoimmune thyroid disease and AAV has never been reported in Malaysia, thus making this the first case. Although many studies had proven an association between antithyroid drugs particularly propylthiouracil and AAV, whereby propylthiouracil induced the development of AAV, the link between autoimmune thyroid disease and AAV is still uncommon and not well established. Nevertheless, Tanaka *et al.* found that 4 cases out of a series of 10 with MPO-ANCA positive nephropathy had hypothyroidism, 2 of whom were subclinical⁵. Therefore we suggest that routine testing for thyroid function be done in all patients with AAV.

ACKNOWLEDGEMENT

We would like to thank the Director-General of Health Malaysia for giving us permission to publish this paper.

REFERENCES

1. Jennette JC, Falk RJ, Bacon PA, *et al.* 2012 Revised International Chapel Hill Consensus Conference Nomenclature of Vasculitides. *Arthritis & Rheum* 2013; 65(1): 1-11.
2. Mukhtyar C, Cuijlevin L, Cid MC, *et al.* EULAR recommendations for the management of primary small and medium vessel vasculitis. *Ann Rheum Dis* 2009;68:310-7.
3. Jayne D. Rituximab treatment for vasculitis. *Clin J Am Soc Nephrol* 2010(5): 1359-62.
4. Guillevin L, Lhote F, Gayraud M, *et al.* Prognostic factors in polyarteritis nodosa and Churg-Strauss syndrome: a prospective study in 342 patients. *Medicine (Baltimore)* 1996; 75(1): 17-28.
5. Tanaka A, Maeda K, Sawai K, *et al.* Concealed hypothyroidism in patients with myeloperoxidase antineutrophil cytoplasmic autoantibodies (MPO-ANCA) positive renal disease. *Clin Nephrol* 1999; 52(2): 91-5.