

Colonic and Small Bowel Metastasis From Ductal Carcinoma of The Breast : A Case Report

Visalini Sanmugachandran, MBBS Aimst, Daphne Anthonysamy, MD(UPM) MS(UKM), Mohamed Yusof Abdul Wahab, MD (USM) FRCS (Ed)

Department of General Surgery, Hospital Tengku Ampuan Rahimah, Jalan langat, 41200 Klang, Selangor

INTRODUCTION

Breast cancer is the most common neoplasm in women, accounting for approximately 32% of cancers in women, with a lifetime risk of 1 in 10. Because colon cancers are also common malignancies in most developed countries, the occurrence of colon cancer in patients with a history of breast cancer is not uncommon. However, colonic metastasis from a primary breast cancer is very rare¹. We report a case of colonic and small bowel metastasis from a ductal carcinoma of the breast six years after treatment of the disease. This example highlights the importance of considering metastatic breast cancer as a potential cause of gastrointestinal symptoms in a patient with a previous history of breast cancer.

CASE REPORT

Madam C is a 72 year old Chinese lady who presented to us in 2006 with Left Breast Cancer. She underwent a left mastectomy and axillary clearance soon after diagnosis and was well post operatively. The histopathological examination confirmed that the lesion was an Infiltrating Ductal Carcinoma (Grade 2), with no nodal involvement. Her Clinical staging was IIA (T2 N0 M0). Estrogen and progesterone receptors were positive, and CEB2 was negative. Staging CT scans showed no evidence of distance metastasis. In view of her age, she was not given adjuvant chemotherapy. She was started on Tamoxifen and has been on regular follow up with yearly mammograms since. She has no family history of malignancies.

She presented to us in 2012, with intestinal obstruction. CT abdomen done showed an irregular cecal mass with regional lymphadenopathy, and small bowel obstruction (Fig 1). There was also a well defined homogeneously enhancing stomach wall tumour mass in the lesser curvature suggestive of a GIST (Fig 2). She underwent a laparotomy, which revealed a polypoidal cecal tumour measuring 2 x 2cm, a small GIST tumour in the stomach measuring 1.5 x 2 cm, and a constricting lesion measuring 1 x 2 cm in the small bowel, 70cm from the terminal ileum. A right hemicolectomy, resection of small bowel lesion and end to end anastomosis and submucosal resection of gastric tumour was done. The histopathological examination revealed that both the cecal and small bowel lesion showed malignant cells with glandular formation and the immunohistochemical staining were reactive for CK 7 and negative for CK 20, confirming it

as metastasis from the breast. It also confirmed that the gastric tumour was a GIST with unknown malignant potential.

She was subsequently planned for palliative care as she was not fit for chemotherapy. She was discharged home 10 days post surgery. However she was readmitted 4 months later with sepsis secondary to pneumonia and she succumbed to her illness.

DISCUSSION

Up to one third of patients with breast cancer will show evidence of metastatic spread over their course of disease. Common sites of metastasis in breast cancer include bone, liver, lung, and brain. Metastases to the Gastrointestinal tract remain rare. Metastasis to the stomach and small bowel have been more frequently reported compared to colonic and rectal lesions. Most metastatic lesions occur after the diagnosis of breast cancer has been established, typically within the first 5-10 years. However, some metastasis may take 20 to 30 years to manifest.

Borst published a large series that analyzed more than 2500 cases of breast cancer with metastatic disease over a period of 18 years; he found that only 17 patients (less than 1%) had metastasis to the GI tract². In a retrospective study, McLemore reported 23 cases of GI metastases, he found that the disease was more frequent in the midgut and hindgut than in the foregut³. Despite the greater incidence of incidental ductal breast carcinoma among woman (90%), lobular breast carcinoma has a specific metastatic pattern and more frequently metastasizes to the GI tract and retroperitoneal tissue than ductal cancer.

However, in the present case, the primary cancer was a ductal carcinoma, which has rarely been described in the literature. Furthermore she has metastatic lesions to both the colon and small bowel.

Immunohistochemistry has aided in differentiating the tumor site of origin. Hormone receptors, such as estrogen and progesterone receptors are utilized to differentiate breast versus GI primaries. The more common antigen markers include cytokeratins (CK) 7 and 20, MUC1, MUC2, and gross cystic disease fluid protein 15 (GCDFF-15)⁴.

This article was accepted: 13 May 2013

*Corresponding Author: Daphne Anthonysamy, Department of General Surgery, Hospital Tengku Ampuan Rahimah, Jalan langat, 41200 Klang, Selangor
Email: daphney77d@hotmail.com*

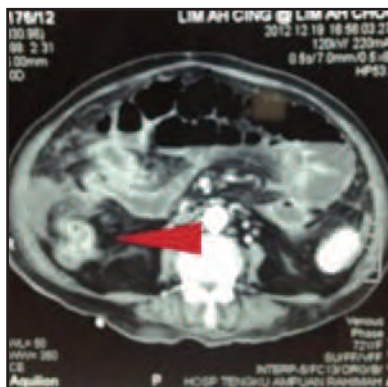

Fig. 1 : Caecal tumour.

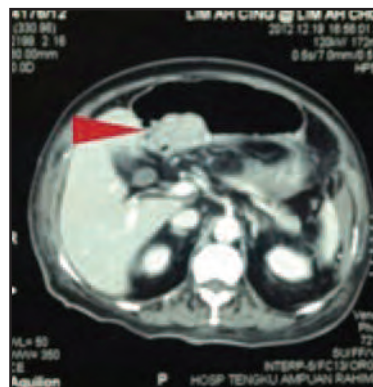


Fig. 2 : Stomach GIST at lesser curvature.

This is shown in the present case, because the tumor stained strongly for cytokeratin 7.

Clinical presentations of metastatic breast cancer of the luminal gastrointestinal tract can be diverse. Our patient presented with acute intestinal obstruction that required immediate surgical intervention.

In view that breast cancer metastasis to the gastrointestinal tract is rare, there is still no consensus on the management of these lesions. Ambroggi *et al.* reported that surgery was performed whenever possible, and postoperatively they were treated with either chemotherapy, radiotherapy or hormonal therapy. One patient in his study was treated only with hormonal therapy due to suboptimal medical conditions contraindicating chemotherapy⁵, which is similar to what was done for our case.

The overall prognosis of metastatic breast cancer to the GI tract is poor. The median survival after diagnosis is less than three years, with surgical intervention not greatly affecting survival rates. The median overall survival after a diagnosis of GI metastases is a little lower than the median survival of all women with metastatic disease secondary to breast cancer (range 24-36 months)⁵.

CONCLUSION

Breast cancer metastasis to the GI Tract is rare. However it should be suspected in patients with previous breast cancer who present with intestinal obstruction, even if the presentation is many years after the primary malignancy. Detailed pathological analysis using Informative markers such as the estrogen and progesterone receptors and immunostaining with CK7 can be very useful in facilitating the diagnosis. The choice of treatment must be tailored to the patient based on the extent of the metastasis. Resection of the involved bowel segment and postoperative systemic chemo or hormonal therapy should be considered.

REFERENCES

1. Toma S, Giacchero A, Bonelli L, Graziani A, De Lorenzi R, Aste H. Association between breast and colorectal cancer in a sample of surgical patients. *Eur J Surg Oncol* 1987; 13: 429-32.
2. MJ Borst, JA Ingold, P.O Hasselgren *et al*; "Metastatic patterns of invasive lobular carcinoma versus ductal carcinoma of the breast." *Surgery*, vol. 114;4: 637-642.
3. EC McLemore, BA Pockaaj, C Reynolds, *et al.*, "Breast cancer: presentation and intervention in women with gastrointestinal metastasis and carcinomatosis," *Annals of Surgical Oncology*, 2005 vol. 12;pp: 886-94.
4. Chu P, Wu E, Weiss LM. Cytokeratin 7 and cytokeratin 20 expression in epithelial neoplasms: A survey of 435 cases. *Mod Pathology* 2000; 13(9): 962-72.
5. Ambroggi M, Stroppa E.M, Mordenti P, *et al*" Metastatic Breast Cancer to the Gastrointestinal Tract: Report of Five Cases and Review of The Literature", *International Journal of Breast Cancer*, vol. 2012, ID: 439023.