

Iatrogenic corneal perforation in Terrien Marginal Degeneration

MR Kursiah, MS(Ophthal)

Ophthalmology Department, Hospital Sultanah Bahiyah, Alor Star, Kedah, Malaysia

SUMMARY

This case report is about a rare disease with unusual presentation. Failure to recognise atypical presentation may lead to error in managing the patient and cause disastrous complications. Here we highlight a case of Terrien Marginal Degeneration in both eyes with atypical presentation; namely pseudopterygium. A 22 year old man was referred to our centre for iatrogenic right eye corneal perforation after having an atypical pterygium removed at another hospital. On arrival, his vision was 1/60 in both eyes with bilateral cornea Terrien Marginal Degeneration. His right eye anterior chamber was deep with a conjunctival flap covering the perforation site which was located from the 2.30 – 3.30 clock position nasally with no aqueous leak. However after a day his right eye anterior chamber became flat and there was fast aqueous leak from the perforation site. An emergency C shaped peripheral corneal lamellar keratoplasty was performed to seal the perforation. Post operatively his right eye improved to 6/24.

KEY WORDS:

Terrien Marginal Degeneration, Atypical pterygium, corneal perforation

INTRODUCTION

Terrien Marginal Degeneration is typically described as a disease of the middle to late age.⁽¹⁾ It is rare, slowly progressive, bilateral and characterised by peripheral corneal stromal thinning. However there are several articles that have described a variant of this disease with prominent inflammation occurring in a younger age group and in children^{1,2}. Terrien Marginal Degeneration usually starts at the superonasal quadrant as fine yellow-white punctate stromal opacities which progressively involves the entire circumference of the peripheral cornea with neovascularisation, scarring and lipid infiltration occurring at the leading edge³. Other rare presentations are atypical pterygium which appear early in the disease and occurs at other than the 3 and 9 o'clock position and spontaneous corneal perforation^{4,5}. Failure to recognise this early onset atypical pterygium as one of the manifestation of Terrien Marginal Degeneration can result in an iatrogenic peripheral corneal perforation when surgical removal of the pterygium is attempted. In this article we highlighted a case of iatrogenic peripheral corneal perforation post atypical pterygium removal that occurred in a young patient with inflammatory variant of Terrien Marginal Degeneration.

CASE REPORT

A 22-year-old man was referred for iatrogenic corneal perforation after an attempt to remove atypical pterygium on his right eye. The patient had history of recurrent bilateral eye redness for 5 years which was associated with deterioration of visual acuity. He also noted a slowly progressive nasal conjunctival growth invading his cornea during that period.

He went to a hospital and was offered pterygium removal; which he agreed have. Unfortunately intraoperatively a peripheral cornea perforation was noted by the surgeon. As a temporary measure to seal the perforation, the surgeon performed a conjunctival flap to cover the perforation (refer to figure 1).

His presenting vision to us was 1/60 bilaterally. There was circumferential peripheral corneal thinning associated with vascularization. Fine yellow white deposits were seen in the corneal stroma with lipid infiltrates at the leading edge. On the right eye a conjunctival flap was seen at the nasal side of cornea. Siedel's test was negative and anterior chamber was deep. Bilaterally the lenses were clear with normal fundus finding of healthy 0.3 cup disc ratio and good fovea reflex. However the next day, the conjunctival flap retracted causing a leak of aqueous and shallowing of anterior chamber with incarceration of iris tissue. He underwent an emergency peripheral C shaped corneal lamellar keratoplasty. Intra-operative the peripheral corneal perforation located at 2.30 – 3.30 clock position was sealed with corneal lamellar keratoplasty and the iris tissue was repositioned making the pupil more centrally located (refer figure 2)

Post operatively his right eye vision improved to 6/24 with refraction of -4.50/-3.00 x 70 degree. His left eye vision was poor with refraction of -1.00/-10.00 x 105 degree due to ectatic cornea as a result of Terrien Marginal Degeneration

DISCUSSION

A variant of Terrien Marginal Degeneration occurs in a younger age group. In this group it is characterised by prominent inflammation with severe pain and associated episcleritis or superficial scleritis¹. This inflammatory variant occur mostly at 20-40 years old with male to female ratio of 3:1.

This article was accepted: 15 February 2013

Corresponding Author: Kursiah Mohd Razali, Ophthalmology Department, Hospital Sultanah Bahiyah, Alor Star, 05460 Kedah, Malaysia
Email: mkursiah@gmail.com

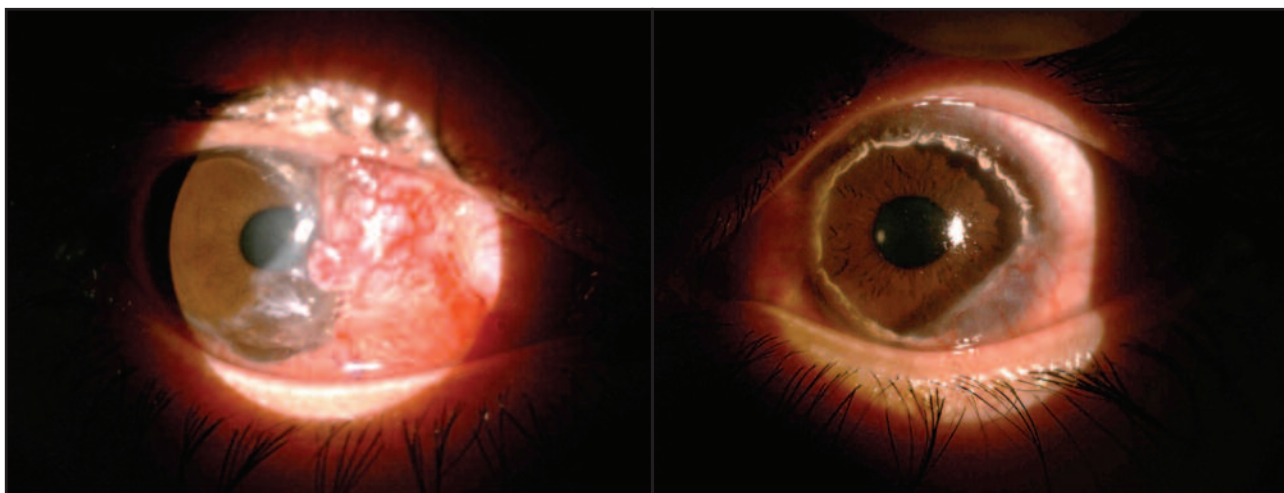


Fig. 1 : Appearance of the right and left eye on presentation. Conjunctival flap was done to the right eye to seal the perforation from 2 – 3.30 o'clock position.

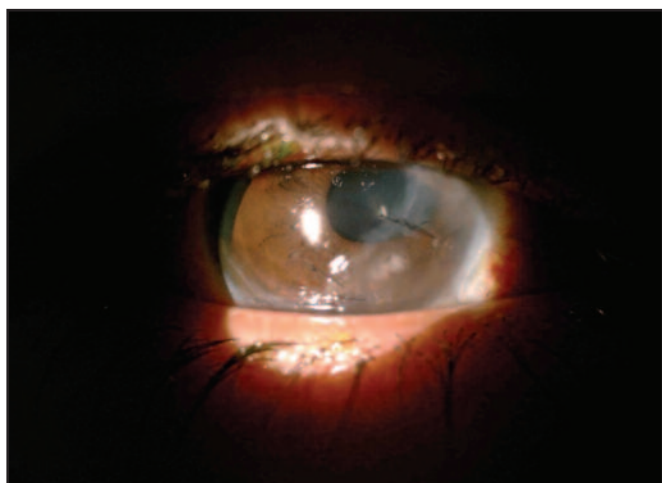


Fig. 2 : Right eye after C shape lamellar keratoplasty.

This patient showed characteristic changes that coincided with inflammatory type of Terrien Marginal Degeneration. He had recurrent bilateral eye redness since 5 years ago with deteriorating visual acuity suggesting progressive corneal ectasia with resultant high astigmatism.

Another rare feature of this disease is pseudopterygium or atypical pterygium which appear early in the disease. This pseudopterygium has a characteristic appearance, which is of diagnostic value and occurs at position other than 3 and 9

o'clock position, grows into cornea at an oblique axis and has a rather broad, flat leading edge⁴. Failure to recognise this pseudopterygium may cause unnecessary removal thus corneal perforation.

Various techniques of lamellar keratoplasty have shown to improve visual acuity, reduce corneal astigmatism and stabilize the peripheral corneal ectasia in Terrien Marginal Degeneration. In this patient C shaped lamellar keratoplasty had improved his best corrected visual acuity from 1/60 to 6/24. Refractive finding post operatively showed regular astigmatism of -3.00 diopter cylinder.

As a conclusion; recognition of atypical feature of this disease will definitely prevent unnecessary removal of pseudopterygium that can lead to iatrogenic complication the patient.

REFERENCES

1. Beauchamp GR. Terrien's Marginal corneal degeneration. *J Pediatr Ophthalmol Strabismus* 1982 Mar-Apr; 19(2): 97-9.
2. Austin P, Brown SI. Inflammatory Terrien's marginal corneal disease. *Am J Ophthalmol* 1981 Aug; 92(2): 189-92.
3. Ceresara G, Migliavacca L, Orzalesi N, Rossetti L. In vivo confocal microscopy in Terrien marginal corneal degeneration: a case report. *Cornea* 2011 Jul; 30(7): 820-4.
4. Goldman KN, Kaufman HE. Atypical pterygium. A clinical feature of Terrien's marginal degeneration. *Arch Ophthalmol* 1978 Jun; 96(6): 1027-9.
5. Srinivasan S, Murphy CC, Fisher AC, Freeman LB, Kaye SB. Terrien marginal degeneration presenting with spontaneous corneal perforation. *Cornea*. 2006 Sep; 25(8): 977-80.