

# Leucocytosis in a case of Lung Cancer: Infection or Paraneoplastic Syndrome? - Dilemma in Diagnosis and Treatment

Sudipta Pandit, MD, Sabyasachi Choudhury, MD, Sibes Kumar Das, MD, Saumen Nandi, MD

Medical College, 88, College Street, Kolkata, West Bengal 713 073 India

### SUMMARY

A 65 year old male smoker was diagnosed with squamous cell carcinoma of upper lobe of the right lung complicated with Horner's syndrome and gradually increasing leucocytosis. Although the inflammatory biomarker level in serum was low, there was no definite way to determine the cause of the leucocytosis (whether infection or hematologic paraneoplastic syndrome). After empirical antibiotic therapy, his fever subsided but the leucocytosis persisted. It was difficult for us to take a decision regarding the priority of the treatment of infection or the lung cancer. Only after the first cycle chemotherapy, did the leucocytosis rapidly drop down. Normal serum procalcitonin level and quick response to chemotherapy indicated that leucocytosis was a manifestation of paraneoplastic syndrome. Treating the underlying cancer is the first step.

### KEY WORDS:

*Paraneoplastic syndrome, Leucocytosis, Lung cancer*

### INTRODUCTION

The paraneoplastic syndrome was first described by the French physician, M. Auchè, who reported peripheral nervous system involvement in cancer patients in 1890<sup>1</sup>.

Paraneoplastic syndromes are rare disorders that are triggered by an altered immune system response to a neoplasm. They are defined as hormonal, neurologic, hematologic, or other remote effects of cancer not related to the direct invasion, obstruction, or metastatic effects of tumor or treatment related side effects. In a broad sense, these syndromes are collections of symptoms that result from substances produced by the tumor, and they occur remotely from the tumor itself. Paraneoplastic syndromes related to bronchogenic carcinoma occur in 10% to 20% of patients.

Leucocytosis is a rare manifestation of the paraneoplastic syndrome of bronchogenic carcinoma. However it can also be a manifestation of infection in cancer patients. The presence of leucocytosis in a cancer patient can lead to diagnostic and therapeutic dilemma as the differentiation between paraneoplastic syndrome and infection as a cause of leucocytosis is not always easy.

### CASE REPORT

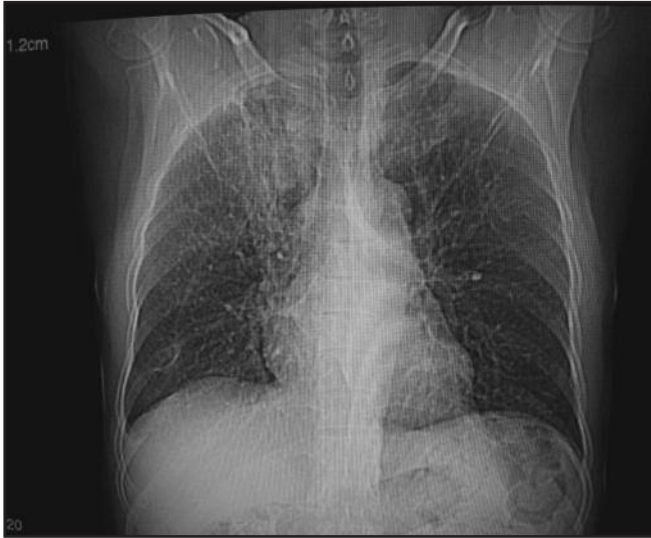A 65-year-old male patient presented with a history of gradually progressing exertional shortness of breath along with dry cough of eight months and hoarseness of voice along with right sided dull aching chest pain of three months. Shortness of breath was neither associated with any wheeze nor associated with any history of paroxysmal nocturnal dyspnoea. Cough was not associated with any seasonal or diurnal variation. He developed gradually progressing drooping of right upper eye lid during last three-month. He had a continuous fever around 100° F for last two-days before admission. He had one episode of streaky hemoptysis three-months back and suffered from pulmonary tuberculosis forty-years back. He smoked cigarettes without filter for 15 pack-years. The patient was hypertensive and used to take amlodipine with hydrochlorothiazide.

Clinically he had grade III clubbing along with the features of right upper lobe fibrosis. He had right upper eye lid partial ptosis, miosis of right eye, anhydrosis of right half of face. Celio-spinal reflex was not very much prominent. Chest skiagram revealed right upper lobe non-homogenous opacity (Fig.1). Hematology report revealed total leucocyte count (TLC): 31,900/mm<sup>3</sup> with 90% neutrophil on the day of admission. There was no abnormality of the liver function test (LFT), renal function test, fasting blood sugar and serum calcium level were normal. His serum procalcitonin was 0.12 µg/L. Blood and urine culture showed no growth of organism after seventy-two hours. Bone marrow study revealed only leuco-erythroblastic reaction without any evidence of malignant infiltration and no growth of any organism on culture. Patient presented to us with a report of CT guided Fine Needle Aspiration Cytology (FNAC) of the right upper lobe mass lesion, revealing sub-acute inflammatory condition. Considering his age, history and clinico-radiological finding we suspected lung malignancy and performed Fiberoptic Bronchoscopy (FOB) which was normal. Then we decided to do a repeat contrast enhanced computed tomography (CECT) scan of Thorax with CT guided FNAC of the right upper lobe lesion. This time CECT revealed a right paratracheal mass lesion extending up to the apex (Fig.2). FNAC of the mass revealed, squamous cell carcinoma of upper lobe of the right lung (Fig.3). He was thus diagnosed as a case of squamous cell carcinoma of upper lobe of the right lung complicated with Horner's syndrome and leucocytosis.

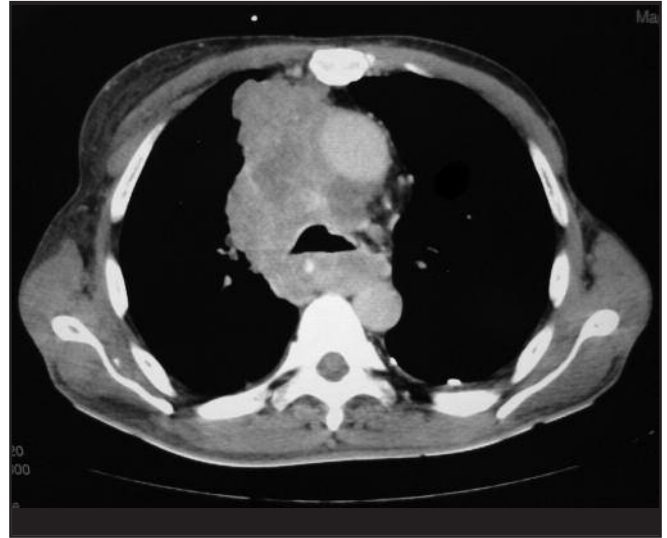
This article was accepted: 5 May 2012

Corresponding Author: Sudipta Pandit, Medical College, 88, College Street, Kolkata, West Bengal 713 073 India

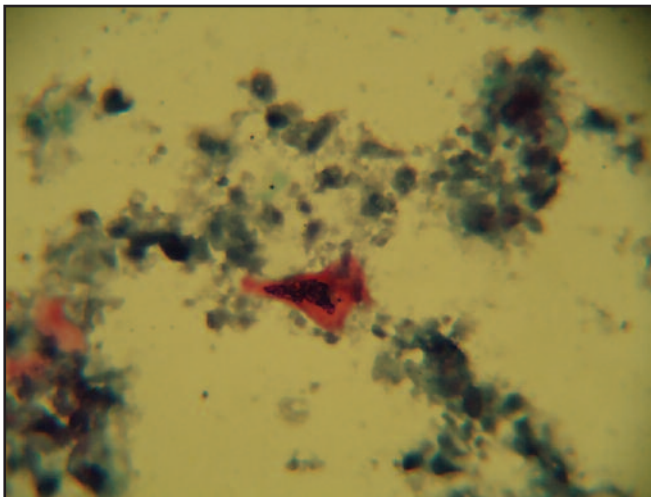
Email: [drsudiptapandit@rediffmail.com](mailto:drsudiptapandit@rediffmail.com)



**Fig. 1 :** CXR - PA view showing right upper lobe non-homogeneous opacity.



**Fig. 2 :** CECT thorax showing right paratracheal mass lesion.



**Fig. 3 :** FNAC of the mass revealed, squamous cell carcinoma of upper lobe of the right lung.

We started co-amoxycylav and levofloxacin simultaneously empirically after sending the bronchoalveolar lavage (BAL) fluid for Z-N stain, Gram stain and aerobic pyogenic culture and sensitivity test. After seventy-two hours of culture growth of *Klebsiella* sp. developed, sensitive to meropenem, linezolid and amikacin. After three days TLC was 45,500/mm<sup>3</sup> with 76% neutrophil and fever was persisting. We started meropenem and linezolid afresh and fever subsided within next three days but TLC increased to 50,100/mm<sup>3</sup> with 81% neutrophil. Same antibiotics were continued for another 4 days but surprisingly the TLC increased to 65000/mm<sup>3</sup> with 91% neutrophil but patient was still afebrile. Then we stopped all antibiotics. TLC was high persistently. Oncologist was not allowing us to start chemotherapy initially and advised to wait till the TLC comes down to less than 15000/mm<sup>3</sup>. Repeat serum procalcitonin level was done after 1, 3, 5 and 7 days. Each time the value was between 0.1-0.12

µg/L. We observed the patient for next seven days and his condition was same as before. There was no fever but the count was 68400/mm<sup>3</sup> with 90% neutrophil at the end of one week. Ultimately after considering the entire situation, the oncologist allowed chemotherapy to start with a single day paclitaxel and gemcitabine containing regime. Three days after the first cycle of chemotherapy, TLC rapidly dropped down to 30200/mm<sup>3</sup> with 75% neutrophil. We discharged the patient and the patient came back after seven days in afebrile state with TLC 16700/mm<sup>3</sup> with 65% neutrophil. Then he was referred to oncology department for subsequent chemotherapy.

#### DISCUSSION

Paraneoplastic syndromes are common in lung cancer, and may be the first manifestation of the disease or its recurrence<sup>2</sup>. Leucocytosis occurs in about 30% of patients with solid tumors. Leucocytosis is often found in patients with lung cancer either at time of diagnosis or during the course of the disease<sup>3</sup>. Generally 1.4% to 14.5% of patients of lung cancer develop leucocytosis<sup>3</sup>. In one study leucocytosis was described in 15% of all patients with lung cancer (n = 227). Nearly all patients had NSCLC<sup>3</sup>. In about half of the patients with leucocytosis and lung cancer, the leucocytosis occurs due to an identifiable non-paraneoplastic etiology like infection, tumor necrosis, corticosteroid therapy etc. Tumor cell in lung carcinoma have been documented to produce granulocyte colony stimulating factor (G-CSF), granulocyte - macrophage colony stimulating factor (GM-CSF) and interleukin (IL)- 6<sup>4</sup>. However in most patients, the etiology of paraneoplastic leucocytosis is not known. Patients of advance stage carcinoma are more likely to develop leucocytosis. Leucocytosis of obscure etiology may be seen in association with lung carcinoma, which is usually an unfavorable prognostic indicator<sup>3</sup>. But the true role of excessive leukocyte production and their implication in immune dysregulation and paraneoplastic syndrome remain unclear.

Differentiation between infection and paraneoplastic syndrome as a cause of leucocytosis is not always easy. But there are few clinical clues. In contrast to infection, paraneoplastic leucocytosis does not have a shift to immature forms of neutrophils. Recently several biomarkers of infection are available, which are useful to predict the diagnosis of infection, host response and prognosis, especially in severe community acquired pneumonia and ventilator associated pneumonia. They include serum procalcitonin, C-reactive protein, proadrenomedullin, copeptins, natriuretic peptide, triggering receptor expressed on myeloid cells 1 (TREM1) etc. Procalcitonin, the most promising marker is a peptide precursor of calcitonin that is released by the parenchymal cells in response to bacterial toxins and certain bacterial specific proinflammatory mediators like IL-16, IL-6 and tumor necrosis factor. Procalcitonin <0.1 µg/L implies bacterial infection very unlikely and antibiotics can safely be withheld. With procalcitonin between 0.1-0.25 µg/L, antibiotics are only recommended in presence of hemodynamic instability, life threatening condition, evidence of empyema or positive microbiological test<sup>5</sup>. Absence of symptoms, increased leucocyte alkaline phosphatase score, a normal bone marrow and a quick resolution of leucocytosis with the treatment of the underlying malignancy are other evidences consistent with the diagnosis of paraneoplastic leucocytosis.

## CONCLUSION

Paraneoplastic syndromes are common in lung cancer patients and one manifestation is leukocytosis. Treating the underlying cancer is the first step. Clinician should be aware of this when the possibility of infection is excluded.

## REFERENCES

1. Aucho M. Des nevrites peripheriques chez les cancéreux. *Rev Med. (Paris)* 1890; 10: 785-807.
2. Bunn PA, Ridgway EC. Paraneoplastic syndromes. In: DeVita, V.T., Hellman, S. and Rosenberg, S.A, eds. *Cancer: Principles and Practice of Oncology*. 4th Edn. JB Lippincott Co, 1993 pp 2026-71.
3. Kasuga I, Makino S, Kiyokawa H, Katoh H, Ebihara Y, Ohyashiki K. Tumor-related leukocytosis is linked with poor prognosis in patients with lung carcinoma. *Cancer*. 2001; 92(9): 2399-405.
4. Johnson BE, Chute JP. Extrapulmonary syndromes associated with lung tumors. In: Fishman AP, Elias JA, Fishman JA, Grippi MA, Senior RM, Pack AL (eds). *Fishman's Pulmonary disease and disorders*. Vol-2, 4th edition, New York: Mc Graw Hill Medical, 2008: 1929-40.
5. File TM (Jr). New Diagnostic tests for Pneumonia: What is there role in clinical practice? *Clin Chest Med* 2011; 32: 417-30.