

An Unusual Presentation of Adult Onset Still's Disease

Anirban Ghosal, MD, Radha Binod Pal, MBBS, MD (PAED), Somak Kumar Das, MBBS, Tanima Das, MBBS, MD (MED)

N.R.S Medial College & Hospital, Neurology, 138, AJC Bose Road, Kolkata-700014, Kolkata, West Bengal 700014, India

SUMMARY

Adult onset still's disease usually presents with high grade intermittent fever, polyarthritis, salmon pink evanescent rash and hepatosplenomegaly. Pulmonary involvement in the form of pneumonitis, as a presenting feature is very rare. We report a case of a young lady who presented with fever, cough and respiratory distress. Chest X-ray revealed patchy infiltration in left upper lung zone. She was subsequently diagnosed as Adult onset Still's disease. There was no improvement in clinical condition despite five days of antibiotics. On trans-bronchial lung biopsy (TBLB) proved she had interstitial pneumonitis and responded dramatically to steroid treatment.

KEY WORDS:

Adult onset still's disease, respiratory distress, interstitial pneumonitis, steroid.

INTRODUCTION

Adult onset Still's disease is a multisystem inflammatory disorder characterized by high spiking fever, rash, polyarthritis, lymphadenopathy and hepatosplenomegaly. Polymorphonuclear leukocytosis in the absence of infection, elevated erythrocyte sedimentation rate (ESR) and high serum ferritin are characteristic features. Rashes are typically faint salmon colored, transient, appearing along with spike of fever. Pleural effusion, upper lobar pneumonia, pericardial effusion and myocarditis are also reported.

CASE REPORT

A 30 year old lady was admitted with high grade intermittent fever and non productive cough of 18 days and dyspnoea of 2 days. There was no chest pain or haemoptysis. She was a non-smoker, did not have pets, neither had any travel or contact history in recent past. She had a temperature of 39°C; mild pallor; respiratory rate was 30 breaths /min and had no lymphadenopathy, clubbing or cyanosis. Her trachea was normal in position. Chest auscultation revealed few crackles over left mammary and axillary region. She gave a history of an erythematous rash over chest 14 days back which had now had now formed hypo pigmented residues following desquamation. Her Hemoglobin was 9.6 gm%, leucocyte count 20,000 / μ L with 89% neutrophil and high ESR (100 mm in first hour). Chest X-ray revealed patchy infiltration in left upper lung zone. High resolution chest computed tomography (CT) scan confirmed interstitial infiltration of the anterior segment of the left upper lobe (Figure: 1). She was started with oral azithromycin 500mg daily and injection

ceftriaxone 2grams/day. On third day of admission, arthritis appeared in the right wrist and later involved both knee. There was also history of early morning stiffness involving the hands without any night pain for last three months. Her C - reactive protein was high (32 mg/dl), liver enzymes aspartate aminotransferase (105 U/L) and alanine aminotransferase (81U/L) were raised. Tests for HIV-1 and HIV-2; hepatitis B & C, were negative. Anti nuclear factor (ANA), Anti ds-DNA, Anti cyclic citrullinated peptide antibody, Anti U1-RNP, Scl-70 and Antineutrophilic cytoplasmic antibody were all negative. Rheumatoid factor and anti-streptolysin O titre were within the normal range. Ultrasound of the abdomen showed moderate hepatomegaly. All smear and culture reports of urine, sputum and blood were negative. Her fever, cough and neutrophilic leukocytosis persisted despite five days of antibiotic treatment. As the Yamaguchi diagnostic criteria for Adult Onset Still's disease (AOSD) was fulfilled, serum ferritin estimation was done and it was found elevated (11,000 ng/ml).

As the clinical and radiological findings of chest showed no signs of resolution even after seven days of treatment, a flexible bronchoscopy was performed. Bronchoalveolar lavage and bronchial brush specimens were negative in acid-fast smear test, culture and polymerase chain reaction for tubercle bacillus. Histological examination of the trans-bronchial lung biopsy specimen disclosed interstitial pneumonia pattern and focal areas of atelectasis (Figure: 2).

She was given pulse intravenous methylprednisolone ¹ gm/day for three days. Fever and arthritis subsided dramatically and her respiratory rate became normal. Follow up was done with high dose oral prednisolone (1mg/kg body weight). Signs of resolution of pneumonic changes were noted in Chest x-ray at 2 weeks, neutrophilic leukocytosis subsided and ferritin was 9800 ng/ml. Prednisolone was gradually tapered over several months without any further flare ups in next 6 months. She continued well with low dose steroid (10 mg oral prednisolone per day) and oral methotrexate (7.5mg per week).

DISCUSSION

Pulmonary manifestation of AOSD is reported to be 12-53% for pleuritis and 0-27% for interstitial pneumonia ¹. Transient pulmonary infiltrates and pleural effusion are the most common pulmonary diseases. Occasional cases of cryptogenic organizing pneumonia and diffuse pulmonary hemorrhage (DAH) are also reported ².

This article was accepted: 29 May 2012

Corresponding Author: Anirban Ghosal, N.R.S Medial College & Hospital, Neurology, 138, AJC Bose Road, Kolkata-700014, Kolkata, West Bengal 700014, India Email: dranirban.ghosal@gmail.com

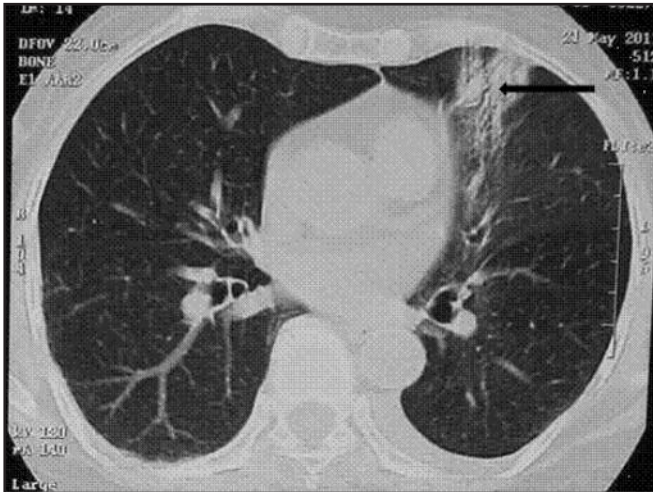


Fig. 1 : Computed tomography of chest showing interstitial infiltration of the anterior segment of the left upper lobe (arrow).

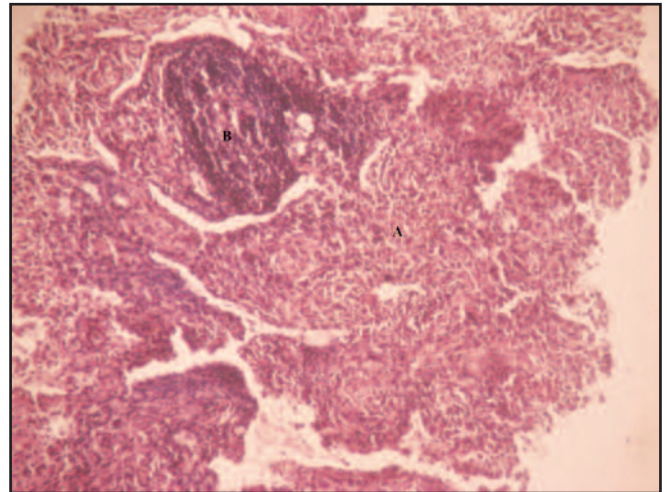


Fig. 2 : Light microscopy of trans-bronchial lung biopsy specimen showing areas of atelectasis with interstitial dense lymphoplasmacytic infiltrates (A) with focal organizing pattern (B). (Hematoxylin-Eosin Stain × 10).

But AOSD presentation as pulmonary involvement is quite rare. Our patient presented with long continued fever and clinical as well as radiological features of pneumonia. After excluding common etiologies, diagnosis of AOSD was entertained on the basis of more than 2 weeks of fever, polyarthritides, rash, persistent neutrophilic leukocytosis and elevated liver enzymes. Hyperferritinaemia, negative ANA and Rheumatoid factor further helped in diagnosis.

Interleukin-18 (IL-18) is the most important proinflammatory cytokine in AOSD pathogenesis. It is overproduced in the acute phase of the disease and is believed to initiate the inflammatory cascade that includes interferon gamma, IL-6, and tumor necrosis factor alpha. Increased IL-18 levels is found in both blood and lung tissue in endotoxemia-related lung injury³. This may lead to interstitial lymphoplasmacytic infiltration and pulmonary capillaritis resulting in DAH.

Hyper-ferritinemia in AOSD is probably a consequence of cytokine secretion induced by the reticuloendothelial system or hepatic damage. A fivefold increase in serum ferritin has 41% specificity and 80% sensitivity⁴. Ferritin levels correlate with disease activity; and after remission get normalized. Liver function abnormalities occur in the form of elevation of serum transaminases. Ferritin was raised in our case as were serum transaminases.

Aspirin or non steroidal anti inflammatory drugs are recommended as initial treatment of AOSD, but response rate is low. Most patients are therefore treated with corticosteroids in the course of their disease, with an efficacy of up to 95%. Steroid should also be used for those suffering from persistent anemia, pericarditis, serositis and marked elevation of liver enzymes⁵. We treated our patient with high dose methylprednisolone for her non resolving systemic and pulmonary manifestations and got excellent result.

We therefore conclude that pulmonary involvement in the form of interstitial pneumonia can be an initial presentation of Adult-onset Still's disease which responds dramatically to glucocorticoid treatment. AOSD diagnosis should be considered by clinicians in a case of non resolving pneumonia after exclusion of common infective, malignant and inflammatory etiologies.

REFERENCES

1. Yamaguchi M, Ohta A, Tsunematsu T, *et al*. Preliminary criteria for classification of adult still's disease. *J Rheumatol* 1992; 19: 424-430.
2. Ismail Sari, Merih Birlik, Omer Binicier, *et al*. A Case of Adult-Onset Still's Disease Complicated with Diffuse Alveolar Hemorrhage. *J Korean Med Sci* 2009; 24:155-157.
3. Efthimiou P, Georgy S. Pathogenesis and management of adult-onset Still's disease. *Seminars in Arthritis and Rheumatism* 2006; 36:144-152.
4. Fautrel B, Le Moel G, Saint-Marcoux B, *et al*. Diagnostic value of ferritin and glycosylated ferritin in adult onset Still's disease. *J Rheumatol* 2001; 28:322-9.
5. Cush JJ. Adult-onset Still's disease. *Bull Rheum Dis*, 2000; 49:1-4.