

Comparing the Morbidity of External Laryngeal Nerve Injury in Thyroid Surgery with and without Identifying the Nerve using Intraoperative Neuromonitoring

A O Khaled, MBChB, M Irfan, MD, MMed (ORL-HNS), A Baharudin, MBBS, MMed (ORL-HNS), H Shahid, MCPS (ORL)

Department of Otorhinolaryngology-Head and Neck Surgery, School of Medical Sciences, Universiti Sains Malaysia, 16150 Kubang Kerian, Kelantan, Malaysia

SUMMARY

Objective: To describe and determine the possibility of surgical trauma to the external branch of the superior laryngeal nerve and to assess the role of intraoperative neuromonitoring in thyroid surgery.

Design and Setting: Prospective, randomized, controlled study in a teaching Hospital Universiti Sains Malaysia (HUSM), Kota Bharu, Kelantan, Malaysia.

Subjects: Forty two patients of both genders, whom underwent thyroid surgery divided into two groups (21 patients control group and 21 patients study group) in HUSM and were randomly selected for our study.

Methods: The use of nerve monitoring and proper surgical technique of upper thyroid pole dissection followed by its lateralization and exposure of cricothyroid space were performed in each subject in study group in order to preserve EBSLN after its identification. In control group upper thyroid vessels were ligated close to the upper thyroid pole without any effort of EBSLN identification.

Results: Total of 42 (35 females and 7 males) patients who underwent thyroid surgery in a period of 2 years. Evaluation of all subjects 1 case in control group presented with symptoms of EBSLN injury.

Conclusion: Intraoperative identification and neuromonitoring can avoid injury to the EBSLN and prevent its sequential changes in voice especially for those who professionally depend to their voice.

KEY WORDS:

Thyroidectomy, Superior laryngeal nerve, Voice dysfunction, Intraoperative neuromonitoring

INTRODUCTION

The external branch of superior laryngeal nerve (EBSLN) is related to the structures of the upper pole of thyroid gland. It passes through the potential avascular cricothyroid space (Space of Reeve). The nerve then continues in its course over the inferior constrictor muscle to reach and supply the cricothyroid muscle. Injury to the EBSLN during thyroid

surgery is not uncommon. Most surgeons tend to avoid rather than to expose and identify the external laryngeal nerve. Carefully dissecting the upper pole of the thyroid gland utilizing the nerve monitoring is helpful to preserve the EBSLN. Injury to this nerve (EBSLN) during thyroid surgery can have serious consequences for patients especially for those who depend on their high pitch voices, for example singers, teachers or professional speakers. Due to small diameter of the EBSLN and its wide variation in course sometimes optical identification is difficult. Thus the use of nerve monitoring in identification of EBSLN in our study during thyroid surgery has been the essential method in identifying the nerve intraoperatively and then its preservation. The purpose of this study was to describe and assess the possibility of iatrogenic injury to the EBSLN by the clinical examination using laryngoscopic examination and evaluation of voice dysfunction after thyroid surgery.

MATERIALS AND METHODS

In this study patients were divided into study and control group based on a Random Number Table. Study group of 21 patients of whom the procedure has done with EBSLN identification in help with nerve monitoring and control group of 21 patients without any effort for identifying of EBSLN same as operating in conventional method. All thyroidectomies performed in the period of study from June 2008 to June 2010, were intraoperatively observed and documented. All types of thyroidectomies are included. Knowing different types of thyroidectomies may impose different risk of injury, randomization thus plays a very important role to reduce bias in any one of the group. All admitted patients who fitted the inclusion criteria that underwent thyroid surgery, were selected from Otorhinolaryngology-Head and Neck Surgery clinic in HUSM. The exclusion criteria include anaplastic thyroid carcinoma, Grave's disease, completion thyroidectomy, presence of cervical lymphadenopathy and abnormal vocal cord function pre-operatively. The surgery was done by many surgeons involved in ORL-HNS training. This constitutes a limitation of the study whereby number and the experience of surgeon can affect the outcome of surgery. However, we have undertaken effort to minimize it by designating a single and experienced senior surgeon to be in the team in every operation.

This article was accepted: 23 February 2012

Corresponding Author: Irfan Mohamad, Department of Otorhinolaryngology-Head & Neck Surgery, School of Medical Sciences, Universiti Sains Malaysia Health Campus, 16150 Kota Bharu, Kelantan, Malaysia Email: irfan@kb.usm.my

Over 20 months 21 patients of study group underwent thyroid surgery using technique of upper pole lateralization, dissection of avascular cricothyroid space, identification of EBSLN and individual ligation of the superior thyroid vessels. During the same period 21 patients of control group underwent conventional thyroidectomy without any effort of EBSLN identification. Demonstration of the anatomical EBSLN course and its relationship to the upper thyroid pole was facilitated by intraoperative use of the nerve monitoring. Identified nerves were classified according to Cernea's classification¹. Outcome parameters of this study were the incidence of EBSLN injury and the efficiency of neuromonitoring intraoperatively during EBSLN identification.

Surgical technique

In this study we present a valid and safe surgical technique for practical identification and its preservation of EBSLN in thyroid surgery. The EBSLN arises from the superior laryngeal nerve of the 10th cranial nerve and descends dorsolaterally to the carotid arteries at C3 level, crosses them and passes to the superior thyroid artery (STA). The nerve courses medially through the space of Reeve to enter and supply the cricothyroid muscle. The key point for identification of the EBSLN intraoperatively in thyroid surgery is the topographical relationship between this nerve and the upper thyroid pole with the superior thyroid vessels². Based on this relation Cernea et al determined and described the types or the levels of their classification (Type 1, 2a and 2b)³. Cernea et al classification in our study was the essential guide for identifying the EBSLN. Surgical steps in thyroidectomy started with rising of subplatysmal flap together with anterior jugular vein superiorly until hyoid bone level and inferiorly until sternal notch. It is followed by separation and division of strap muscles at its upper one-third to avoid injury to ansa cervicalis nerve. Mobilization of upper thyroid pole after identification of middle thyroid vein and its ligation is the starting surgical step for identifying the EBSLN. Proper dissection of upper thyroid pole by its lateralization and exposure of cricothyroid space, enable the ability of EBSLN identification [Figure 1]. The EBSLN can be detected running on the surface or entering the cricothyroid muscle, by gentle retraction of the upper thyroid pole vessels. Due to the small caliber of EBSLN, the use of nerve monitoring intraoperatively was essential and performed in each thyroid surgery of study group before upper thyroid pole vessels ligation.

Dividing and ligation of superior thyroid vessels close to the gland is a surgical step which always performed after EBSLN identification to ensure its preservation. Mobilization of inferior thyroid pole and inferior thyroid artery exposure using nerve monitoring in both groups is essential surgical step to identify and secure the damage to the recurrent laryngeal nerve. Repositioning and skin closure were the last surgical step after confirming of continuity and conductivity of recurrent laryngeal nerve and EBSLN.

RESULTS

A total of 42 patients with completed requirements of inclusion criteria were included to this study. The gender ratio

was 35 female to 7 male patients. The age range was from 17 to 68 years old and the mean was 41.7 years. Thyroid surgery in this study was performed for multinodular goiter in 24 cases, thyroid nodule in 13, cystic goiter in 2, follicular adenoma in 2 and papillary carcinoma in one patient [Figure 2]. Significantly more type 1 nerves were identified using nerve stimulator followed by type 2a. Type 2b not seen in our series within study group. Results were evaluated based on postoperative 70 degree rigid laryngoscopy and subjective interview. Clinically 19 of 42 patients (45%) diagnosed with a various degrees of postoperative temporary voice changes, which persisted from few weeks to 2 months [Figure 3]. Evaluation of all subjects after 6 months of thyroid surgery, one case in the control group presented with symptoms of permanent easy voice fatigue, mild hoarseness and decreased of high-pitched sound, which was diagnosed as EBSLN palsy [Figure 4].

DISCUSSION

The principles of all surgeries including head and neck surgeries are based on identification and preservation to avoid injury of important structures. Identification and preservation of the nerves intraoperatively must be as standard as in all thyroid surgeries. Damage to the recurrent laryngeal nerve often is easy to detect and recognize with clinical and 70 degree rigid laryngoscopy examination. On other hand injury to the external branch of superior laryngeal nerve in thyroid surgery is within difficulties to diagnose and may frequently be overlooked because of poor clinical signs^{4, 5, 6}. The incidence reported in the literatures of injury to EBSLN intraoperatively in thyroid surgery is not as well documented as that of the recurrent laryngeal nerve; it has been reported to be from 0.3% to 56%^{5, 7}. In this study the incidence of EBSLNs damage and their consequences in term of voice quality was studied in 42 patients underwent thyroid surgery and has been documented to be 2%. Beside evaluation of clinically any voice changes after thyroid surgery, indirect 70 degree rigid laryngoscopy was performed with each patient by two examiners who searched for any structural and kinetic laryngeal abnormalities. Understanding the 3 anatomic grades of the lower part of EBSLN and its relation to the upper thyroid pole allows for high percentage of EBSLN identification. Damage to external branch of superior laryngeal nerve (EBSLN) can cause serious voice changes according to the voice needs of the patient. Our results in this study show that the proper dissection of the upper thyroid pole by its lateralization and use of intraoperative neuromonitoring (IONM) was able to identify the EBSLN.

Anatomically the cricothyroid muscle is supplied by external branch of superior laryngeal nerve, which tenses the vocal cord. Tension of the vocal cords allows the ability of voice production at frequencies above 150 Hz, which is called the high tones of voice range⁸. Thus the clinical subjective interview examination for the ability on high-pitched voice range production after thyroid surgery was performed with each subject in control and study group. All cases in both groups were interviewed after thyroid surgery to examine and search for vocal symptoms as hoarseness, voice changes and fatigability. Many patients complained of vocal changes in

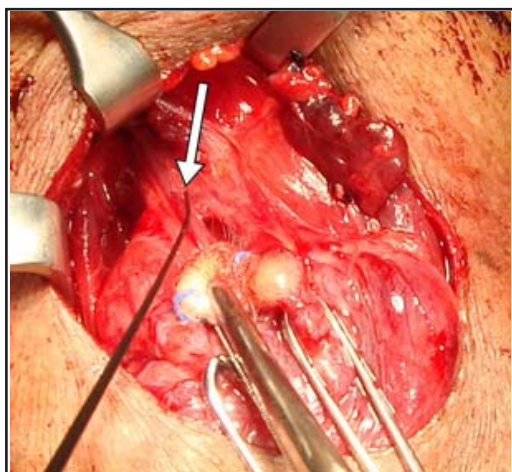


Fig. 1: Lateralisation of upper thyroid pole and identification of right EBSLN crossing the superior thyroid vessels utilizing nerve monitoring in thyroid surgery (arrow pointing to the course of the EBSLN).

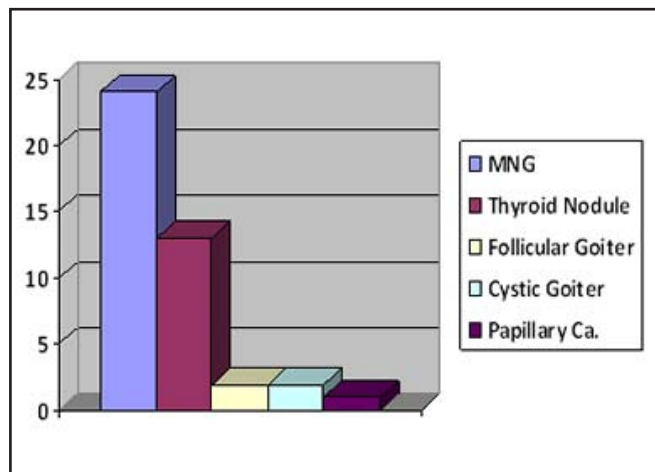


Fig. 2: The frequency and types of thyroidectomies done during our study.

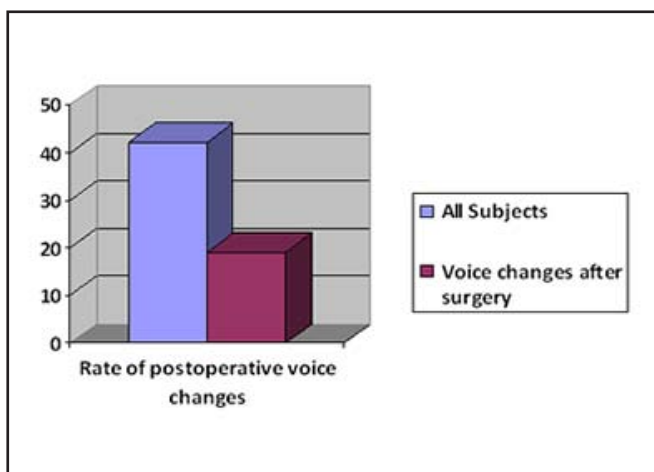


Fig. 3: Rate of external branch of superior laryngeal nerve (EBSLN) injury in the study and control group.

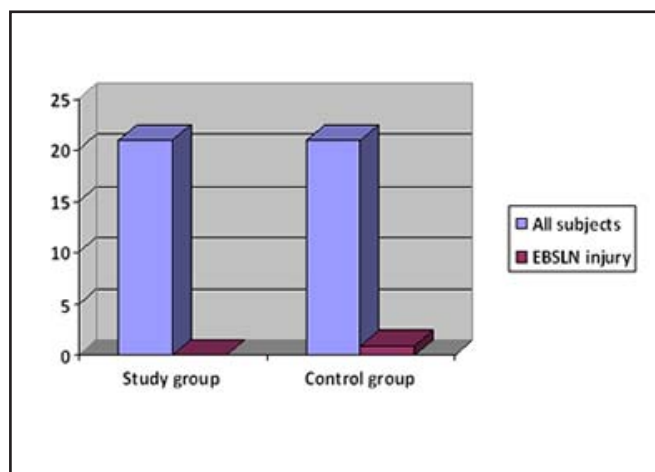


Fig. 4: Rate of external branch of superior laryngeal nerve (EBSLN) injury in the study and control group.

duration of first 3 months after thyroid surgery even patients after EBSLN preservation within study group. Some studies described this temporary result due to relationship of vocal function and extrinsic laryngeal muscles, which shows increased activity at low pitch and decreased activity at high pitch^{9, 10, 11}. Hong *et al* described in a canine laryngeal model that the contraction of sternohyoid and sternothyroid muscles result in lengthening of vocal cords and increased of pitch¹².

The classification of 3 anatomic grades or levels of the lower part of the EBSLN according to its relation to the upper thyroid pole and superior thyroid pedicle enables the surgeons for a safe identification and preservation of this overlooked and neglected laryngeal nerve. Intraoperative identification and neuromonitoring of the EBSLN can help us to prevent its injury during dissection of the upper thyroid pole. Although conventional method of ligating the superior

vessels near the gland can result in the equally low nerve injury outcome, by using the nerve monitor, it can be confirmed that among the structures ligated near the pole, there is no nerve in or near it (Cernea Type 2b).

CONCLUSION

The rate of damage of EBSLN in this study is 2% (which occur in the conventional control group). Even it is low, it still give significant impact to the patient’s quality of voice. The EBSLN should be explored during thyroid surgery and its identification is possible in most cases. Paralysis of the EBSLN can be significant to those whose career depends heavily on full range of voice. Therefore avoiding injury to the EBSLN should not be understated when discussing the complications during thyroid surgery. Using intraoperative neuromonitoring is very helpful in helping to identify and avoiding injury to the EBSLN during thyroid operations.

REFERENCES

1. Cernea CR, Ferraz AR, Fulani J, Monteiro S, Nishio S, Hojaij FC, Dutra JA, Marques LA, Pontes PA, Bevilacqua RG. Identification of the external branch of the superior laryngeal nerve during thyroidectomy. *Am J Surg* 1992; 164: 634-8.
2. Sun SQ, Chang R. The superior laryngeal nerve loop and its surgical implications. *Surg Radiol Anat* 1991;13: 175-80.
3. Cernea CR, Nishio S, Hojaij FC. Identification of the external branch of the superior laryngeal nerve (EBSLN) in large goiters. *Am J Otolaryngol* 1995; 16: 307-11.
4. Dursum G, Sataloff RT, Spiegel JR, Mandel S, Heuer RJ, Risen DC. Superior laryngeal nerve paresis and paralysis. *J Voice* 1996; 10: 206-11.
5. Jansson S, Tisell LE, Hagne I, Sanner E, Stenborg R, Svensson P. Partial superior laryngeal nerve (SLN) lesions before and after thyroid surgery. *World J Surg* 1988; 12: 521-7.
6. Ward PH, Berci G, Calacaterra TC. Superior laryngeal nerve paralysis: an often overlooked entity. *Trans Am Acad Ophthalmol Otolaryngol* 1977; 84: 77-89.
7. McIvor NP, Flint DJ, Gillibrand J, Morton RP. Thyroid surgery and voice-related outcomes. *Aust NZ J Surg* 2000; 79: 179-83.
8. Scott-Brown WJ, Ballantyne JC, Groves J. *Diseases of the ear, nose and throat*. 7th ed. London: Butterworth, 2008.
9. Faaborg-Anderson K, Sonninen A. Function of the extrinsic laryngeal muscles at different pitches. *Acta Otolaryngol* 1960; 51: 89-93.
10. Hirano M, Koike Y, von Leden H. The sternohyoid muscle during phonation. Electromyographic studies. *Acta Otolaryngol* 1967; 64: 500-7.
11. Hong KH, Kim YK. Phonatory characteristics of patients undergoing thyroidectomy without laryngeal nerve injury. *Otolaryngol Head Neck Surg* 1997; 117: 399-404.
12. Hong KH, Ye M, Kim YM, Kevorkian KF, Berke GS. The role of strap muscles in phonation- in vivo canine laryngeal model. *J Voice* 1997; 11: 23-32.