

## CASE REPORT

# Single Stage Minimally Invasive Bilateral Video Assisted Thoracoscopic Surgery for Simultaneous Bilateral Primary Spontaneous Pneumothorax

A Sachithanandan, FRCSI (C-Th) (UK), I Nur Ezrin, MBBS, B Badmanaban, FRCSI(CTh)

Cardiothoracic Surgery Division, Serdang Hospital, Jalan Puchong, Kajang, Selangor 43000, Malaysia

### SUMMARY

Simultaneous bilateral spontaneous pneumothorax (SBSP) is a very rare life-threatening condition that requires rapid diagnosis and treatment. Most cases are secondary to various underlying lung pathology but a primary SBSP may occur due to rupture of subpleural blebs or bullae. Surgery via an open or minimally invasive approach provides definitive treatment and can be undertaken as a staged or simultaneous procedure. We report our experience with two such rare cases utilizing a single stage minimally invasive bilateral video assisted thoracoscopic (VATS) approach. The pathogenesis of this rare condition and intra-operative technical considerations for a successful outcome are discussed.

### KEY WORDS:

*Spontaneous pneumothorax, Video assisted thoracic surgery (VATS)*

### INTRODUCTION

Simultaneous bilateral spontaneous pneumothorax (SBSP) is a very rare life-threatening condition which accounts for 1% of spontaneous pneumothoraces<sup>1</sup>. Most cases are secondary to various underlying lung disease. Rapid diagnosis and treatment is vital as fatal cardiorespiratory embarrassment can quickly ensue. We present two rare cases of primary SBSP with persistent air leaks, treated successfully with a single stage minimally invasive bilateral video assisted thoracoscopic (VATS) approach.

### CASE REPORTS

#### Case 1

A 26-year-old previously healthy male smoker initially presented with a one day history of sudden unexplained dyspnoea. His admission chest radiograph (CXR) demonstrated a large right pneumothorax and an intercostal chest drain (ICD) was promptly inserted. He was transferred to our thoracic service a week later for a persistent air leak. Review of previous imaging identified a concomitant contra lateral left pneumothorax that was missed on the initial admission CXR (Figure 1). A left ICD was subsequently inserted. Computed tomography (CT) scan demonstrated bilateral subpleural apical blebs but otherwise healthy lungs. Findings at surgery were consistent with the CT. A single

stage bilateral VATS apical bullectomy, parietal pleurectomy and pleural abrasion was performed sequentially with alternating single lung ventilation.

First the patient was placed in the right lateral position and the left pleural cavity accessed via a standard 3-port VATS approach. A carefully positioned anterior ICD was inserted at the end of the procedure prior to repositioning the patient in the left lateral position and an identical procedure performed on the right lung.

Post-operatively the patient was transferred to the intensive care unit and extubated several hours later with no air leaks. His subsequent initial recovery was uneventful however a week later prior to discharge the patient developed a sudden and persistent large air leak following a sudden bout of coughing, which failed to resolve with conservative treatment. At redo surgery via a right mini-thoracotomy it was evident the air leak was due to a partial dehiscence of the parenchymal staple line. A further proximal stapled wedge resection reinforced with handsewn buttress felt strips sealed the air leak. Histology revealed mesothelial hyperplasia, subpleural fibrosis and blebs.

#### Case 2

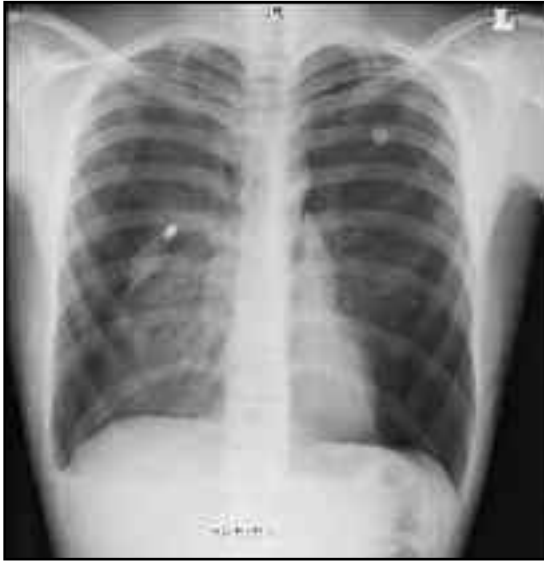A 17-year-old male smoker originally presented to a peripheral hospital with a recurrent left sided pneumothorax treated with an ICD. Following drain removal the patient was discharged home asymptomatic, with complete radiological resolution of the pneumothorax. He re-presented a week later with sudden breathlessness. A CXR (Figure 2) confirmed SBSP. The patient was referred to our thoracic surgical unit with persistent air leaks from bilateral ICDs. CT Thorax confirmed SBSP. The patient proceeded to surgery. A single stage VATS apical bullectomy, parietal pleurectomy and pleural abrasion was performed uneventfully sequentially bilaterally with alternating single lung ventilation as described in Case 1. This patient had an uneventful recovery and was discharged home five days later with no ICD or residual pneumothorax. Histology showed no malignancy or epithelioid granuloma.

### DISCUSSION

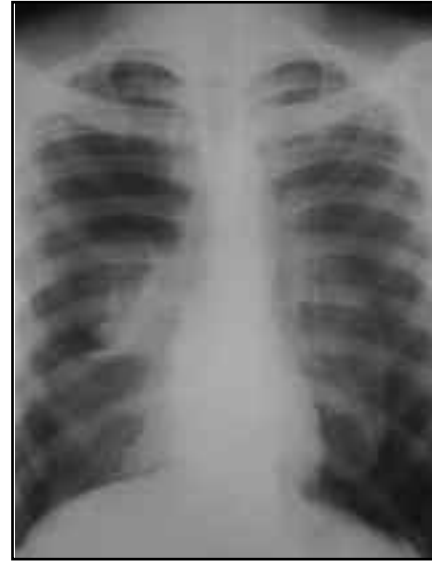
Surgery for SBSP can be technically challenging for obvious reasons. Strategies include an open or minimally invasive VATS approach and can be undertaken simultaneously as a

*This article was accepted: 15 February 2012*

*Corresponding Author: Anand Sachithanandan, Cardiothoracic Surgery Division, Serdang Hospital, Jalan Puchong, Kajang, Selangor 43000, Malaysia  
Email: anandsachithanandan@yahoo.com*



**Fig. 1:** Chest radiograph (CXR) with simultaneous bilateral spontaneous pneumothoraces (SBSP). Note the existing right ICD. The moderate left pneumothorax was 'missed' on initial presentation.



**Fig. 2:** CXR demonstrating SBSP prior to bilateral chest drain insertion.

single stage intervention or as staged procedures. The traditional gold standard thoracotomy provides excellent access to the lung apices where a majority of subpleural blebs or bullae are situated however bilateral thoracotomy incisions can be painful and may impair post-operative respiratory mechanics. Alternatively a median sternotomy is less painful but less cosmetic, affords suboptimal access to the upper lobes and carries a risk of sternal dehiscence. A minimally invasive VATS is routinely performed as a unilateral procedure with a 3-port approach hence staged VATS procedures are easily feasible however this necessitates two separate general anaesthetics. Furthermore positive pressure ventilation with general anaesthesia may exacerbate the contralateral non-operated pneumothorax due to be dealt with at a later time. It is for these reasons that we elected to undertake a simultaneous VATS approach as a single stage procedure.

In both cases, we elected to operate on the left side first due to the ongoing air leak and persistent large pneumothorax. At the end of the procedure we deviated from our usual drain site placement and a more anterior ICD was deliberately inserted to ensure the drain would not kink or obstruct on patient repositioning in the left lateral position to facilitate surgery on the right lung. A standard posterolateral ICD is more likely to kink with potentially catastrophic intra-operative consequences. The identical procedure was repeated on the right side but complicated in Case 1 post surgery by a residual air leak due to the dense adhesions between the lung apex and chest wall. It is possible we missed a residual occult bullae or breached the lung parenchyma with cautery when dividing the adhesions.

A simultaneous VATS approach with the patient in the supine position has been previously reported and avoids the need for patient re-positioning<sup>3,4</sup>. We considered this approach but persisted with a sequential standard lateral VATS approach for familiarity with the intra thoracic anatomical spatial orientation and hence safety reasons. Our patients had two firm indications for surgery namely prolonged air leaks with persistent pneumothoraces, and the rare occurrence of SBSP<sup>5</sup>.

In both cases, histology was consistent with a rare primary SBSP. The mechanisms of bullae formation remain elusive but degradation of pulmonary elastic fibers by smoking –activated neutrophils and macrophages may be partly responsible<sup>6</sup>. Smoking aside, both patients had no relevant past medical or familial history. Secondary SBSP may occur due to various underlying lung diseases including pulmonary metastases, interstitial lung disease, histiocytosis X, asthma, cystic fibrosis, lymphangioleiomyomatosis, granulomatous diseases, chronic obstructive airways disease, rheumatoid disease and lung cysts, all of which should be considered and systematically excluded<sup>1,2</sup>. A CT scan is a useful pre-operative investigation in such cases.

Our experience suggests a bilateral single stage VATS utilising a conventional lateral approach with intra-operative patient repositioning is a safe, feasible and familiar technique for treatment of SBSP. Careful consideration regarding which side to operate on first and thoughtful anterior ICD placement is important.

## REFERENCES

1. Graf-Deuel E, Knoblauch A. Simultaneous bilateral spontaneous pneumothorax. *Chest* 1994; 105: 1142-1146.
2. Sayar A, Turna A, Metin M, Kucukyagci N, Solak O, Gurses A. Simultaneous bilateral spontaneous pneumothorax - report of 12 cases and review of the literature. *Acta Chir Belg.* 2004; 104: 572-576.
3. Maruyama R, Anai H. Video-assisted thoracoscopic surgery for bilateral spontaneous pneumothorax in supine position: the use of a pillow beneath the back for intercostal space widening. *Thorac Cardiovasc Surg.* 2000; 48: 370-371.
4. Junior GRN, Rodrigues ALS, Meguins LC. Thoracoscopic surgery for simultaneous bilateral spontaneous pneumothorax. *Internet J Thorac Cardiovasc Surg* 2008;12:1.
5. MacDuff A, Arnold A, Harvey J. Management of spontaneous pneumothorax: British Thoracic Society pleural disease guideline 2010. *Thorax* 2010; 65 (suppl): ii18-iii31. Doi: 10.1136/thx.2010.136986.
6. Sahn SA, Hefner JE. Spontaneous pneumothorax – review article. *N Engl J Med* 2000; 342: 868-874.